A 25-year-old woman comes to the office due to arthralgias in her hands for the last several months. The pain frequently involves her wrists and proximal finger joints bilaterally, and alternates between being worse in the wrists versus in the hands. The patient has no other medical problems and takes no medications. Complete blood count results are as follows:

Erythrocytes	3.2 million/mm^3
Platelets	90,000/mm^3
Leukocytes	3,200/mm^3

Further evaluation reveals proteinuria and red blood cell casts. Which of the following is the most likely diagnosis?

A. Ankylosing spondylitis

B. Myelodysplastic syndrome

C. Primary myelofibrosis

D. Systemic lupus erythematosus

E. Vitamin B_{12} deficiency

Submit

A 25-year-old woman comes to the office due to arthralgias in her hands for the last several months. The pain frequently involves her wrists and proximal finger joints bilaterally, and alternates between being worse in the wrists versus in the hands. The patient has no other medical problems and takes no medications. Complete blood count results are as follows:

Erythrocytes	3.2 million/mm^3
Platelets	90,000/mm^3
Leukocytes	3,200/mm^3

Further evaluation reveals proteinuria and red blood cell casts. Which of the following is the most likely diagnosis?

- A. Ankylosing spondylitis (1%)
- B. Myelodysplastic syndrome (11%)
- C. Primary myelofibrosis (10%)
- ✓ D. Systemic lupus erythematosus (75%)
- E. Vitamin B_{12} deficiency (0%)

Omitted
Correct answer
D

75%
Answered correctly

03 secs
Time Spent

03/03/2020
Last Updated

Explanation

Manifestations of systemic lupus erythematosus	
Clinical symptoms	• Constitutional: fever, fatigue & weight loss • Symmetric, migratory arthritis • Skin: butterfly rash & photosensitivity • Serositis: pleurisy, pericarditis & peritonitis • Thromboembolic events (due to vasculitis & antiphospholipid antibodies) • Neurologic: cognitive dysfunction & seizures

Laboratory findings	• Hemolytic anemia, thrombocytopenia & leukopenia
	• Hypocomplementemia (C3 & C4)
	• Antibodies:
	  ◦ ANA (sensitive)
	  ◦ Anti-dsDNA & anti-Sm (specific)
	• Renal involvement: proteinuria & elevated creatinine

ANA = antinuclear antibodies; **dsDNA** = double-stranded DNA.

This patient has chronic **migratory arthralgias**, pancytopenia, and evidence of glomerulonephritis (ie, proteinuria, red cell casts). These findings are suspicious for **systemic lupus erythematosus** (SLE), an idiopathic autoimmune disorder that is most common in women.

Hematologic abnormalities are common in SLE. The most common cause of anemia is chronic inflammation (anemia of chronic disease); however, **pancytopenia** (as seen in this patient) can also occur due to autoantibodies against blood cell antigens (ie, **type II hypersensitivity**). Autoimmune hemolytic anemia in SLE is caused by IgG antibodies against erythrocytes; manifestations include spherocytosis, a positive direct Coombs test, and extravascular hemolysis. Antiplatelet antibodies in SLE can cause thrombocytopenia resembling immune thrombocytopenic purpura. Leukopenia can also occur, primarily due to antibody-mediated destruction of neutrophils.

Lupus nephritis is caused by immune complex deposition (ie, **type III hypersensitivity**) in the mesangium, subendothelial, and/or subepithelial spaces. Histopathology is variable but diffuse proliferative glomerulonephritis (class IV) is the most common pattern.

This patient has chronic **migratory arthralgias**, pancytopenia, and evidence of glomerulonephritis (ie, proteinuria, red cell casts). These findings are suspicious for **systemic lupus erythematosus** (SLE), an idiopathic autoimmune disorder that is most common in women.

Hematologic abnormalities are common in SLE. The most common cause of anemia is chronic inflammation (anemia of chronic disease); however, **pancytopenia** (as seen in this patient) can also occur due to autoantibodies against blood cell antigens (ie, **type II hypersensitivity**). Autoimmune hemolytic anemia in SLE is caused by IgG antibodies against erythrocytes; manifestations include spherocytosis, a positive direct Coombs test, and extravascular hemolysis. Antiplatelet antibodies in SLE can cause thrombocytopenia resembling immune thrombocytopenic purpura. Leukopenia can also occur, primarily due to antibody-mediated destruction of neutrophils.

Lupus nephritis is caused by immune complex deposition (ie, **type III hypersensitivity**) in the mesangium, subendothelial, and/or subepithelial spaces. Histopathology is variable but diffuse proliferative glomerulonephritis (class IV) is the most common pattern.

(Choice A) Ankylosing spondylitis is a chronic inflammatory arthritis involving the spine and sacroiliac joints. It presents with low back pain and stiffness. Common associated features include enthesitis, dactylitis, and uveitis, but renal and hematologic manifestations (other than anemia of chronic disease) are not common.

(Choices B, C, and E) Myelodysplastic syndromes and primary myelofibrosis are bone marrow disorders that occur most commonly in patients over age 50. Vitamin B_{12} deficiency can also cause impaired hematopoiesis. Although these disorders can cause pancytopenia, this patient's arthritis and nephritis are much more consistent with SLE.

Educational objective:
Systemic lupus erythematosus is an autoimmune disorder that occurs most commonly in women. Hematologic abnormalities are common; autoantibodies against blood cell antigens (ie, type II hypersensitivity) can cause pancytopenia (ie, anemia, thrombocytopenia, leukopenia). In contrast, lupus nephritis is caused by immune complex deposition (ie, type III hypersensitivity) in the glomeruli.

References

- Management of immune cytopenias in patients with systemic lupus erythematosus - old and new.
- Redefining lupus nephritis: clinical implications of pathophysiologic subtypes.

Pathology Hematology & Oncology SLE

A 42-year-old previously healthy woman comes to the office due to fever and sore throat. She has no cough. Physical examination shows tonsillar exudate and a nontender cervical lymph node that measures 3.5 cm in diameter. Oral antibiotic therapy is started and on a follow-up visit a week later, the patient reports that her symptoms have resolved. The previously enlarged cervical lymph node has decreased slightly in size. On several follow-up visits over the following year, the patient remains asymptomatic and the size of the lymph node fluctuates but does not disappear completely. Referral to a surgeon is made and excisional biopsy of the lymph node is performed. Which of the following most likely will be seen on biopsy?

- A. Acute lymphoid leukemia
- B. Burkitt lymphoma
- C. Diffuse large B-cell lymphoma
- D. Follicular lymphoma
- E. Hairy cell leukemia
- F. Mycosis fungoides

Submit

A 42-year-old previously healthy woman comes to the office due to fever and sore throat. She has no cough. Physical examination shows tonsillar exudate and a nontender cervical lymph node that measures 3.5 cm in diameter. Oral antibiotic therapy is started and on a follow-up visit a week later, the patient reports that her symptoms have resolved. The previously enlarged cervical lymph node has decreased slightly in size. On several follow-up visits over the following year, the patient remains asymptomatic and the size of the lymph node fluctuates but does not disappear completely. Referral to a surgeon is made and excisional biopsy of the lymph node is performed. Which of the following most likely will be seen on biopsy?

- A. Acute lymphoid leukemia (1%)
- B. Burkitt lymphoma (17%)
- C. Diffuse large B-cell lymphoma (17%)
- ✓ D. Follicular lymphoma (52%)
- E. Hairy cell leukemia (2%)
- F. Mycosis fungoides (8%)

Omitted
Correct answer
D

52%
Answered correctly

01 sec
Time Spent

01/29/2020
Last Updated

Explanation

This patient with persistent fluctuating lymphadenopathy, who may have had an unrelated pharyngitis (treated with antibiotics) on initial presentation, most likely has **follicular lymphoma**. Follicular lymphoma is the most common **indolent** non-Hodgkin lymphoma (NHL) in adults

This patient with persistent fluctuating lymphadenopathy, who may have had an unrelated pharyngitis (treated with antibiotics) on initial presentation, most likely has **follicular lymphoma**. Follicular lymphoma is the most common **indolent** non-Hodgkin lymphoma (NHL) in adults and the second most common NHL overall. It derives from follicular B cells and typically has a long, **waxing and waning** clinical course. This condition most often presents in middle-aged patients with **painless lymph node enlargement** or abdominal discomfort from an abdominal mass. Histology is notable for a mixture of **cleaved and noncleaved** follicle center cells in a nodular pattern. The majority of tumors exhibit a **t(14;18) translocation**, resulting in overexpression of the *bcl-2* oncogene that blocks programmed cell death.

(Choice A) Acute lymphoblastic leukemia is the most common leukemia in children. It presents with lymphadenopathy, hepatosplenomegaly, fever, bleeding, and bone pain. Neoplastic cells are pre-B or pre-T lymphoblasts.

(Choice B) Burkitt lymphoma is a highly aggressive (but generally chemotherapy-responsive) B-cell NHL associated with chronic Epstein-Barr virus infection and/or deregulation of the c-*myc* proto-oncogene. Patients typically develop rapidly growing tumor masses in the facial bone, jaw, or abdomen. Tumor doubling time is very rapid and spontaneous tumor lysis can occur.

(Choice C) Diffuse large B-cell lymphoma (most common NHL) typically presents with a rapidly enlarging nodal (neck, abdomen, mediastinum) or extranodal symptomatic mass. The Waldeyer's ring (oropharyngeal lymphoid tissue) and gastrointestinal tract are commonly involved, and systemic "B" symptoms (fever, weight loss, drenching night sweats) can also be seen.

(Choice E) Hairy cell leukemia presents with splenomegaly and pancytopenia in older men. Lymph node enlargement is not characteristic. Leukemic cells have hairlike cytoplasmic projections and are positive for tartrate-resistant acid phosphatase (TRAP).

(Choice F) Mycosis fungoides is a cutaneous T-cell lymphoma. Proliferating $CD4^+$ lymphocytes infiltrate the dermis and epidermis, where they form Pautrier microabscesses. This condition manifests with plaques (often on trunk or buttocks) that may be confused with eczema or psoriasis. Generalized erythema and scaling and thickening of the skin (erythroderma) may result.

Educational objective:
Follicular lymphoma is the most common indolent non-Hodgkin lymphoma in adults. It is of B-cell origin and presents with painless waxing and waning lymphadenopathy. The cytogenetic change t(14;18) is characteristic and results in overexpression of the *bcl-2* oncogene.

References

- Follicular lymphoma: 2014 update on diagnosis and management

condition most often presents in middle-aged patients with painless lymph node enlargement or abdominal discomfort from an abdominal mass. Histology is notable for a mixture of **cleaved and noncleaved** follicle center cells in a nodular pattern. The majority of tumors exhibit a **t(14;18) translocation**, resulting in overexpression of the *bcl-2* oncogene that blocks programmed cell death.

(Choice A) Acute lymphoblastic leukemia is the most common leukemia in children. It presents with lymphadenopathy, hepatosplenomegaly, fever, bleeding, and bone pain. Neoplastic cells are pre-B or pre-T lymphoblasts.

(Choice B) Burkitt lymphoma is a highly aggressive (but generally chemotherapy-responsive) B-cell NHL associated with chronic Epstein-Barr virus infection and/or deregulation of the c-*myc* proto-oncogene. Patients typically develop rapidly growing tumor masses in the facial bone, jaw, or abdomen. Tumor doubling time is very rapid and spontaneous tumor lysis can occur.

(Choice C) Diffuse large B-cell lymphoma (most common NHL) typically presents with a rapidly enlarging nodal (neck, abdomen, mediastinum) or extranodal symptomatic mass. The Waldeyer's ring (oropharyngeal lymphoid tissue) and gastrointestinal tract are commonly involved, and systemic "B" symptoms (fever, weight loss, drenching night sweats) can also be seen.

(Choice E) Hairy cell leukemia presents with splenomegaly and pancytopenia in older men. Lymph node enlargement is not characteristic. Leukemic cells have hairlike cytoplasmic projections and are positive for tartrate-resistant acid phosphatase (TRAP).

(Choice F) Mycosis fungoides is a cutaneous T-cell lymphoma. Proliferating $CD4^+$ lymphocytes infiltrate the dermis and epidermis, where they form Pautrier microabscesses. This condition manifests with plaques (often on trunk or buttocks) that may be confused with eczema or psoriasis. Generalized erythema and scaling and thickening of the skin (erythroderma) may result.

Educational objective:
Follicular lymphoma is the most common indolent non-Hodgkin lymphoma in adults. It is of B-cell origin and presents with painless waxing and waning lymphadenopathy. The cytogenetic change t(14;18) is characteristic and results in overexpression of the *bcl-2* oncogene.

References

- Follicular lymphoma: 2014 update on diagnosis and management.

Pathology	Hematology & Oncology	Nonhodgkin lymphoma
Subject	System	Topic

and the second most common NHL overall. It derives from follicular B cells and typically has a long, **waxing and waning** clinical course. This

Exhibit Display

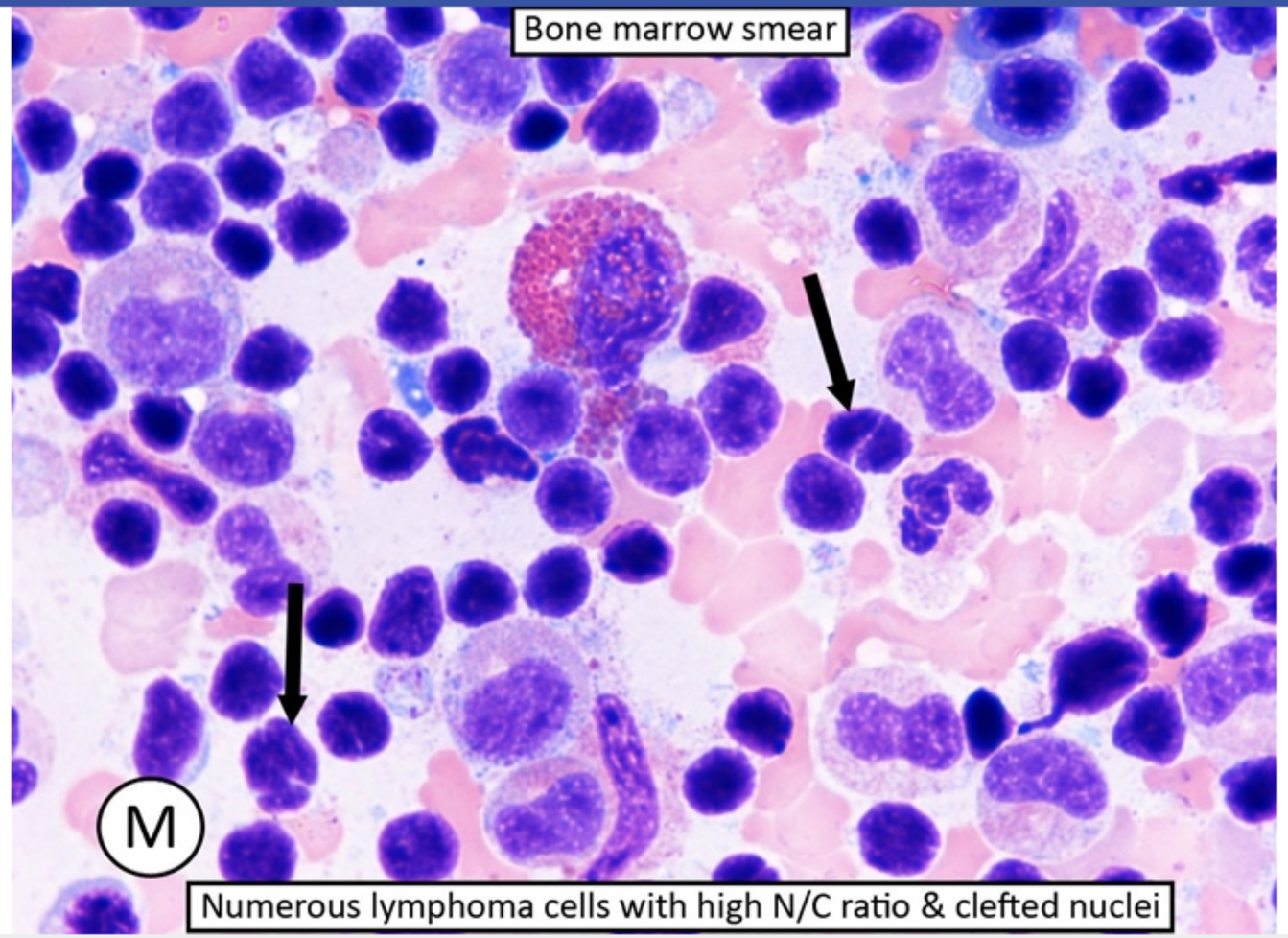

Zoom In | Zoom Out | Reset | Add To New Card | Existing Card

Pathology Hematology & Oncology Nonhodgkin lymphoma

and the second most common NHL overall. It derives from follicular B cells and typically has a long, **waxing and waning** clinical course. This

Exhibit Display

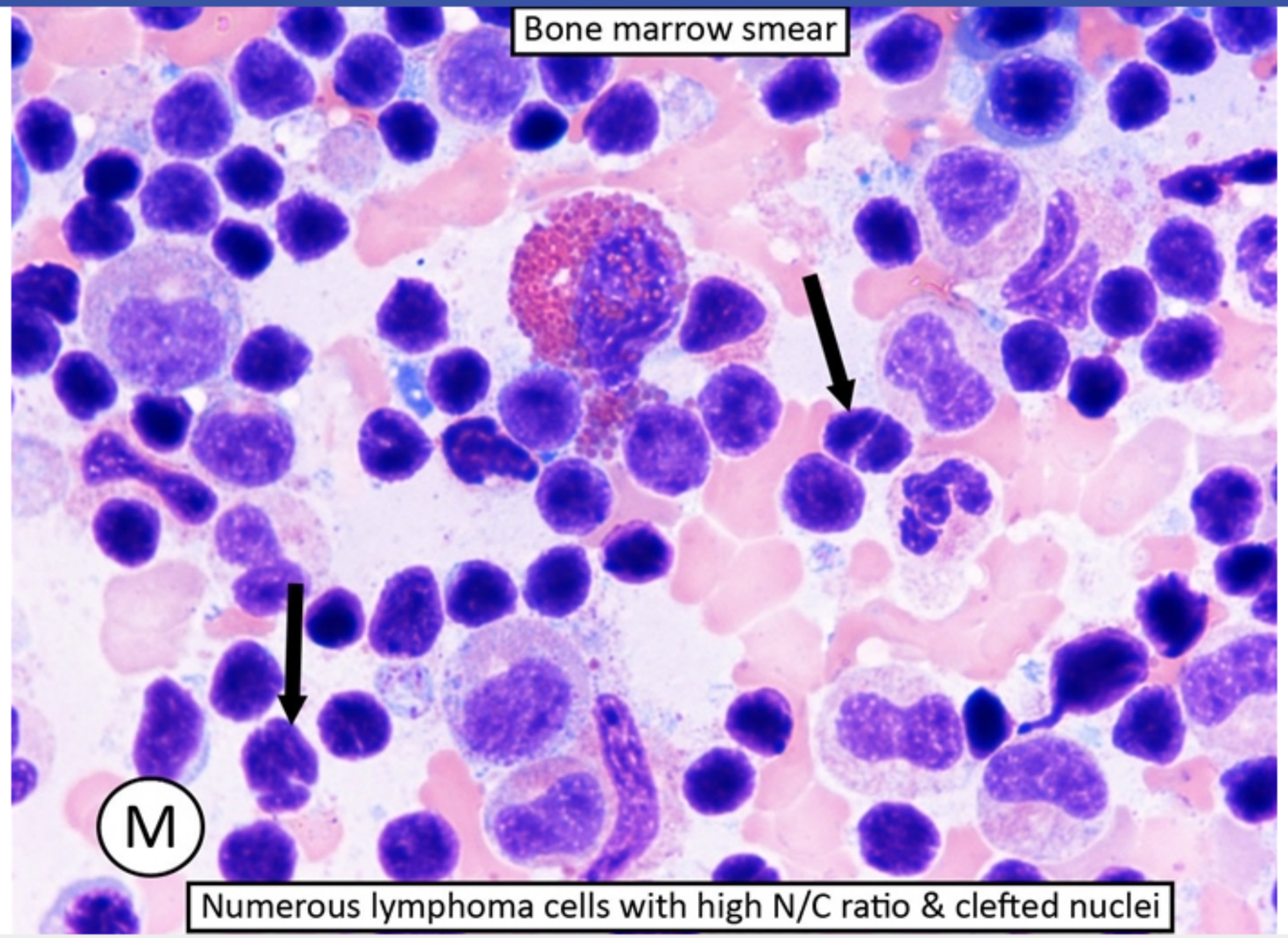

Zoom In | Zoom Out | Reset | Add To New Card | Existing Card

Pathology Hematology & Oncology Nonhodgkin lymphoma

t(14;18) translocation, resulting in overexpression of the *bcl-2* oncogene that blocks programmed cell death.

(Choice A) Acute lymphoblastic leukemia is the most common leukemia in children. It presents with lymphadenopathy, hepatosplenomegaly, fever, bleeding, and bone pain. Neoplastic cells are pre-B or pre-T lymphoblasts.

(Choice B) Burkitt lymphoma is a highly aggressive (but generally chemotherapy-responsive) B-cell NHL associated with chronic Epstein-Barr virus infection and/or deregulation of the c-*myc* proto-oncogene. Patients typically develop rapidly growing tumor masses in the facial bone, jaw, or abdomen. Tumor doubling time is very rapid and spontaneous tumor lysis can occur.

(Choice C) Diffuse large B-cell lymphoma (most common NHL) typically presents with a rapidly enlarging nodal (neck, abdomen, mediastinum) or extranodal symptomatic mass. The Waldeyer's ring (oropharyngeal lymphoid tissue) and gastrointestinal tract are commonly involved, and systemic "B" symptoms (fever, weight loss, drenching night sweats) can also be seen.

(Choice E) Hairy cell leukemia presents with splenomegaly and pancytopenia in older men. Lymph node enlargement is not characteristic. Leukemic cells have hairlike cytoplasmic projections and are positive for tartrate-resistant acid phosphatase (TRAP).

(Choice F) Mycosis fungoides is a cutaneous T-cell lymphoma. Proliferating $CD4^+$ lymphocytes infiltrate the dermis and epidermis, where they form Pautrier microabscesses. This condition manifests with plaques (often on trunk or buttocks) that may be confused with eczema or psoriasis. Generalized erythema and scaling and thickening of the skin (erythroderma) may result.

Educational objective:
Follicular lymphoma is the most common indolent non-Hodgkin lymphoma in adults. It is of B-cell origin and presents with painless waxing and waning lymphadenopathy. The cytogenetic change t(14;18) is characteristic and results in overexpression of the *bcl-2* oncogene.

References

- Follicular lymphoma: 2014 update on diagnosis and management.

Pathology	Hematology & Oncology	Nonhodgkin lymphoma
Subject	System	Topic

Copyright © UWorld. All rights reserved.

t(14;18) translocation, resulting in overexpression of the *bcl-2* oncogene that blocks programmed cell death.

Exhibit Display

Zoom In | Zoom Out | Reset | Add To New Card | Existing Card

1
2
3
4
5
6
7
8
9
10
11
12
13
14
15
16
17
18
19
20
21
22
23
24
25
26
27
28
29
30

t(14;18) translocation, resulting in overexpression of the *bcl-2* oncogene that blocks programmed cell death.

(Choice A) Acute lymphoblastic leukemia is the most common leukemia in children. It presents with lymphadenopathy, hepatosplenomegaly, fever, bleeding, and bone pain. Neoplastic cells are pre-B or pre-T lymphoblasts.

(Choice B) Burkitt lymphoma is a highly aggressive (but generally chemotherapy-responsive) B-cell NHL associated with chronic Epstein-Barr virus infection and/or deregulation of the c-*myc* proto-oncogene. Patients typically develop rapidly growing tumor masses in the facial bone, jaw, or abdomen. Tumor doubling time is very rapid and spontaneous tumor lysis can occur.

(Choice C) Diffuse large B-cell lymphoma (most common NHL) typically presents with a rapidly enlarging nodal (neck, abdomen, mediastinum) or extranodal symptomatic mass. The Waldeyer's ring (oropharyngeal lymphoid tissue) and gastrointestinal tract are commonly involved, and systemic "B" symptoms (fever, weight loss, drenching night sweats) can also be seen.

(Choice E) Hairy cell leukemia presents with splenomegaly and pancytopenia in older men. Lymph node enlargement is not characteristic. Leukemic cells have hairlike cytoplasmic projections and are positive for tartrate-resistant acid phosphatase (TRAP).

(Choice F) Mycosis fungoides is a cutaneous T-cell lymphoma. Proliferating $CD4^+$ lymphocytes infiltrate the dermis and epidermis, where they form Pautrier microabscesses. This condition manifests with plaques (often on trunk or buttocks) that may be confused with eczema or psoriasis. Generalized erythema and scaling and thickening of the skin (erythroderma) may result.

Educational objective:
Follicular lymphoma is the most common indolent non-Hodgkin lymphoma in adults. It is of B-cell origin and presents with painless waxing and waning lymphadenopathy. The cytogenetic change t(14;18) is characteristic and results in overexpression of the *bcl-2* oncogene.

References

- Follicular lymphoma: 2014 update on diagnosis and management.

Pathology	Hematology & Oncology	Nonhodgkin lymphoma
Subject	System	Topic

Copyright © UWorld. All rights reserved.

An 8-year-old boy comes to the office due to a mass in the right mandible. His family first noticed it a few months ago, and it has grown rapidly. He has had no fevers, chills, cough, or weight loss. The patient and his family recently immigrated to the United States from East Africa. He has no known medical problems. Temperature is 37 C (98.6 F). Physical examination shows a large tumor on the right mandible with palpable regional lymphadenopathy. A biopsy of the lesion is performed. Histopathologic examination shows a diffuse infiltrate of lymphoid cells with numerous mitotic figures. Interspersed macrophages surrounded by clear spaces are also seen. The gene translocated in these lymphoid cells produces a protein that is most directly responsible for which of the following functions?

- A. Apoptosis inhibition
- B. DNA repair
- C. Regulation of G1 to S-phase transition
- D. Transcription activation
- E. Tyrosine kinase upregulation

Submit

An 8-year-old boy comes to the office due to a mass in the right mandible. His family first noticed it a few months ago, and it has grown rapidly. He has had no fevers, chills, cough, or weight loss. The patient and his family recently immigrated to the United States from East Africa. He has no known medical problems. Temperature is 37 C (98.6 F). Physical examination shows a large tumor on the right mandible with palpable regional lymphadenopathy. A biopsy of the lesion is performed. Histopathologic examination shows a diffuse infiltrate of lymphoid cells with numerous mitotic figures. Interspersed macrophages surrounded by clear spaces are also seen. The gene translocated in these lymphoid cells produces a protein that is most directly responsible for which of the following functions?

- A. Apoptosis inhibition (16%)
- B. DNA repair (2%)
- C. Regulation of G1 to S-phase transition (13%)
- ✓ D. Transcription activation (53%)
- E. Tyrosine kinase upregulation (14%)

Omitted
Correct answer
D

53%
Answered correctly

02 secs
Time Spent

05/18/2020
Last Updated

Explanation

This patient likely has the endemic African form of **Burkitt lymphoma**, which primarily affects children and typically presents as a maxillary or mandibular mass. This type of lymphoma is strongly associated with **Epstein-Barr virus** (EBV) infection.

On light microscopy, Burkitt lymphoma consists of monomorphic, intermediate-sized lymphocytes with round nuclei, multiple prominent nucleoli,

1 2 3 4 5 6 7 8 9 10 11 12 13 14 15 16 17 18 19 20 21 22 23 24 25 26 27 28 29 30

This patient likely has the endemic African form of **Burkitt lymphoma**, which primarily affects children and typically presents as a maxillary or mandibular mass. This type of lymphoma is strongly associated with **Epstein-Barr virus** (EBV) infection.

On light microscopy, Burkitt lymphoma consists of monomorphic, intermediate-sized lymphocytes with round nuclei, multiple prominent nucleoli, and vacuolated basophilic cytoplasm. A high mitotic index and high cell death rate are typically seen. Benign macrophages that phagocytize the resulting cellular debris ("**tingible body macrophages**") are diffusely distributed throughout the malignant tissue. The clear spaces that surround these macrophages contribute to the characteristic "starry sky" appearance of Burkitt lymphoma.

Most Burkitt lymphomas demonstrate a translocation between the c-*Myc* oncogene on the long arm of chromosome 8 and the Ig heavy chain region on chromosome 14 [**t(8;14)**]. The product of c-*Myc* is a nuclear phosphoprotein that functions as a **transcription activator** controlling cell proliferation, differentiation, and apoptosis.

(Choice A) Follicular lymphoma is often characterized by a translocation between the long arm of chromosome 18 near the *BCL2* gene and the Ig heavy chain gene on chromosome 14 [t(14;18)]. This translocation leads to overexpression of the apoptosis inhibitor protein Bcl-2.

(Choice B) Mutations of DNA repair enzymes (eg, BRCA1, BRCA2) are associated with breast cancer, ovarian cancer, Lynch syndrome, xeroderma pigmentosum, Fanconi anemia, and many other diseases.

(Choice C) Translocation between the cyclin D1 locus on chromosome 11 and the Ig heavy chain locus on chromosome 14 [t(11;14)] is characteristic of mantle cell lymphoma. This abnormality results in increased production of cyclin D1, a promoter of G1 to S-phase transition during the cell cycle.

(Choice E) Translocation of the *ABL* gene from chromosome 9 to 22 [t(9;22)] results in the Philadelphia chromosome, a typical finding in chronic myelogenous leukemia. *BCR-ABL*, the resulting fusion gene, encodes a protein that inhibits apoptosis while promoting mitogenesis and increased tyrosine kinase activity.

Educational objective:
Burkitt lymphoma is characterized by aggressive rapid growth and a "starry sky" microscopic appearance. Translocation of the c-*Myc* oncogene on the long arm of chromosome 8 with the Ig heavy chain region on chromosome 14 produces a nuclear phosphoprotein (c-Myc) that functions as a transcription activator.

On light microscopy, Burkitt lymphoma consists of monomorphic, intermediate-sized lymphocytes with round nuclei, multiple prominent nucleoli, and vacuolated basophilic cytoplasm. A high mitotic index and high cell death rate are typically seen. Benign macrophages that phagocytize the resulting cellular debris ("**tingible body macrophages**") are diffusely distributed throughout the malignant tissue. The clear spaces that surround these macrophages contribute to the characteristic "starry sky" appearance of Burkitt lymphoma.

Most Burkitt lymphomas demonstrate a translocation between the c-*Myc* oncogene on the long arm of chromosome 8 and the Ig heavy chain region on chromosome 14 [**t(8;14)**]. The product of c-*Myc* is a nuclear phosphoprotein that functions as a **transcription activator** controlling cell proliferation, differentiation, and apoptosis.

(Choice A) Follicular lymphoma is often characterized by a translocation between the long arm of chromosome 18 near the *BCL2* gene and the Ig heavy chain gene on chromosome 14 [t(14;18)]. This translocation leads to overexpression of the apoptosis inhibitor protein Bcl-2.

(Choice B) Mutations of DNA repair enzymes (eg, BRCA1, BRCA2) are associated with breast cancer, ovarian cancer, Lynch syndrome, xeroderma pigmentosum, Fanconi anemia, and many other diseases.

(Choice C) Translocation between the cyclin D1 locus on chromosome 11 and the Ig heavy chain locus on chromosome 14 [t(11;14)] is characteristic of mantle cell lymphoma. This abnormality results in increased production of cyclin D1, a promoter of G1 to S-phase transition during the cell cycle.

(Choice E) Translocation of the *ABL* gene from chromosome 9 to 22 [t(9;22)] results in the Philadelphia chromosome, a typical finding in chronic myelogenous leukemia. *BCR-ABL*, the resulting fusion gene, encodes a protein that inhibits apoptosis while promoting mitogenesis and increased tyrosine kinase activity.

Educational objective:
Burkitt lymphoma is characterized by aggressive rapid growth and a "starry sky" microscopic appearance. Translocation of the c-*Myc* oncogene on the long arm of chromosome 8 with the Ig heavy chain region on chromosome 14 produces a nuclear phosphoprotein (c-Myc) that functions as a transcription activator.

Pathology	Hematology & Oncology	Burkitt lymphoma
Subject	System	Topic

1
2
3
4
5
6
7
8
9
10
11
12
13
14
15
16
17
18
19
20
21
22
23
24
25
26
27
28
29
30

Exhibit Display

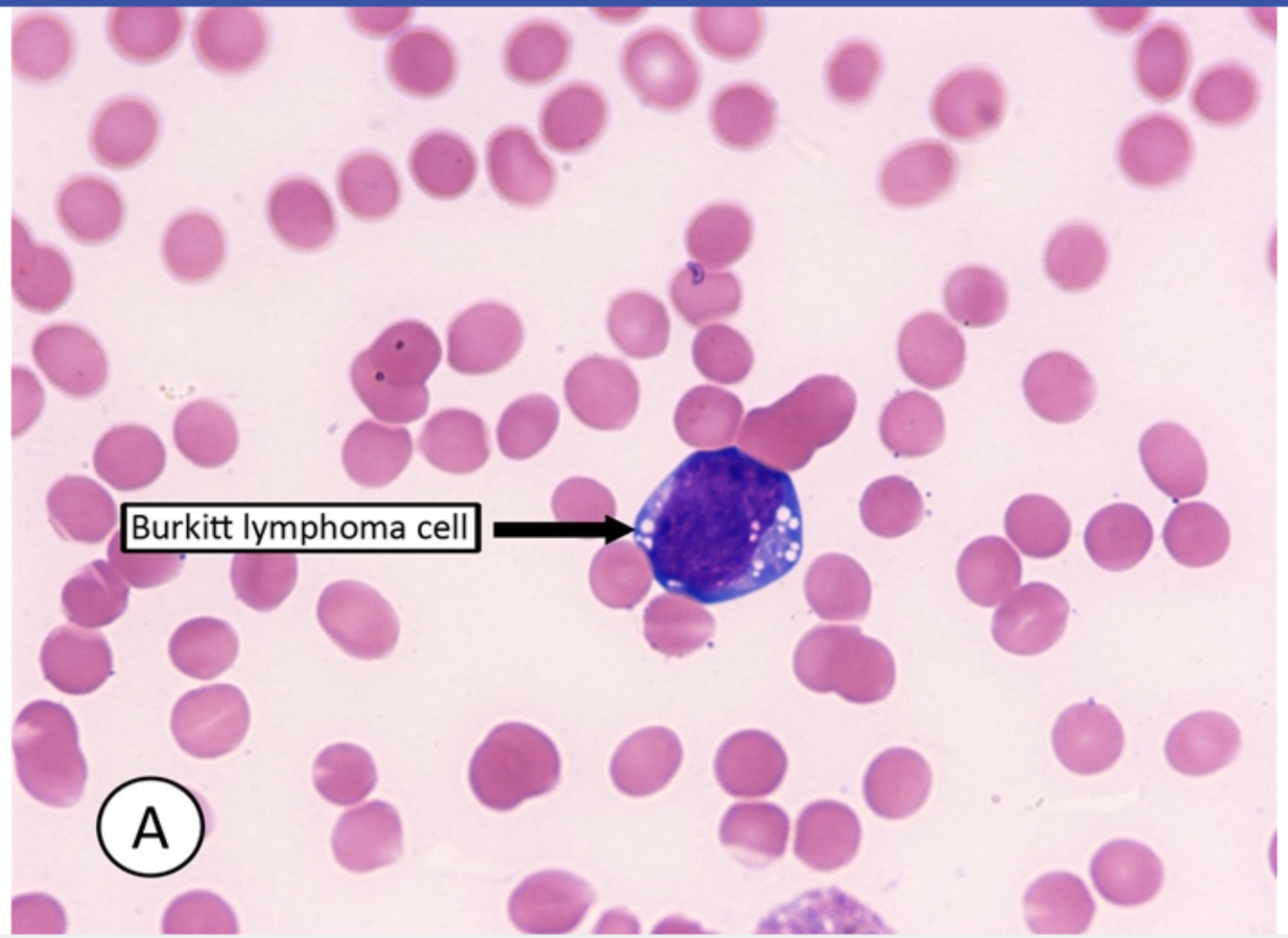

Zoom In | Zoom Out | Reset | Add To New Card | Existing Card

a transcription activator.

1
2
3
4
5
6
7
8
9
10
11
12
13
14
15
16
17
18
19
20
21
22
23
24
25
26
27
28
29
30

Exhibit Display

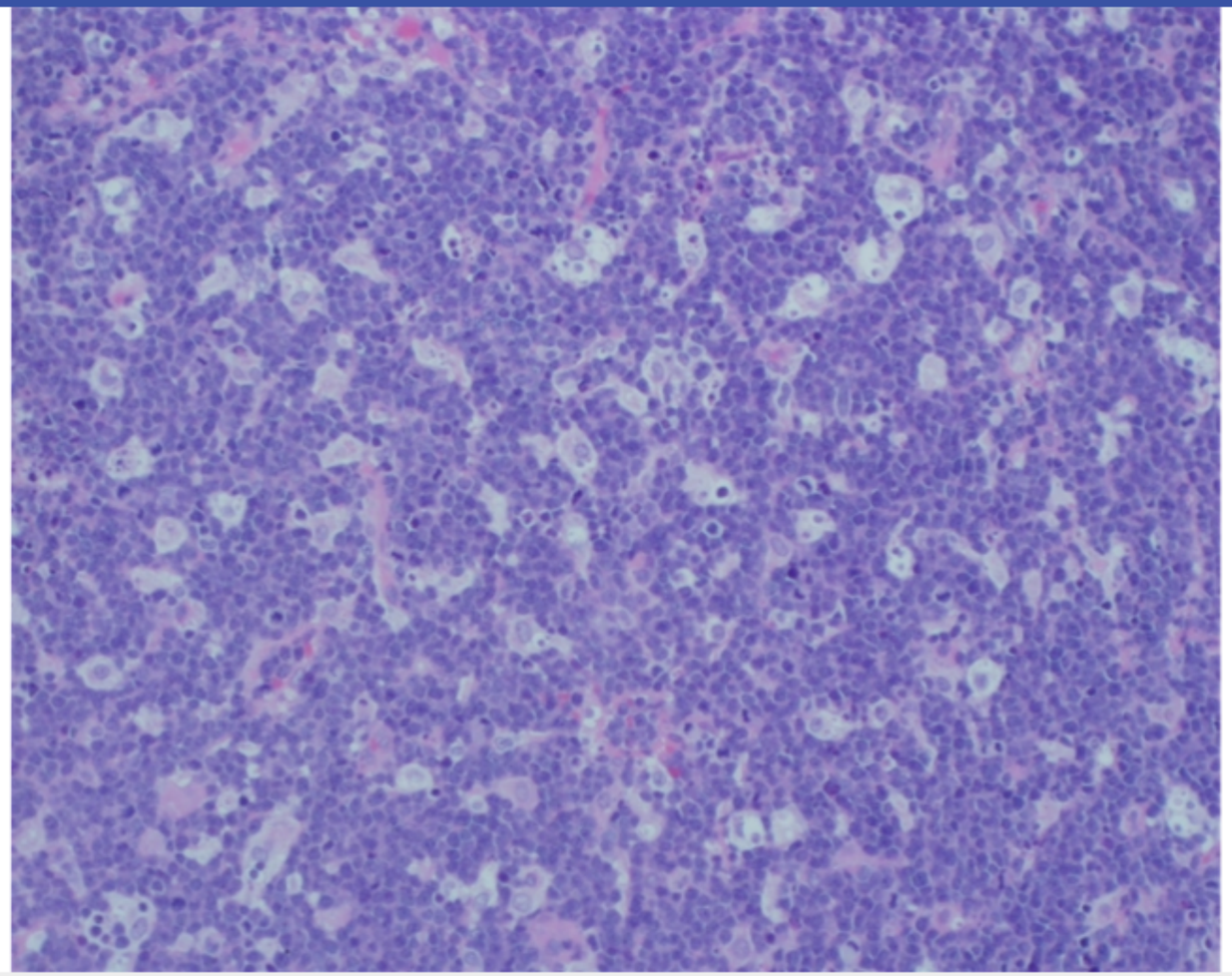

Zoom In | Zoom Out | Reset | Add To New Card | Existing Card

a transcription activator.

1
2
3
4
5
6
7
8
9
10
11
12
13
14
15
16
17
18
19
20
21
22
23
24
25
26
27
28
29
30

A 62-year-old man comes to the office due to worsening difficulty with swallowing food over the last 3 months. He has smoked a pack of cigarettes daily for the past 45 years. On examination, there is a firm, palpable mass at the base of tongue. Cervical lymph nodes are also palpable. Which of the following histologic features is most likely to be seen on biopsy of the tongue lesion?

A. Fibrovascular cores surrounded by squamous epithelium

B. Glandular structures with droplets of mucin

C. Inflammatory infiltrate with pseudohyphae

D. Irregular foci of keratinization

E. Nodular proliferation of lymphocytic follicles

Submit

A 62-year-old man comes to the office due to worsening difficulty with swallowing food over the last 3 months. He has smoked a pack of cigarettes daily for the past 45 years. On examination, there is a firm, palpable mass at the base of tongue. Cervical lymph nodes are also palpable. Which of the following histologic features is most likely to be seen on biopsy of the tongue lesion?

- A. Fibrovascular cores surrounded by squamous epithelium (27%)
- B. Glandular structures with droplets of mucin (5%)
- C. Inflammatory infiltrate with pseudohyphae (0%)
- ✓ D. Irregular foci of keratinization (57%)
- E. Nodular proliferation of lymphocytic follicles (8%)

Omitted
Correct answer
D

57%
Answered correctly

01 sec
Time Spent

03/11/2020
Last Updated

Explanation

Keratinizing invasive squamous cell carcinoma

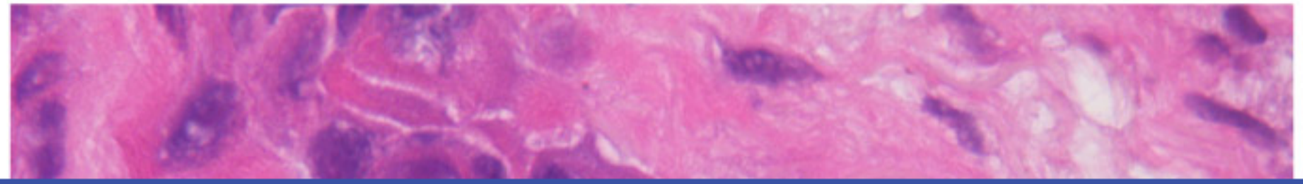

1
2
3
4
5
6
7
8
9
10
11
12
13
14
15
16
17
18
19
20
21
22
23
24
25
26
27
28
29
30

Keratinizing invasive squamous cell carcinoma

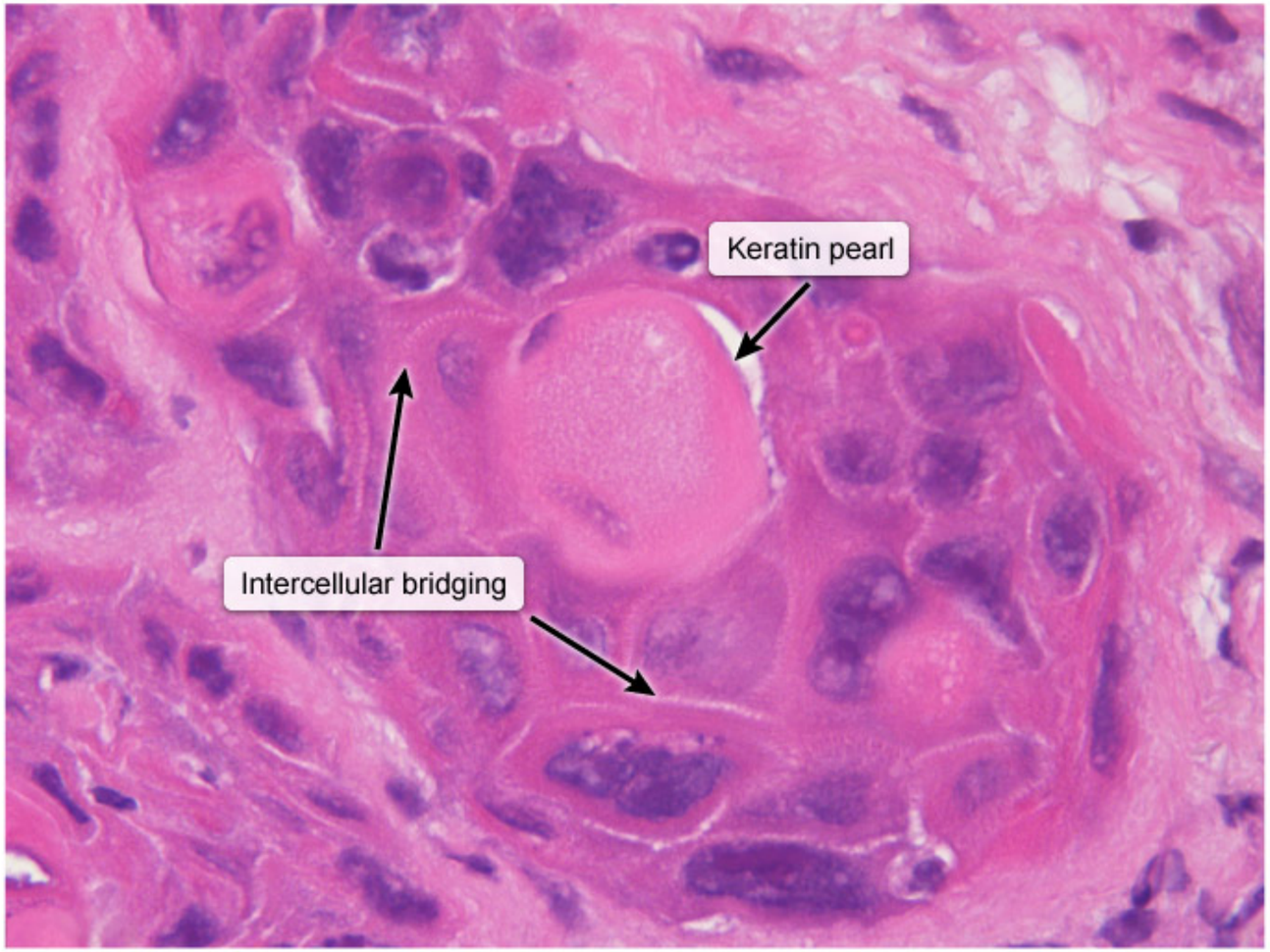

©UWorld

This patient with dysphagia, a base of tongue mass, and cervical lymphadenopathy likely has mucosal **head and neck squamous cell**

©UWorld

This patient with dysphagia, a base of tongue mass, and cervical lymphadenopathy likely has mucosal **head and neck squamous cell carcinoma** (HNSCC). HNSCC arises from the mucosa of the upper aerodigestive tract after accrual of multiple somatic mutations, often caused by the mutagens found in **tobacco**. Other risk factors for HNSCC include age >40, alcohol use, and immunocompromised status. There has also been a dramatic increase in HNSCC due to **human papillomavirus** (HPV), which may be seen in younger, nonsmoking patients.

Characteristic pathologic findings of HNSCC include sheets of polygonal cells with abundant eosinophilic cytoplasm that invade the submucosa and surrounding structures; **intercellular bridges** and keratin pearls (ie, **irregular foci of keratinization**) are commonly seen on light microscopy.

(Choice A) Squamous papillomas are benign tumors that have fibrovascular cores surrounded by squamous epithelium. They can occur in the mucosa of the upper aerodigestive tract but would not spread to regional lymph nodes as they are not malignant.

(Choice B) Adenocarcinomas arise due to mutation of glandular cells and often retain glandular features and some glandular functions, including the production of mucin. The mucosa of the head and neck is made of stratified squamous cells; therefore, cancers arising from this region often retain some features of squamous cells (eg, production of keratin).

(Choice C) Oral candidiasis (ie, thrush) often has an inflammatory infiltrate with pseudohyphae and can present with oral lesions. However, oral candidiasis characteristically appears as white plaques on an erythematous base throughout the mucosa. It does not form a palpable mass or cause firm cervical adenopathy.

(Choice E) Although non-Hodgkin lymphoma (characterized by nodular proliferation of lymphocytic follicles) can rarely present in a tonsil, it is unlikely to occur in the base of tongue and is overall much less common than HNSCC, especially in a patient age >60 with a long history of tobacco use.

Educational objective:
Head and neck squamous cell carcinoma is likely in a patient with cervical adenopathy and a base of tongue mass, especially with a history of tobacco use. Classic histologic findings include intercellular bridges and keratin pearls.

Pathology	Hematology & Oncology	Head and neck cancers
Subject	System	Topic

carcinoma (HNSCC). HNSCC arises from the mucosa of the upper aerodigestive tract after accrual of multiple somatic mutations, often caused by the mutagens found in **tobacco**. Other risk factors for HNSCC include age >40, alcohol use, and immunocompromised status. There has also been a dramatic increase in HNSCC due to **human papillomavirus** (HPV), which may be seen in younger, nonsmoking patients.

Characteristic pathologic findings of HNSCC include sheets of polygonal cells with abundant eosinophilic cytoplasm that invade the submucosa and surrounding structures; **intercellular bridges** and keratin pearls (ie, **irregular foci of keratinization**) are commonly seen on light microscopy.

(Choice A) Squamous papillomas are benign tumors that have fibrovascular cores surrounded by squamous epithelium. They can occur in the mucosa of the upper aerodigestive tract but would not spread to regional lymph nodes as they are not malignant.

(Choice B) Adenocarcinomas arise due to mutation of glandular cells and often retain glandular features and some glandular functions, including the production of mucin. The mucosa of the head and neck is made of stratified squamous cells; therefore, cancers arising from this region often retain some features of squamous cells (eg, production of keratin).

(Choice C) Oral candidiasis (ie, thrush) often has an inflammatory infiltrate with pseudohyphae and can present with oral lesions. However, oral candidiasis characteristically appears as white plaques on an erythematous base throughout the mucosa. It does not form a palpable mass or cause firm cervical adenopathy.

(Choice E) Although non-Hodgkin lymphoma (characterized by nodular proliferation of lymphocytic follicles) can rarely present in a tonsil, it is unlikely to occur in the base of tongue and is overall much less common than HNSCC, especially in a patient age >60 with a long history of tobacco use.

Educational objective:
Head and neck squamous cell carcinoma is likely in a patient with cervical adenopathy and a base of tongue mass, especially with a history of tobacco use. Classic histologic findings include intercellular bridges and keratin pearls.

Pathology	Hematology & Oncology	Head and neck cancers
Subject	System	Topic

Copyright © UWorld. All rights reserved.

1
2
3
4
5
6
7
8
9
10
11
12
13
14
15
16
17
18
19
20
21
22
23
24
25
26
27
28
29
30

A 5-week-old boy is brought to the emergency department after having tonic-clonic movements of his left upper and lower extremity that lasted approximately 3 minutes. The patient was born at home at 38 weeks gestation to a 23-year-old primigravida. The patient's mother received prenatal care, took prenatal vitamins, and had a healthy diet during pregnancy. The infant's newborn screen was positive for cystic fibrosis, and confirmatory testing is pending. The infant has been breastfeeding and gaining weight well. He has never taken any medications and also has received no vaccinations. On examination, the infant is postictal but no longer seizing. A head CT scan shows a right-sided intracranial hemorrhage. Which of the following is the most likely cause of this infant's presentation?

A. Failure of amino acid hydroxylation

B. Failure of fatty acid oxidation

C. Failure of rhodopsin production

D. Impaired gamma carboxylation

E. Ineffective erythropoiesis

F. Reduced activation of intranuclear receptors

Submit

1
2
3
4
5
6
7
8
9
10
11
12
13
14
15
16
17
18
19
20
21
22
23
24
25
26
27
28
29
30

A 5-week-old boy is brought to the emergency department after having tonic-clonic movements of his left upper and lower extremity that lasted approximately 3 minutes. The patient was born at home at 38 weeks gestation to a 23-year-old primigravida. The patient's mother received prenatal care, took prenatal vitamins, and had a healthy diet during pregnancy. The infant's newborn screen was positive for cystic fibrosis, and confirmatory testing is pending. The infant has been breastfeeding and gaining weight well. He has never taken any medications and also has received no vaccinations. On examination, the infant is postictal but no longer seizing. A head CT scan shows a right-sided intracranial hemorrhage. Which of the following is the most likely cause of this infant's presentation?

A. Failure of amino acid hydroxylation (10%)
B. Failure of fatty acid oxidation (7%)
C. Failure of rhodopsin production (3%)
✓ D. Impaired gamma carboxylation (68%)
E. Ineffective erythropoiesis (3%)
F. Reduced activation of intranuclear receptors (6%)

Omitted
Correct answer
D

68%
Answered correctly

01 sec
Time Spent

05/19/2020
Last Updated

Explanation

Neonatal vitamin K deficiency

Neonatal vitamin K deficiency	
Etiology	• Low vitamin K stores at birth (poor placental transfer, sterile gut, low content in breast milk) • Neonatal liver cannot use vitamin K efficiently
Presentation	• Intracranial, gastrointestinal, cutaneous, umbilical & surgical site **bleeding**
Prevention	• Intramuscular vitamin K at birth

©UWorld

Vitamin K, a **fat-soluble** vitamin, is an **essential cofactor** for gamma-glutamyl carboxylase, an enzyme that **carboxylates coagulation factors II, VII, IX, and X**.

Infants are born with low vitamin K stores due to poor transplacental transfer. Their livers are unable to use vitamin K efficiently and breast milk is low in this vitamin. Additional risk factors for neonatal vitamin K deficiency include parental **refusal of vitamin K prophylaxis** at birth and **exclusive breastfeeding**. Patients with **cystic fibrosis (CF)** are also at risk for vitamin K deficiency due to malabsorption of fat-soluble vitamins.

Vitamin K deficiency can result in a **life-threatening bleeding diathesis**, such as intracranial hemorrhage and profuse bleeding from the gastrointestinal tract, umbilicus, and surgical sites. Deficiency is prevented by intramuscular supplementation at birth.

(Choice A) Vitamin C (ascorbic acid) deficiency results in defective collagen synthesis due to failure of hydroxylation of proline and lysine. Mucosal bleeding and bruising are typical manifestations in severely malnourished individuals and those who misuse drugs or alcohol. However, breast milk provides adequate ascorbic acid.

©UWorld

Vitamin K, a **fat-soluble** vitamin, is an **essential cofactor** for gamma-glutamyl carboxylase, an enzyme that **carboxylates coagulation factors II, VII, IX, and X**.

Infants are born with low vitamin K stores due to poor transplacental transfer. Their livers are unable to use vitamin K efficiently and breast milk is low in this vitamin. Additional risk factors for neonatal vitamin K deficiency include parental **refusal of vitamin K prophylaxis** at birth and **exclusive breastfeeding**. Patients with **cystic fibrosis (CF)** are also at risk for vitamin K deficiency due to malabsorption of fat-soluble vitamins.

Vitamin K deficiency can result in a **life-threatening bleeding diathesis**, such as intracranial hemorrhage and profuse bleeding from the gastrointestinal tract, umbilicus, and surgical sites. Deficiency is prevented by intramuscular supplementation at birth.

(Choice A) Vitamin C (ascorbic acid) deficiency results in defective collagen synthesis due to failure of hydroxylation of proline and lysine. Mucosal bleeding and bruising are typical manifestations in severely malnourished individuals and those who misuse drugs or alcohol. However, breast milk provides adequate ascorbic acid.

(Choice B) Vitamin B3 (niacin) deficiency results in failure of formation of nicotinamide adenine dinucleotide (NAD) and nicotinamide adenine dinucleotide phosphate (NADP), which are required for fatty acid oxidation and synthesis, respectively. Niacin deficiency presents with pellagra (ie, dermatitis, diarrhea, and dementia).

(Choices C and F) Patients with CF are at risk for deficiency of both vitamins A and D. Reduced activation of intranuclear receptors occurs in vitamin D deficiency, and exclusively breastfed infants require vitamin D supplementation to prevent hypocalcemia and rickets due to the low content of this vitamin in breast milk. Vitamin A deficiency impairs rhodopsin formation and leads to night blindness and xerophthalmia.

(Choice E) Erythropoiesis requires folate, and deficiency leads to megaloblastic anemia.

Educational objective:
Vitamin K is necessary for the carboxylation and functionality of coagulation factors II, VII, IX, and X. Newborns who do not receive prophylactic supplementation are at risk for bleeding complications. Patients with cystic fibrosis are also at risk for vitamin K deficiency due to poor absorption of fat-soluble vitamins.

References

Vitamin K deficiency can result in a **life-threatening bleeding diathesis**, such as intracranial hemorrhage and profuse bleeding from the gastrointestinal tract, umbilicus, and surgical sites. Deficiency is prevented by intramuscular supplementation at birth.

(Choice A) Vitamin C (ascorbic acid) deficiency results in defective collagen synthesis due to failure of hydroxylation of proline and lysine. Mucosal bleeding and bruising are typical manifestations in severely malnourished individuals and those who misuse drugs or alcohol. However, breast milk provides adequate ascorbic acid.

(Choice B) Vitamin B3 (niacin) deficiency results in failure of formation of nicotinamide adenine dinucleotide (NAD) and nicotinamide adenine dinucleotide phosphate (NADP), which are required for fatty acid oxidation and synthesis, respectively. Niacin deficiency presents with pellagra (ie, dermatitis, diarrhea, and dementia).

(Choices C and F) Patients with CF are at risk for deficiency of both vitamins A and D. Reduced activation of intranuclear receptors occurs in vitamin D deficiency, and exclusively breastfed infants require vitamin D supplementation to prevent hypocalcemia and rickets due to the low content of this vitamin in breast milk. Vitamin A deficiency impairs rhodopsin formation and leads to night blindness and xerophthalmia.

(Choice E) Erythropoiesis requires folate, and deficiency leads to megaloblastic anemia.

Educational objective:
Vitamin K is necessary for the carboxylation and functionality of coagulation factors II, VII, IX, and X. Newborns who do not receive prophylactic supplementation are at risk for bleeding complications. Patients with cystic fibrosis are also at risk for vitamin K deficiency due to poor absorption of fat-soluble vitamins.

References

- Rise in late onset vitamin K deficiency bleeding in young infants because of omission or refusal of prophylaxis at birth.
- Vitamin K deficiency bleeding: a case study.

Pathology	Hematology & Oncology	Vitamin k deficiency
Subject	System	Topic

Copyright © UWorld. All rights reserved.

1
2
3
4
5
6
7
8
9
10
11
12
13
14
15
16
17
18
19
20
21
22
23
24
25
26
27
28
29
30

A 10-year-old boy comes to the office for a first visit. His family recently came to the United States as political refugees. The patient's mother says that he has required several blood product transfusions due to anemia, but she does not have prior records available with her. On examination, the patient's temperature is 37.1 C (98.8 F). BMI is 21 kg/m^2. Examination is notable for conjunctival pallor and moderate splenomegaly. Laboratory results are as follows:

Hemoglobin	9.4 g/dL
Platelets	240,000/mm^3

Enzyme assays performed on circulating blood cells demonstrate low pyruvate kinase activity. Which of the following is the most likely cause of this patient's splenomegaly?

- A. Inflammatory infiltration
- B. Myeloproliferative disorder
- C. Passive splenic congestion
- D. Presence of circulating immune complexes
- E. Red pulp hyperplasia
- F. Undegraded metabolite accumulation

Submit

A 10-year-old boy comes to the office for a first visit. His family recently came to the United States as political refugees. The patient's mother says that he has required several blood product transfusions due to anemia, but she does not have prior records available with her. On examination, the patient's temperature is 37.1 C (98.8 F). BMI is 21 kg/m^2. Examination is notable for conjunctival pallor and moderate splenomegaly. Laboratory results are as follows:

Hemoglobin	9.4 g/dL
Platelets	240,000/mm^3

Enzyme assays performed on circulating blood cells demonstrate low pyruvate kinase activity. Which of the following is the most likely cause of this patient's splenomegaly?

- A. Inflammatory infiltration (1%)
- B. Myeloproliferative disorder (5%)
- C. Passive splenic congestion (27%)
- D. Presence of circulating immune complexes (4%)
- ✓ E. Red pulp hyperplasia (35%)
- F. Undegraded metabolite accumulation (25%)

Omitted
Correct answer
E

35%
Answered correctly

02 secs
Time Spent

01/20/2020
Last Updated

Pyruvate kinase is a glycolytic pathway enzyme that converts phosphoenolpyruvate to pyruvate, resulting in the generation of a molecule of **ATP**. Allosteric stimulation of pyruvate kinase (by fructose 1,6-bisphosphate) stimulates glycolysis. Mature red blood cells (RBCs), which do not contain mitochondria, rely on lactate as the main metabolite for glycolysis.

Most of the ATP produced is used for transport of cations against a concentration gradient in the RBC membrane. Therefore, pyruvate kinase deficiency, which results in insufficient ATP production, disrupts this gradient, leading to water and potassium loss, defective maintenance of membrane architecture (echinocyte formation), and **hemolysis**. As reticuloendothelial cells in the splenic **red pulp** are involved in removal of damaged RBCs, their increased activity in the setting of pyruvate kinase deficiency causes them to undergo hyperplasia, resulting in **splenomegaly**.

(Choice A) The spleen is important in fighting infectious pathogens in the body; therefore, many acute and chronic infections lead to enlargement of the spleen due to proliferation of lymphoid tissue.

(Choice B) Disorders such as leukemia and lymphoma result in splenomegaly from neoplastic proliferation of lymphoid tissue within the spleen.

(Choice C) Passive congestion of the spleen with blood occurs in the setting of portal hypertension, splenic vein thrombosis, or congestive heart failure. Resultant splenic sinusoid dilation can lead to splenomegaly.

(Choice D) In infective endocarditis, circulating immune complexes can deposit in the kidneys and the spleen, likely contributing to splenomegaly.

(Choice F) Splenomegaly in the lysosomal storage diseases Niemann-Pick disease and Gaucher disease is due to the accumulation of sphingomyelin and glucocerebrosides, respectively.

Educational objective:
Pyruvate kinase deficiency causes hemolytic anemia due to failure of glycolysis and resultant failure to generate sufficient ATP to maintain erythrocyte structure. In this case, splenic hyperplasia results from increased work of the splenic parenchyma, which must remove these deformed erythrocytes from the circulation.

Pathology	Hematology & Oncology	Hemolytic anemia
Subject	System	Topic

1
2
3
4
5
6
7
8
9
10
11
12
13
14
15
16
17
18
19
20
21
22
23
24
25
26
27
28
29
30

A 35-year-old man is being evaluated for nontender cervical lymphadenopathy that he first noticed while shaving. A biopsy is performed, and a low-magnification image of the lymph node histology is shown below.

Cytogenetic analysis would most likely demonstrate which of the following patterns?

1
2
3
4
5
6
7
8
9
10
11
12
13
14
15
16
17
18
19
20
21
22
23
24
25
26
27
28
29
30

A 35-year-old man is being evaluated for nontender cervical lymphadenopathy that he first noticed while shaving. A biopsy is performed, and a low-magnification image of the lymph node histology is shown below.

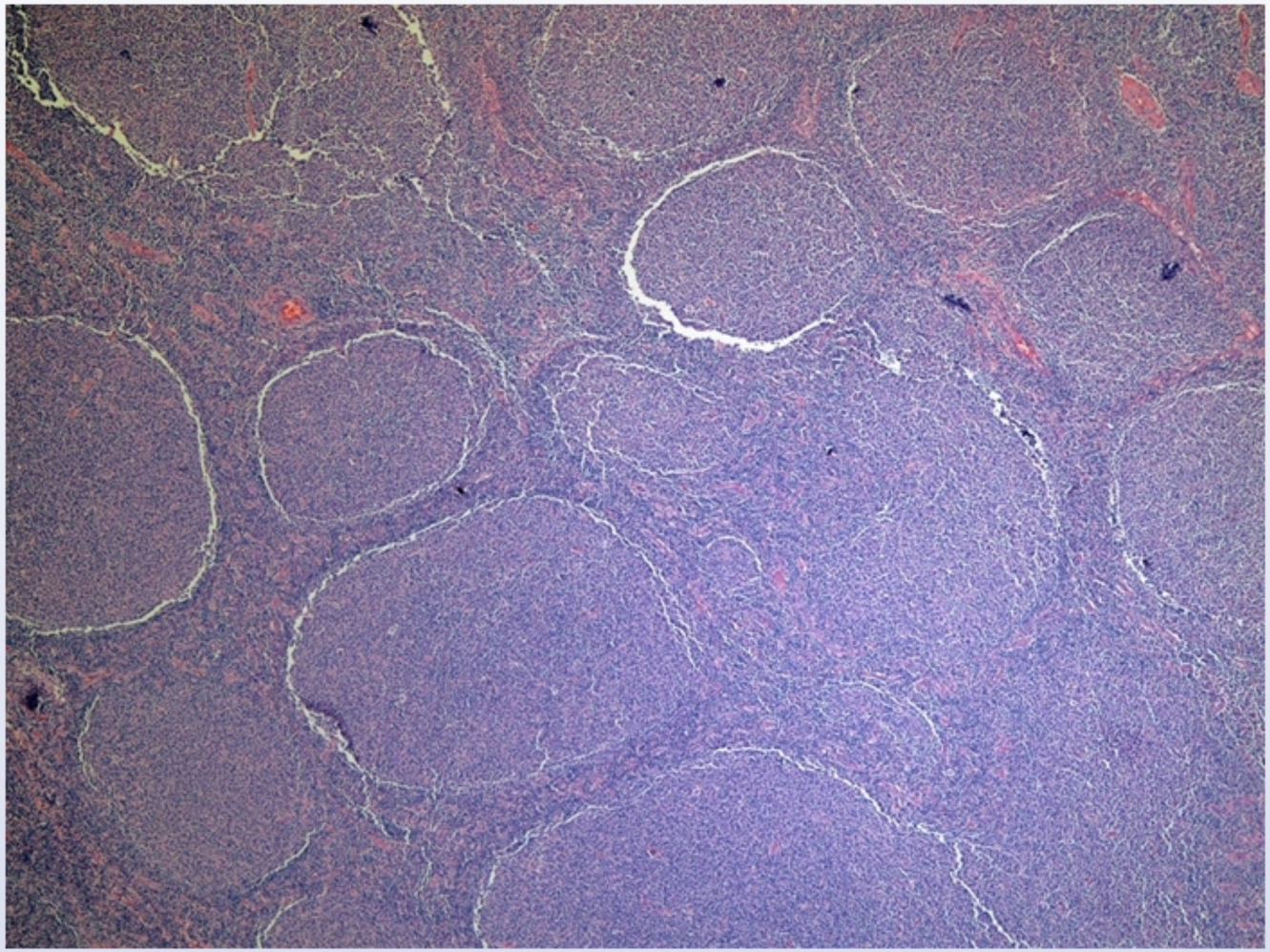

Cytogenetic analysis would most likely demonstrate which of the following patterns?

1
2
3
4
5
6
7
8
9
10
11
12
13
14
15
16
17
18
19
20
21
22
23
24
25
26
27
28
29
30

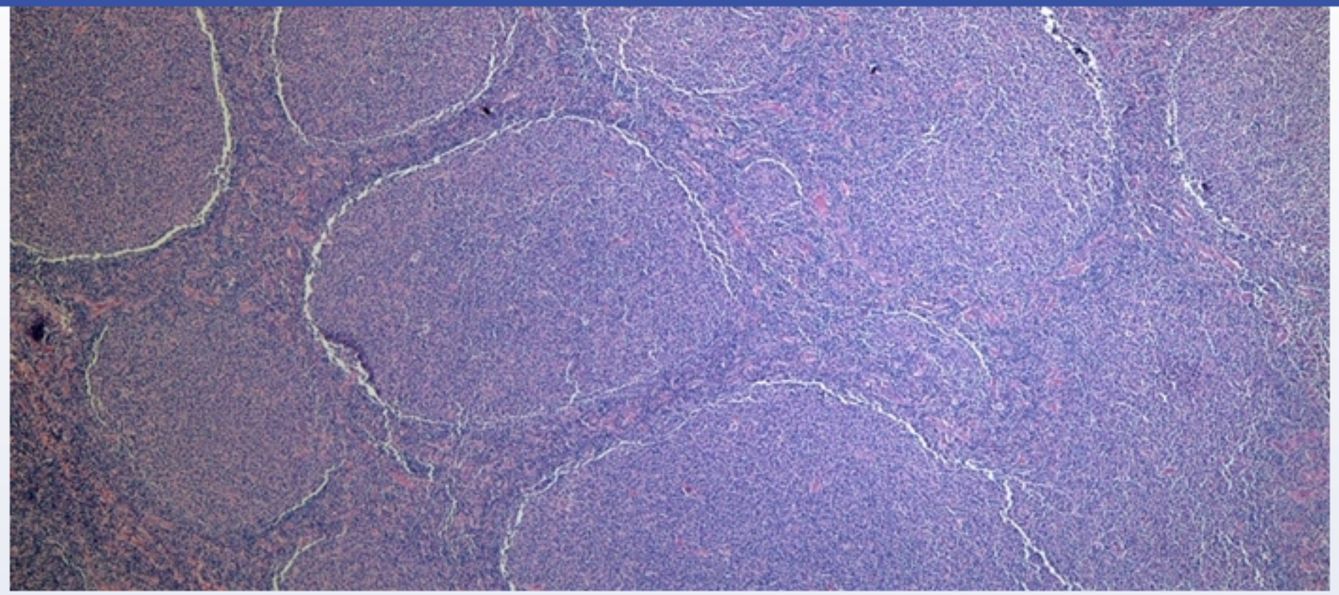

Cytogenetic analysis would most likely demonstrate which of the following patterns?

A. BCL-2 overexpression

B. *BCR-ABL* rearrangement

C. C-MYC overexpression

D. Constitutive tyrosine kinase activation

E. N-MYC overexpression

Submit

1
2
3
4
5
6
7
8
9
10
11
12
13
14
15
16
17
18
19
20
21
22
23
24
25
26
27
28
29
30

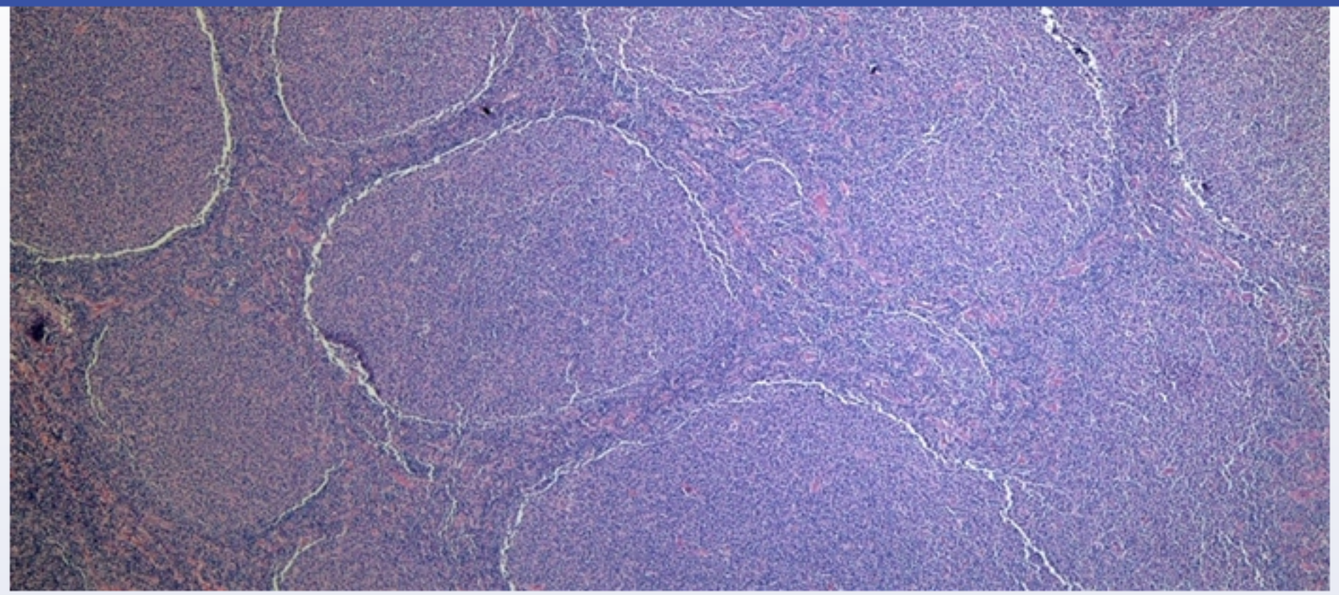

Cytogenetic analysis would most likely demonstrate which of the following patterns?

- A. BCL-2 overexpression (69%)
- B. *BCR-ABL* rearrangement (8%)
- C. C-MYC overexpression (16%)
- D. Constitutive tyrosine kinase activation (3%)
- E. N-MYC overexpression (2%)

Omitted
Correct answer

69%
Answered correctly

10 secs
Time Spent

04/25/2020
Last Updated

1
2
3
4
5
6
7
8
9
10
11
12
13
14
15
16
17
18
19
20
21
22
23
24
25
26
27
28
29
30

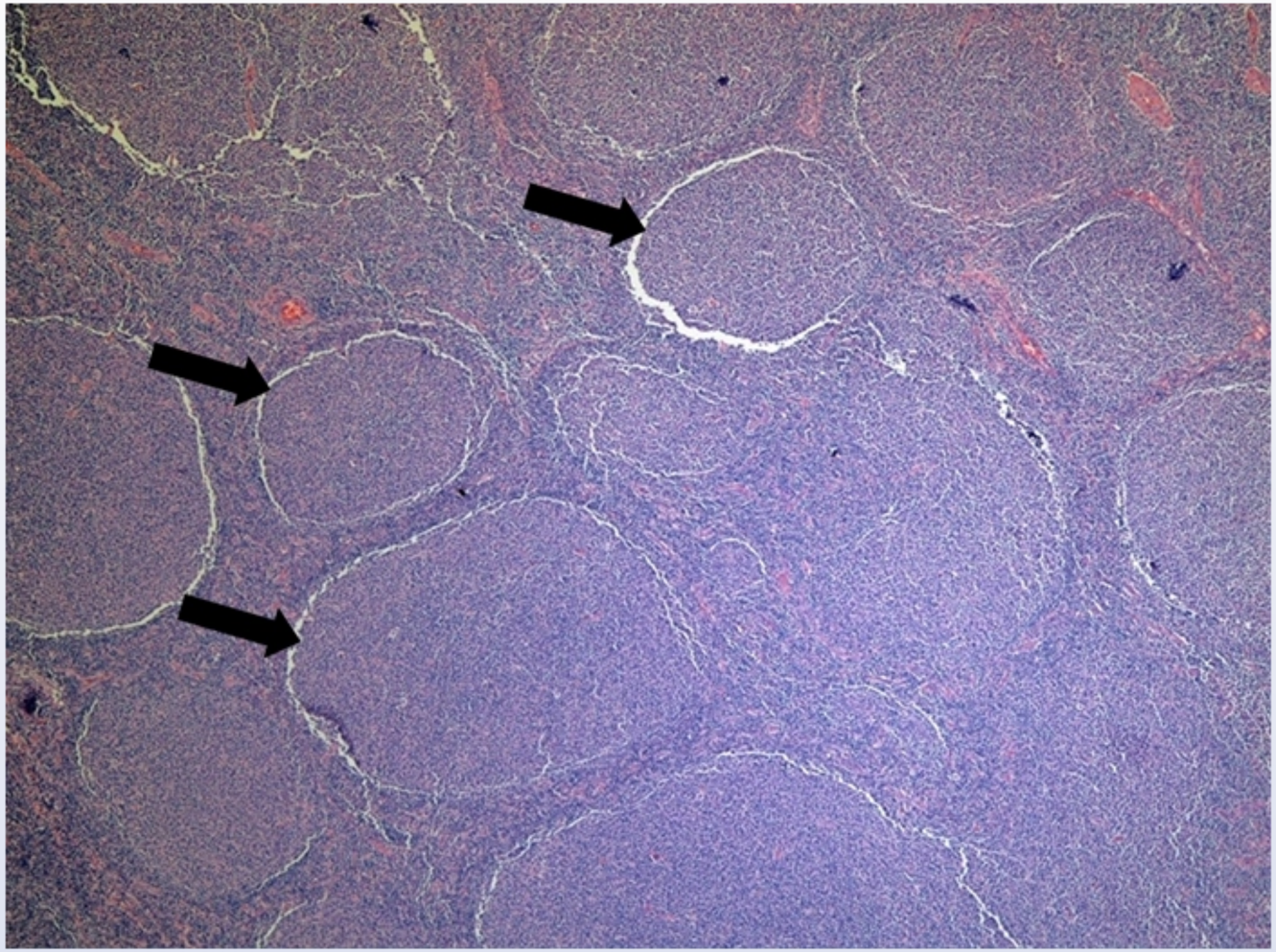

The image demonstrates the classic histology of follicular lymphoma, a type of non-Hodgkin's lymphoma. Follicular lymphoma is a B-cell tumor composed predominantly of centrocytes (small cleaved cells) and fewer numbers of centroblasts (large noncleaved cells). At low magnification, aggregates of packed follicles (arrows) that obscure the normal lymph node architecture are seen. The t(14;18) translocation is found in 80%-90% of follicular lymphomas. The result is overexpression of the antiapoptotic gene product, BCL-2, and tumor formation.

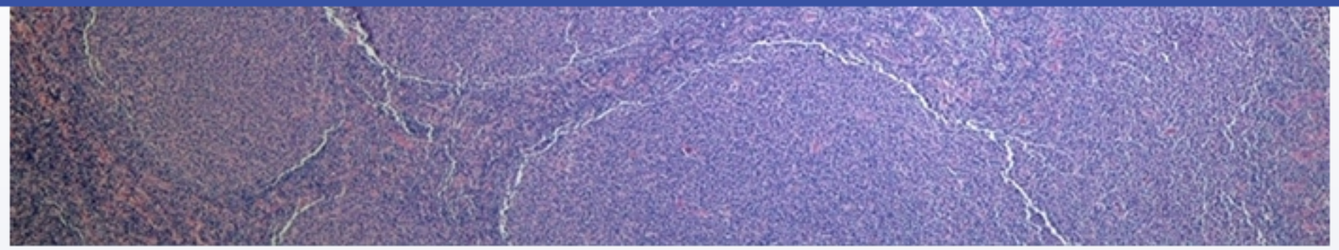

The image demonstrates the classic histology of follicular lymphoma, a type of non-Hodgkin's lymphoma. Follicular lymphoma is a B-cell tumor composed predominantly of centrocytes (small cleaved cells) and fewer numbers of centroblasts (large noncleaved cells). At low magnification, aggregates of packed follicles (arrows) that obscure the normal lymph node architecture are seen. The t(14;18) translocation is found in 80%-90% of follicular lymphomas. The result is overexpression of the antiapoptotic gene product, BCL-2, and tumor formation.

(Choices B and D) *BCR-ABL* rearrangement t(9;22) is found in chronic myelogenous leukemia (CML). CML is a myeloproliferative disorder, not a lymphoproliferative disorder as shown in the image above. The *BCR-ABL* fusion gene directs the synthesis of a constitutively active protein tyrosine kinase that affects multiple intracellular signaling pathways, leading to uncontrolled proliferation.

(Choice C) All Burkitt lymphomas are associated with translocations of the *C-MYC* gene on chromosome 8, usually onto the Ig heavy chain region of chromosome 14 [t(8;14)]. Histologically, Burkitt lymphoma shows a diffuse population of medium-sized lymphocytes with a "starry sky" appearance due to the high proliferation index and high rate of apoptosis.

(Choice E) Overexpression of N-MYC proto-oncogene protein is common in neuroblastoma and small cell carcinoma of the lung.

Educational objective:
Follicular lymphoma is characterized by aggregates of packed follicles that obscure the normal lymph node architecture. Ninety percent of patients with follicular lymphoma have the t(14;18) translocation, which causes overexpression of the antiapoptotic BCL-2 protein.

Pathology	Hematology & Oncology	Nonhodgkin lymphoma
Subject	System	Topic

Copyright © UWorld. All rights reserved.

1
2
3
4
5
6
7
8
9
10
11
12
13
14
15
16
17
18
19
20
21
22
23
24
25
26
27
28
29
30

Exhibit Display

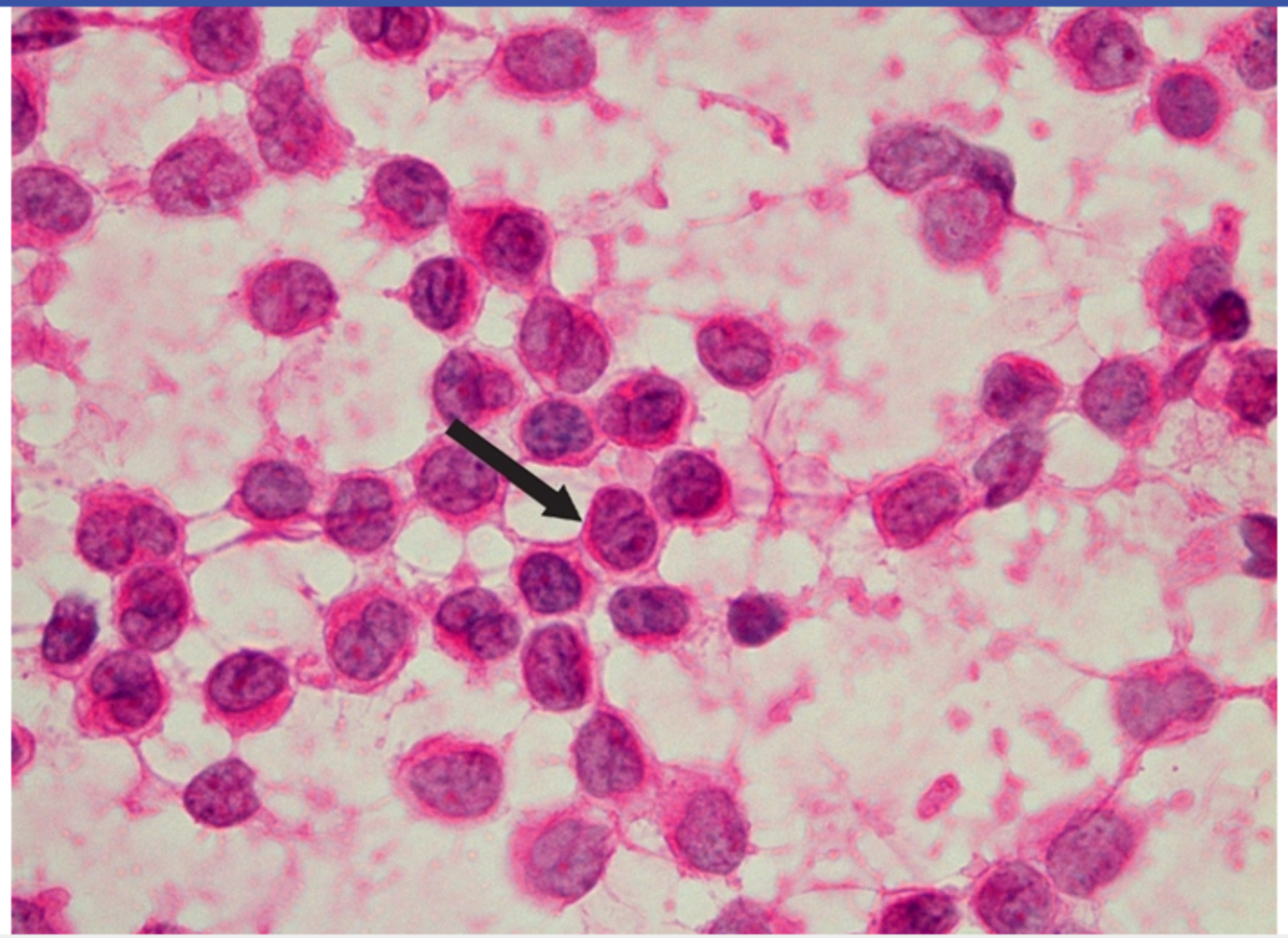

Zoom In | Zoom Out | Reset | Add To New Card | Existing Card

1
2
3
4
5
6
7
8
9
10
11
12
13
14
15
16
17
18
19
20
21
22
23
24
25
26
27
28
29
30

Exhibit Display

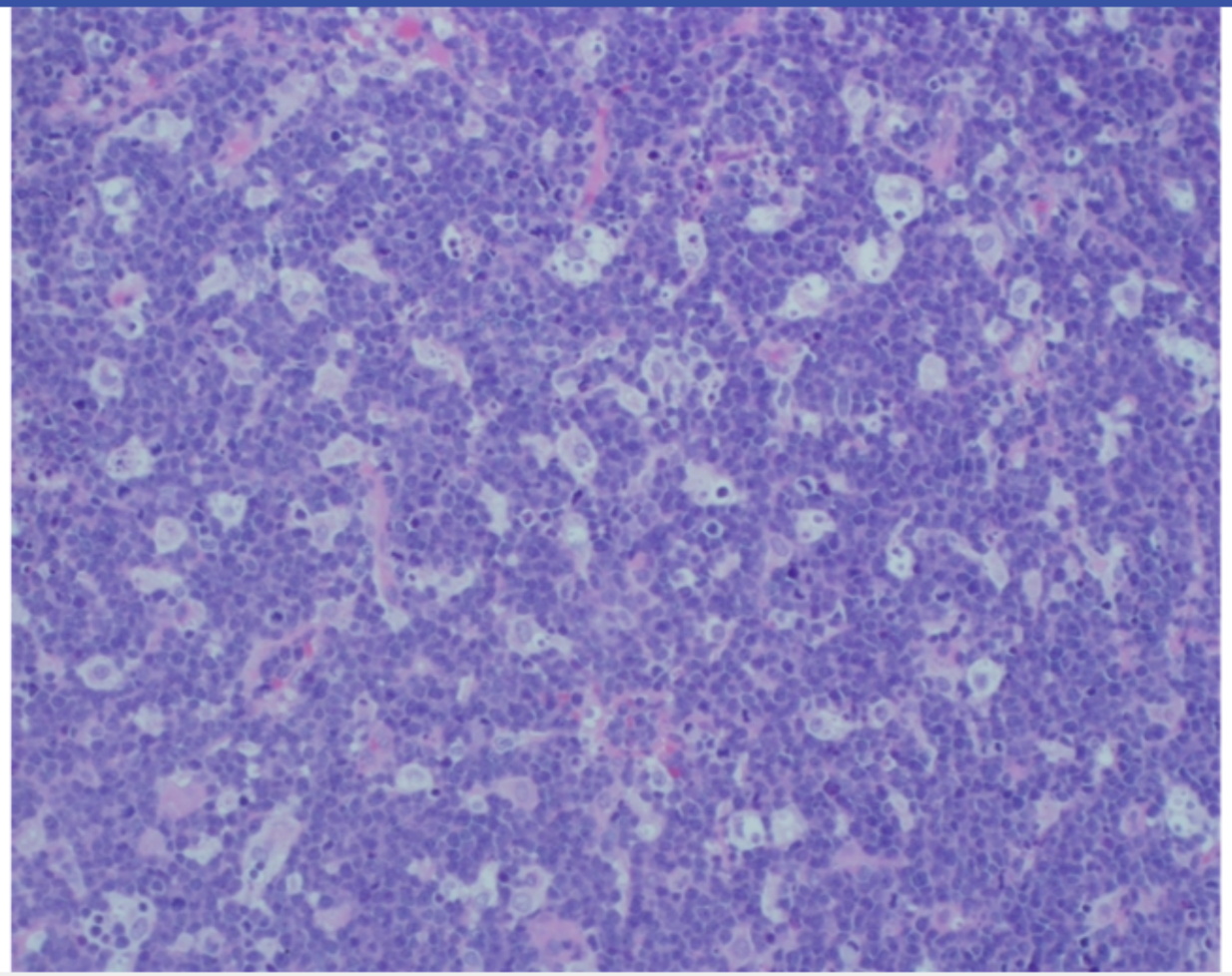

Zoom In | Zoom Out | Reset | Add To New Card | Existing Card

1
2
3
4
5
6
7
8
9
10
11
12
13
14
15
16
17
18
19
20
21
22
23
24
25
26
27
28
29
30

A 72-year-old man comes to the emergency department due to severe chest tightness and dyspnea that started 20 minutes ago at a family dinner. He has never experienced similar symptoms before. The patient's medical conditions include hypertension, hyperlipidemia, type 2 diabetes mellitus, and prostate cancer. He takes multiple medications and has no drug allergies. The patient smoked a pack of cigarettes daily for 30 years and stopped smoking 10 years ago. Chest CT scan with contrast is shown in the image below.

1
2
3
4
5
6
7
8
9
10
11
12
13
14
15
16
17
18
19
20
21
22
23
24
25
26
27
28
29
30

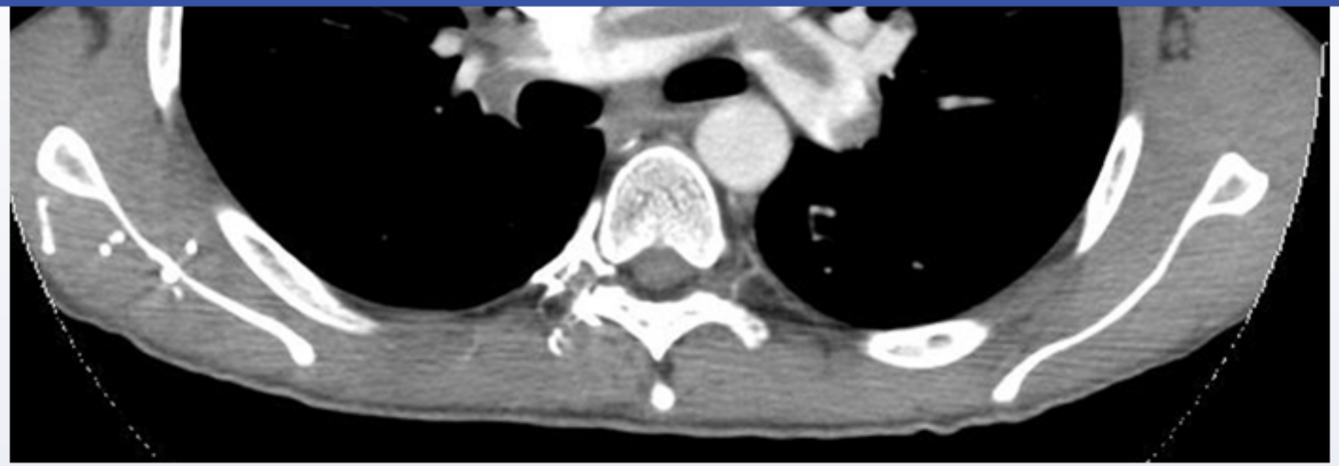

Which of the following factors most likely contributed to this patient's current condition?

- A. Atherosclerosis
- B. Fluid overload
- C. Hypercoagulability
- D. Intimal tear
- E. Noninfectious vasculitis
- F. Pulmonary bleb rupture
- G. Pulmonary metastasis

Submit

1
2
3
4
5
6
7
8
9
10
11
12
13
14
15
16
17
18
19
20
21
22
23
24
25
26
27
28
29
30

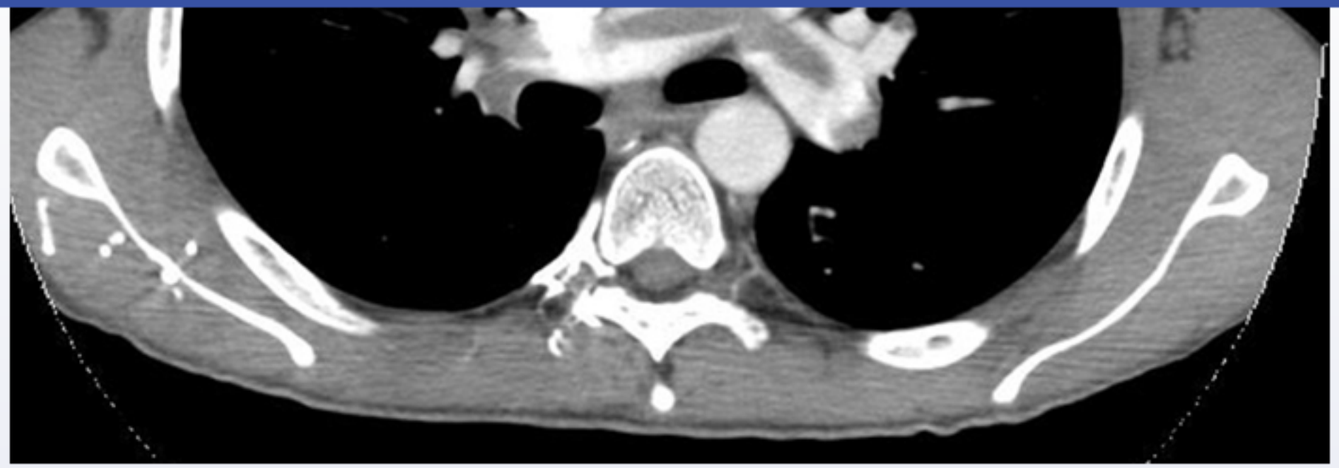

Which of the following factors most likely contributed to this patient's current condition?

- A. Atherosclerosis (18%)
- B. Fluid overload (1%)
- ✓ C. Hypercoagulability (63%)
- D. Intimal tear (11%)
- E. Noninfectious vasculitis (0%)
- F. Pulmonary bleb rupture (2%)
- G. Pulmonary metastasis (1%)

Omitted
Correct answer

63%
Answered correctly

04 secs
Time Spent

04/23/2020
Last Updated

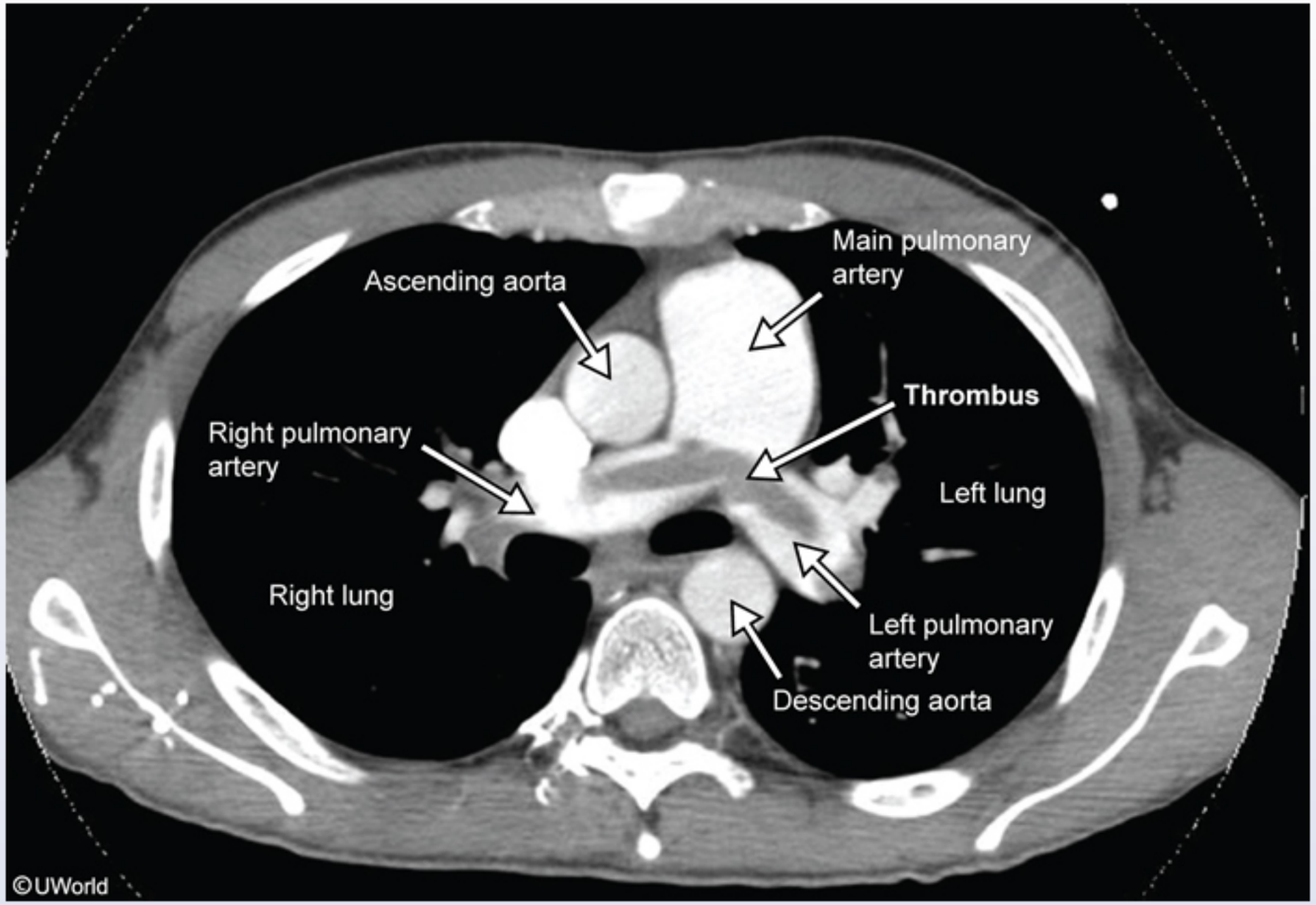

This patient is experiencing sudden-onset chest tightness and dyspnea, and CT scan of the chest shows a **saddle pulmonary embolism** (PE) straddling the bifurcation of the main pulmonary artery. The main pulmonary artery, usually comparable in diameter to the ascending aorta, is significantly dilated due to the proximal increase in hydrostatic pressure from the PE. Saddle PE can result in sudden cardiac death or severe hypotension, but many patients can be hemodynamically stable on presentation.

Venous thromboembolism (VTE) (ie, PE or deep venous thrombosis) results from the Virchow triad of endothelial injury, venous stasis, and a

©UWorld

This patient is experiencing sudden-onset chest tightness and dyspnea, and CT scan of the chest shows a **saddle pulmonary embolism** (PE) straddling the bifurcation of the main pulmonary artery. The main pulmonary artery, usually comparable in diameter to the ascending aorta, is significantly dilated due to the proximal increase in hydrostatic pressure from the PE. Saddle PE can result in sudden cardiac death or severe hypotension, but many patients can be hemodynamically stable on presentation.

Venous thromboembolism (VTE) (ie, PE or deep venous thrombosis) results from the Virchow triad of endothelial injury, venous stasis, and a **hypercoagulable** state. **Malignancy** (eg, prostate cancer) induces a hypercoagulable state and is a strong risk factor for VTE. Active **smoking** is also a risk factor as it contributes to endothelial injury and a hypercoagulable state. Age plays a role as well, as older individuals tend to be more **sedentary** and are more prone to venous stasis.

(Choice A) Atherosclerosis primarily affects the higher pressure arteries in the systemic circulation (eg, aorta, popliteal arteries, carotid arteries) and the coronary arteries. Significant atherosclerosis in the relatively low-pressure pulmonary arteries is rare.

(Choice B) Fluid overload causes pulmonary edema, typically appearing as alveolar ground glass opacities on CT scan. This patient's lungs appear clear of airspace disease.

(Choice D) An intimal tear can lead to aortic dissection, which classically manifests as severe chest pain radiating to the back. Pulmonary artery dissection is extremely rare.

(Choice E) Pulmonary vasculitis (eg, granulomatosis with polyangiitis) could cause dyspnea and chest tightness but would demonstrate an interstitial pattern on CT scan, sometimes leading to pulmonary hemorrhage.

(Choice F) Rupture of pulmonary blebs (thin-walled, air-filled subpleural structures) leads to pneumothorax.

(Choice G) For pulmonary metastasis to cause significant dyspnea, multiple lesions would likely be present. There is no evidence of lung masses on this patient's CT scan.

Educational objective:
Saddle pulmonary embolism straddles the bifurcation of the main pulmonary artery. Venous thromboembolism (ie, pulmonary embolism or deep vein thrombosis) arises due to the Virchow triad of endothelial injury, venous stasis, and a hypercoagulable state. Malignancy causes a hypercoagulable state and is a strong risk factor for venous thromboembolism.

1
2
3
4
5
6
7
8
9
10
11
12
13
14
15
16
17
18
19
20
21
22
23
24
25
26
27
28
29
30

Exhibit Display

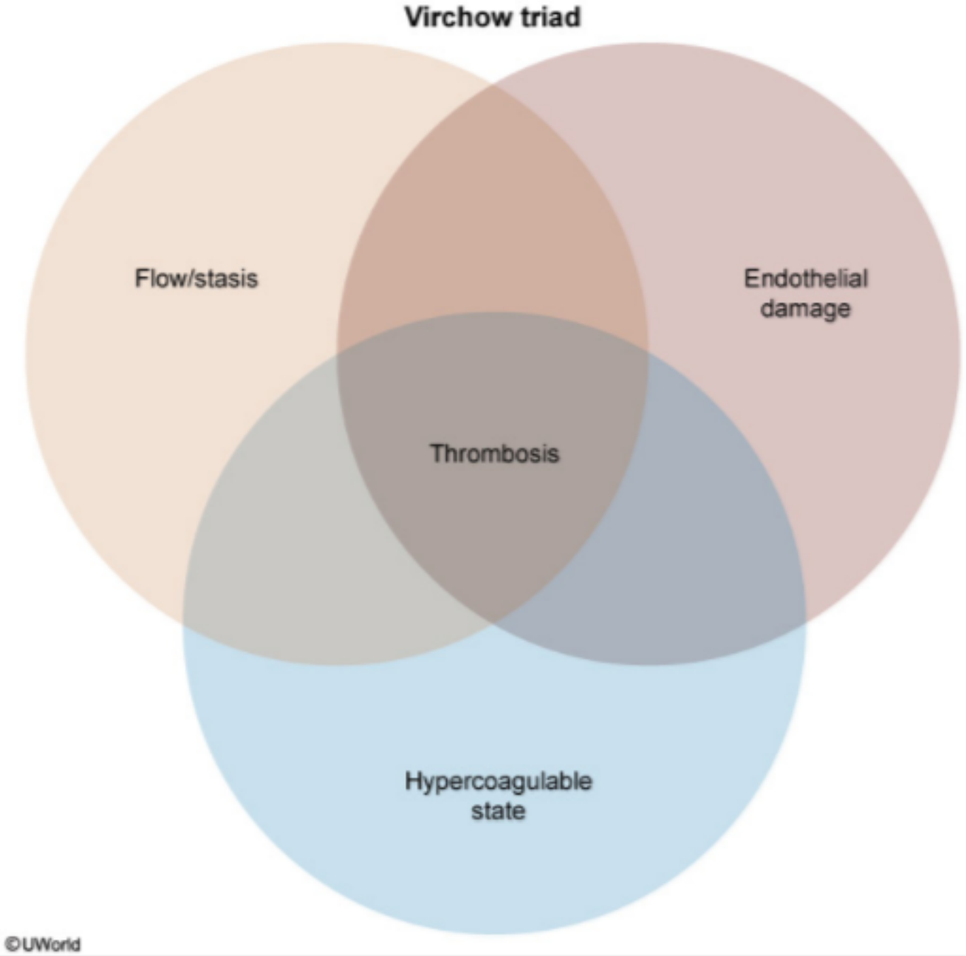

Zoom In | Zoom Out | Reset | Add To New Card | Existing Card

1
2
3
4
5
6
7
8
9
10
11
12
13
14
15
16
17
18
19
20
21
22
23
24
25
26
27
28
29
30

Exhibit Display

Aortic dissection

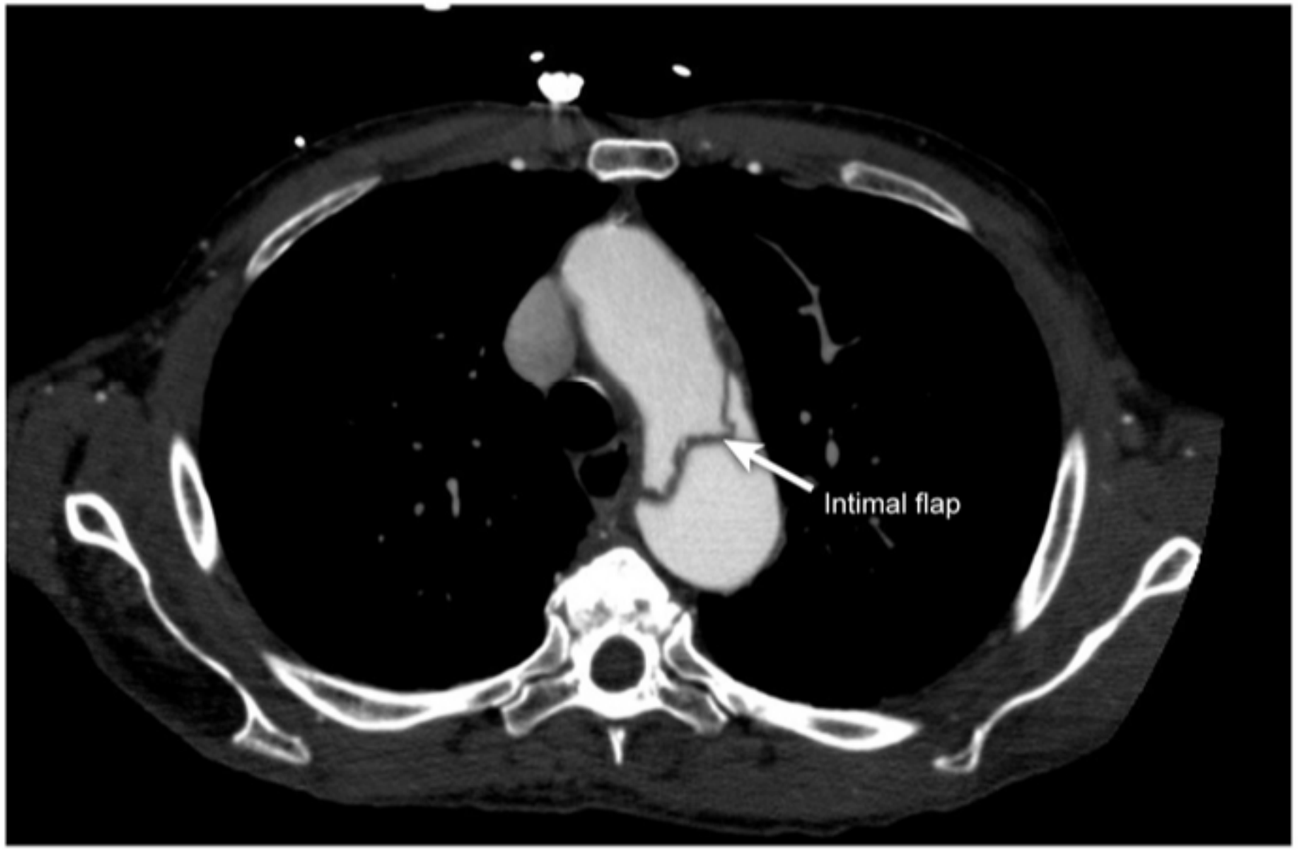

©UWorld

Zoom In | Zoom Out | Reset | Add To New Card | Existing Card

significantly dilated due to the proximal increase in hydrostatic pressure from the PE. Saddle PE can result in sudden cardiac death or severe hypotension, but many patients can be hemodynamically stable on presentation.

Exhibit Display

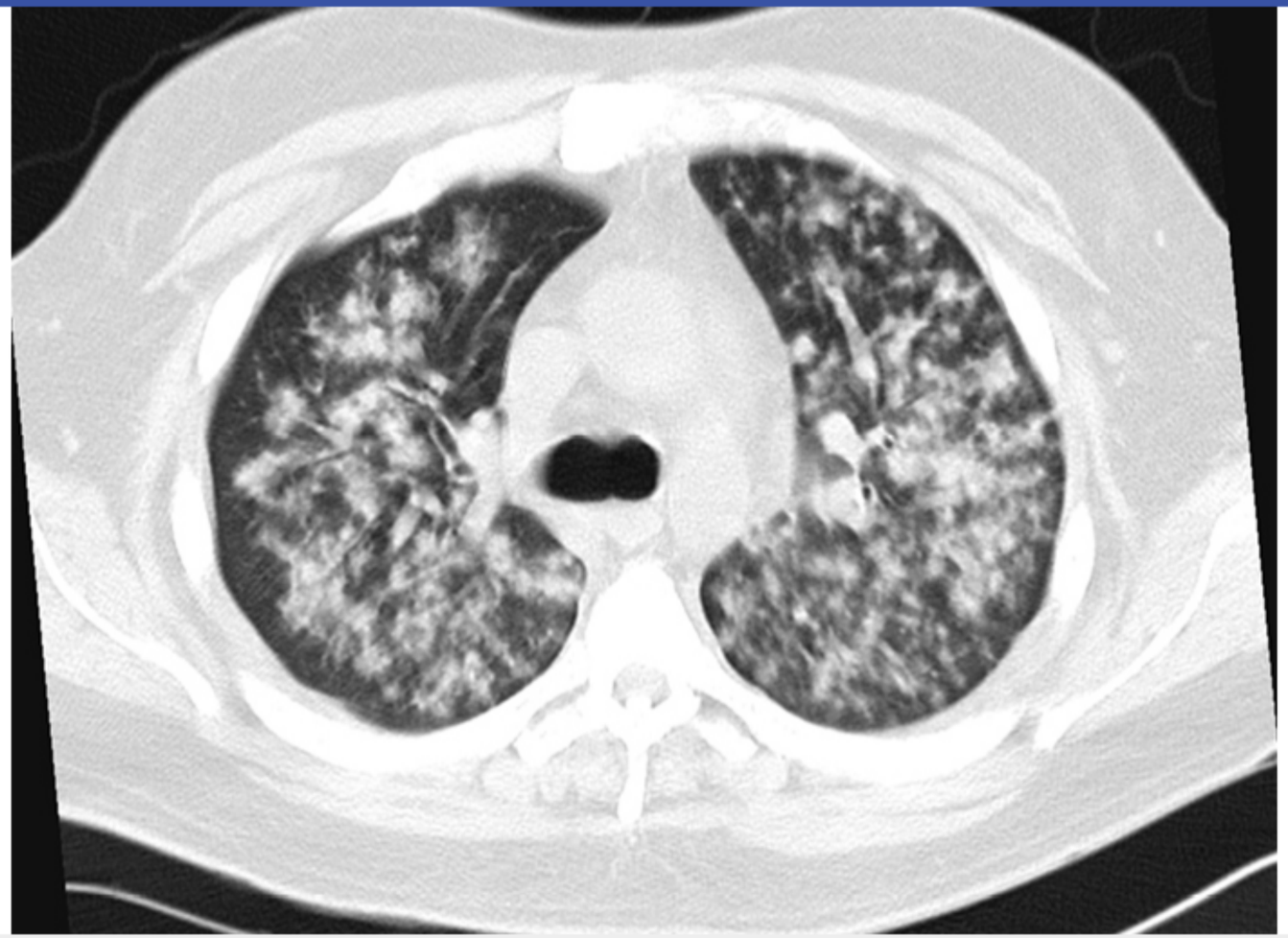

Zoom In | Zoom Out | Reset | Add To New Card | Existing Card

Saddle pulmonary embolism: is it as bad as it looks? A community hospital experience

1
2
3
4
5
6
7
8
9
10
11
12
13
14
15
16
17
18
19
20
21
22
23
24
25
26
27
28
29
30

Exhibit Display

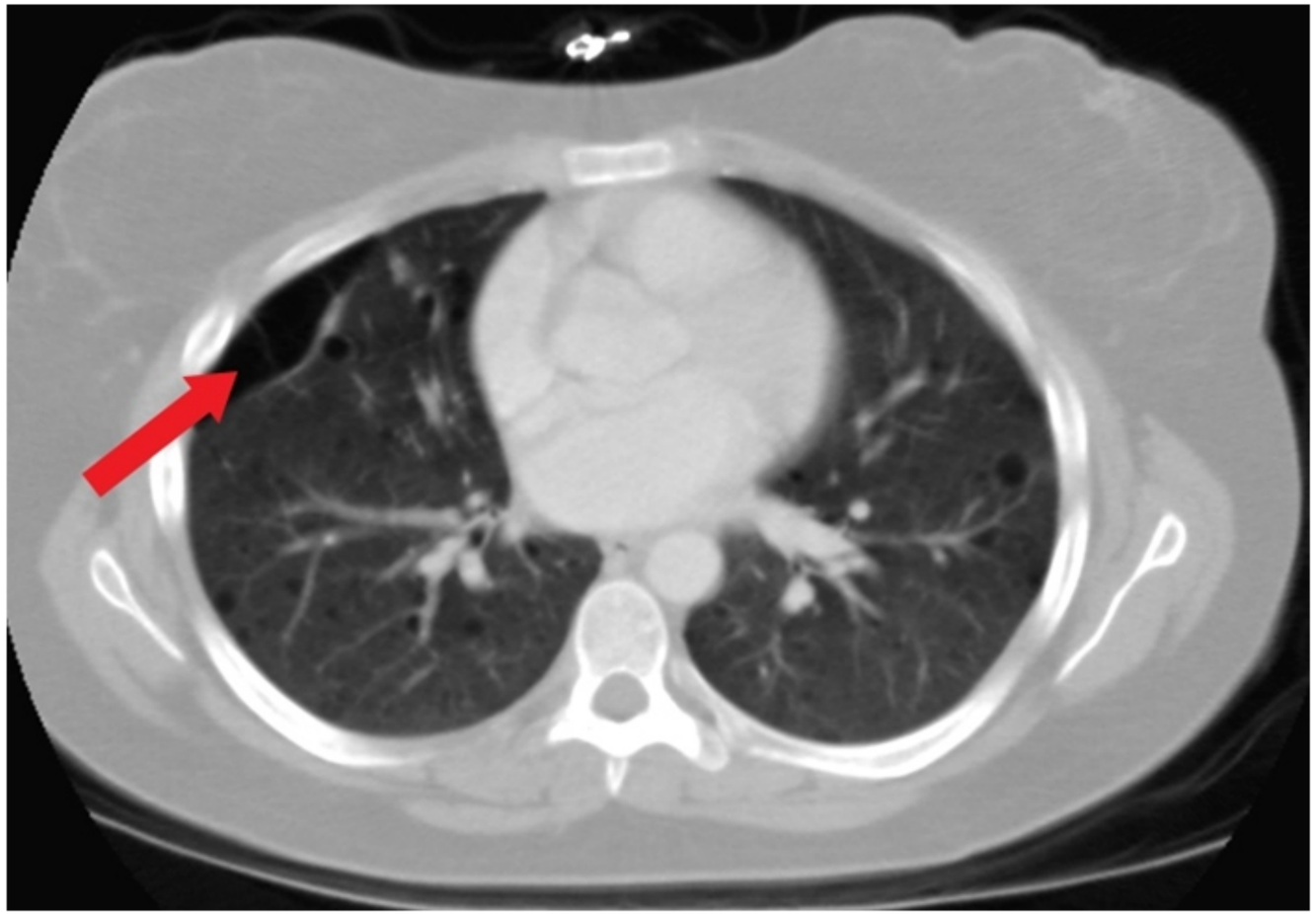

Zoom In | Zoom Out | Reset | Add To New Card | Existing Card

1
2
3
4
5
6
7
8
9
10
11
12
13
14
15
16
17
18
19
20
21
22
23
24
25
26
27
28
29
30

Exhibit Display

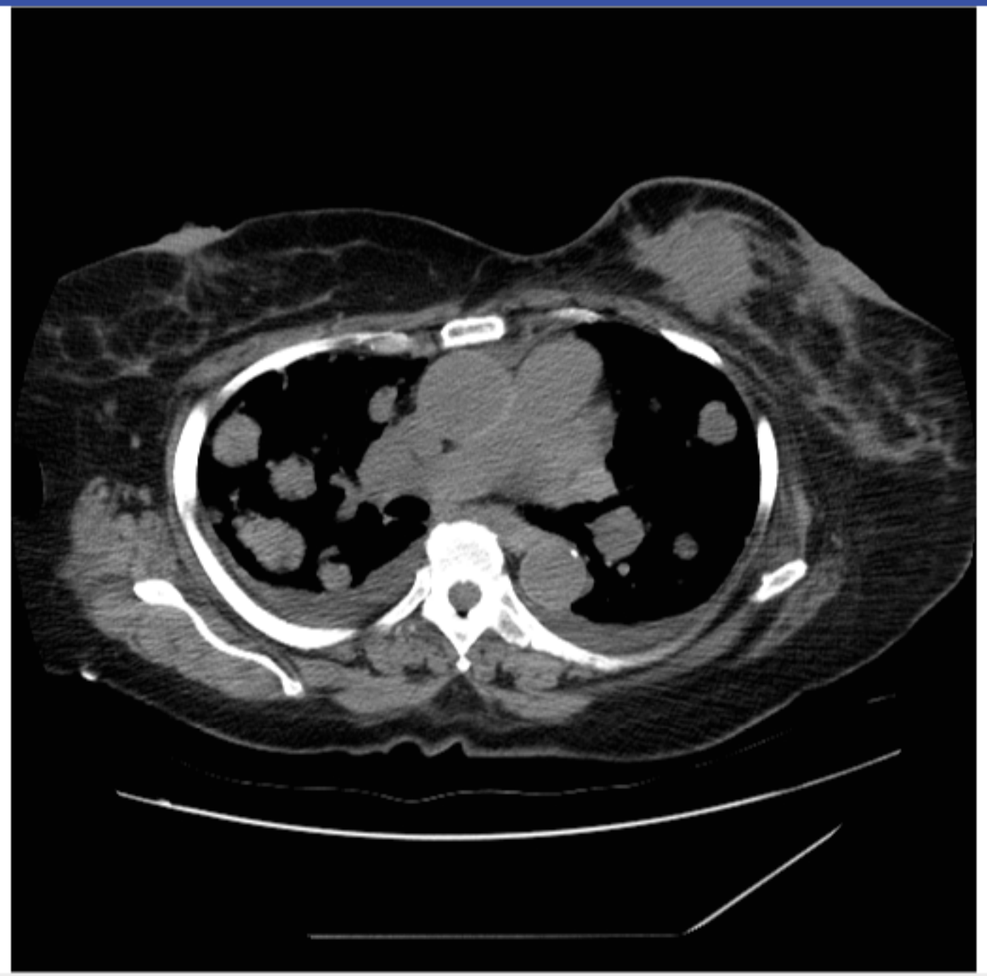

Zoom In | Zoom Out | Reset | Add To New Card | Existing Card

1
2
3
4
5
6
7
8
9
10
11
12
13
14
15
16
17
18
19
20
21
22
23
24
25
26
27
28
29
30

A 4-year-old male dies in the hospital from overwhelming infection. Autopsy findings include bone deformities and hepatosplenomegaly. Clumps of erythroid precursor cells are found in the liver and the spleen. The presence of these precursor cells is most likely related to which of the following conditions?

A. Frequent transfusions
B. Immune deficiency
C. Erythropoietin deficiency
D. Chronic hemolysis
E. Iron deficiency
F. Cyanocobalamin deficiency
G. Portal hypertension

Submit

A 4-year-old male dies in the hospital from overwhelming infection. Autopsy findings include bone deformities and hepatosplenomegaly. Clumps of erythroid precursor cells are found in the liver and the spleen. The presence of these precursor cells is most likely related to which of the following conditions?

- A. Frequent transfusions (7%)
- B. Immune deficiency (11%)
- C. Erythropoietin deficiency (8%)
- ✓ D. Chronic hemolysis (66%)
- E. Iron deficiency (2%)
- F. Cyanocobalamin deficiency (2%)
- G. Portal hypertension (0%)

Omitted
Correct answer
D

66%
Answered correctly

02 secs
Time Spent

02/03/2020
Last Updated

Explanation

The presence of erythroid precursor cells in the liver and spleen is indicative of extramedullary hematopoiesis, a condition characterized by erythropoietin-stimulated, hyperplastic marrow cell invasion of extramedullary organs. Extramedullary hematopoiesis is most frequently caused by severe chronic hemolytic anemias, such as β-thalassemia (which the child depicted here may well have had).

The presence of erythroid precursor cells in the liver and spleen is indicative of extramedullary hematopoiesis, a condition characterized by erythropoietin-stimulated, hyperplastic marrow cell invasion of extramedullary organs. Extramedullary hematopoiesis is most frequently caused by severe chronic hemolytic anemias, such as β-thalassemia (which the child depicted here may well have had).

Extramedullary hematopoiesis can cause a range of skeletal abnormalities. The expanding mass of progenitor cells in the bone marrow thins the bony cortex and impairs bone growth. Pathologic fractures are common in the most symptomatic of children. Maxillary overgrowth and frontal bossing are associated with the characteristic "chipmunk facies" observed in the pediatric population.

(Choice A) Red blood cell transfusions limit extramedullary hematopoiesis by reducing hypoxia.

(Choice B) Immune deficiencies are not frequently associated with red blood cell hemolysis.

(Choice C) Erythropoietin deficiency is observed in patients with chronic renal disease and would be associated with anemia, not extramedullary hematopoiesis.

(Choice E) Iron deficiency results in a relative depression of erythropoietic activity and is not associated with extramedullary hematopoiesis.

(Choice F) Cyanocobalamin (vitamin B_{12}) deficiency causes a megaloblastic anemia that is not associated with extramedullary hematopoiesis.

(Choice G) Intrahepatic extramedullary hematopoiesis can cause portal hypertension, and portal hypertension can cause hepatosplenomegaly. The reverse is not true, however.

Educational Objective:
The presence of erythroid precursors in organs such as the liver and spleen is indicative of extramedullary hematopoiesis, a condition characterized by erythropoietin-stimulated, hyperplastic marrow cell invasion of extramedullary organs. Extramedullary hematopoiesis is most frequently caused by severe chronic hemolytic anemias, such as β-thalassemia.

Pathology	Hematology & Oncology	Hemolytic anemia
Subject	System	Topic

Copyright © UWorld. All rights reserved.

The presence of erythroid precursor cells in the liver and spleen is indicative of extramedullary hematopoiesis, a condition characterized by erythropoietin-stimulated, hyperplastic marrow cell invasion of extramedullary organs. Extramedullary hematopoiesis is most frequently caused by severe chronic hemolytic anemias, such as β-thalassemia (which the child depicted here may well have had).

Extramedullary hematopoiesis can cause a range of skeletal abnormalities. The expanding mass of progenitor cells in the bone marrow thins the bony cortex and impairs bone growth. Pathologic fractures are common in the most symptomatic of children. Maxillary overgrowth and frontal bossing are associated with the characteristic "chipmunk facies" observed in the pediatric population.

(Choice A) Red blood cell transfusions limit extramedullary hematopoiesis by reducing hypoxia.

(Choice B) Immune deficiencies are not frequently associated with red blood cell hemolysis.

(Choice C) Erythropoietin deficiency is observed in patients with chronic renal disease and would be associated with anemia, not extramedullary hematopoiesis.

(Choice E) Iron deficiency results in a relative depression of erythropoietic activity and is not associated with extramedullary hematopoiesis.

(Choice F) Cyanocobalamin (vitamin B_{12}) deficiency causes a megaloblastic anemia that is not associated with extramedullary hematopoiesis.

(Choice G) Intrahepatic extramedullary hematopoiesis can cause portal hypertension, and portal hypertension can cause hepatosplenomegaly. The reverse is not true, however.

Educational Objective:
The presence of erythroid precursors in organs such as the liver and spleen is indicative of extramedullary hematopoiesis, a condition characterized by erythropoietin-stimulated, hyperplastic marrow cell invasion of extramedullary organs. Extramedullary hematopoiesis is most frequently caused by severe chronic hemolytic anemias, such as β-thalassemia.

Pathology	Hematology & Oncology	Hemolytic anemia
Subject	System	Topic

Copyright © UWorld. All rights reserved.

1
2
3
4
5
6
7
8
9
10
11
12
13
14
15
16
17
18
19
20
21
22
23
24
25
26
27
28
29
30

A 72-year-old man is brought into the hospital by paramedics after he was found disoriented and wandering in the street. He has a past medical history of dementia, hypertension, and stroke. Physical examination reveals a disoriented, thin-appearing male. His gingivae are swollen and bleed easily. Ecchymoses are noted on his legs. The laboratory values are provided below:

Hemoglobin	9.6 g/dL
Platelets	152,000/mm^3
White blood cell count	4,500/mm^3
Blood urea nitrogen	28 mg/dL
Serum creatinine	0.8 mg/dL
Prothrombin time	11 sec
Partial thromboplastin time	30 sec

Which of the following is most likely responsible for this patient's ecchymoses?

A. Platelet dysfunction
B. Endothelial cell dysfunction
C. Hepatic dysfunction
D. Water soluble vitamin deficiency
E. Fat soluble vitamin deficiency
F. Zinc deficiency

bleed easily. Ecchymoses are noted on his legs. The laboratory values are provided below:

Hemoglobin	9.6 g/dL
Platelets	152,000/mm^3
White blood cell count	4,500/mm^3
Blood urea nitrogen	28 mg/dL
Serum creatinine	0.8 mg/dL
Prothrombin time	11 sec
Partial thromboplastin time	30 sec

Which of the following is most likely responsible for this patient's ecchymoses?

A. Platelet dysfunction
B. Endothelial cell dysfunction
C. Hepatic dysfunction
D. Water soluble vitamin deficiency
E. Fat soluble vitamin deficiency
F. Zinc deficiency

Submit

1 2 3 4 5 6 7 8 9 10 11 12 13 14 15 16 17 18 19 20 21 22 23 24 25 26 27 28 29 30

bleed easily. Ecchymoses are noted on his legs. The laboratory values are provided below:

Hemoglobin	9.6 g/dL
Platelets	152,000/mm^3
White blood cell count	4,500/mm^3
Blood urea nitrogen	28 mg/dL
Serum creatinine	0.8 mg/dL
Prothrombin time	11 sec
Partial thromboplastin time	30 sec

Which of the following is most likely responsible for this patient's ecchymoses?

A. Platelet dysfunction (14%)
B. Endothelial cell dysfunction (3%)
C. Hepatic dysfunction (4%)
✓ D. Water soluble vitamin deficiency (64%)
E. Fat soluble vitamin deficiency (9%)
F. Zinc deficiency (3%)

Omitted
Correct answer

64%
Answered correctly

04 secs
Time Spent

03/28/2020
Last Updated

Explanation

Vitamin C (ascorbic acid) is a water soluble vitamin that functions as a cofactor in numerous biochemical processes, including collagen synthesis. Deficiency in vitamin C ("scurvy") is most commonly due to insufficient intake, which tends to occur in the setting of chronic drug or alcohol abuse, malnourishment, or old age.

Cutaneous signs of scurvy include phrynoderma (perifollicular hyperkeratosis), coiled hair, and poor wound healing. Mucosal findings include **bleeding gums** and loose teeth. Hemorrhagic complications include ecchymoses and petechiae, hemarthrosis, intramuscular bleeding, and bleeding within the central nervous system, gastrointestinal tract, and genitourinary system. Normocytic, normochromic anemia is typical, while **coagulation studies** (including PT and PTT) are **normal**. Treatment is with vitamin C supplementation, and symptomatic improvement is expected within days.

(Choice A) Common causes of platelet dysfunction in the elderly include uremia and NSAID use. This patient has mild dehydration and prerenal azotemia, which should not cause platelet dysfunction. Similarly, while this patient might be taking aspirin because of his stroke history, aspirin alone would not cause bleeding gums.

(Choice B) Endothelial cell dysfunction can cause von Willebrand disease. However, this condition typically presents earlier in life and is associated with a prolonged PTT.

(Choice C) Hepatic dysfunction can cause prolongation of both PT and PTT or prolongation of PT with a normal PTT. This patient has a normal PT and PTT.

(Choice E) Deficiency in vitamin K (a fat soluble vitamin) results in a prolonged PT.

(Choice F) Zinc deficiency is characterized by an erosive dermatitis of the hands and feet and the perioral, perianal and periocular regions. Other findings include diarrhea, conjunctivitis, and impaired wound healing.

Educational objective:
Vitamin C deficiency (scurvy) is associated with coiled hair, perifollicular keratosis, hemorrhage, easy bruising, bleeding gums, and loose teeth. The PT, PTT, and platelet count are normal.

malnourishment, or old age.

Cutaneous signs of scurvy include phrynoderma (perifollicular hyperkeratosis), coiled hair, and poor wound healing. Mucosal findings include **bleeding gums** and loose teeth. Hemorrhagic complications include ecchymoses and petechiae, hemarthrosis, intramuscular bleeding, and bleeding within the central nervous system, gastrointestinal tract, and genitourinary system. Normocytic, normochromic anemia is typical, while **coagulation studies** (including PT and PTT) are **normal**. Treatment is with vitamin C supplementation, and symptomatic improvement is expected within days.

(Choice A) Common causes of platelet dysfunction in the elderly include uremia and NSAID use. This patient has mild dehydration and prerenal azotemia, which should not cause platelet dysfunction. Similarly, while this patient might be taking aspirin because of his stroke history, aspirin alone would not cause bleeding gums.

(Choice B) Endothelial cell dysfunction can cause von Willebrand disease. However, this condition typically presents earlier in life and is associated with a prolonged PTT.

(Choice C) Hepatic dysfunction can cause prolongation of both PT and PTT or prolongation of PT with a normal PTT. This patient has a normal PT and PTT.

(Choice E) Deficiency in vitamin K (a fat soluble vitamin) results in a prolonged PT.

(Choice F) Zinc deficiency is characterized by an erosive dermatitis of the hands and feet and the perioral, perianal and periocular regions. Other findings include diarrhea, conjunctivitis, and impaired wound healing.

Educational objective:
Vitamin C deficiency (scurvy) is associated with coiled hair, perifollicular keratosis, hemorrhage, easy bruising, bleeding gums, and loose teeth. The PT, PTT, and platelet count are normal.

Pathology	Hematology & Oncology	Vitamin C deficiency
Subject	System	Topic

Copyright © UWorld. All rights reserved.

1
2
3
4
5
6
7
8
9
10
11
12
13
14
15
16
17
18
19
20
21
22
23
24
25
26
27
28
29
30

A 68-year-old man comes to the office with a few months of severe fatigue and a 6.8-kg (15-lb) unintentional loss in weight. The patient has no significant medical history and has not seen a physician in many years. He takes no medications and does not use tobacco, alcohol, or illicit drugs. Physical examination shows mucosal pallor with no scleral icterus. The lungs are clear on auscultation, and heart sounds are normal. Abdominal examination shows mild hepatomegaly and a markedly enlarged spleen. Stool guaiac testing is negative. Laboratory results show pancytopenia, and peripheral blood smear is shown below.

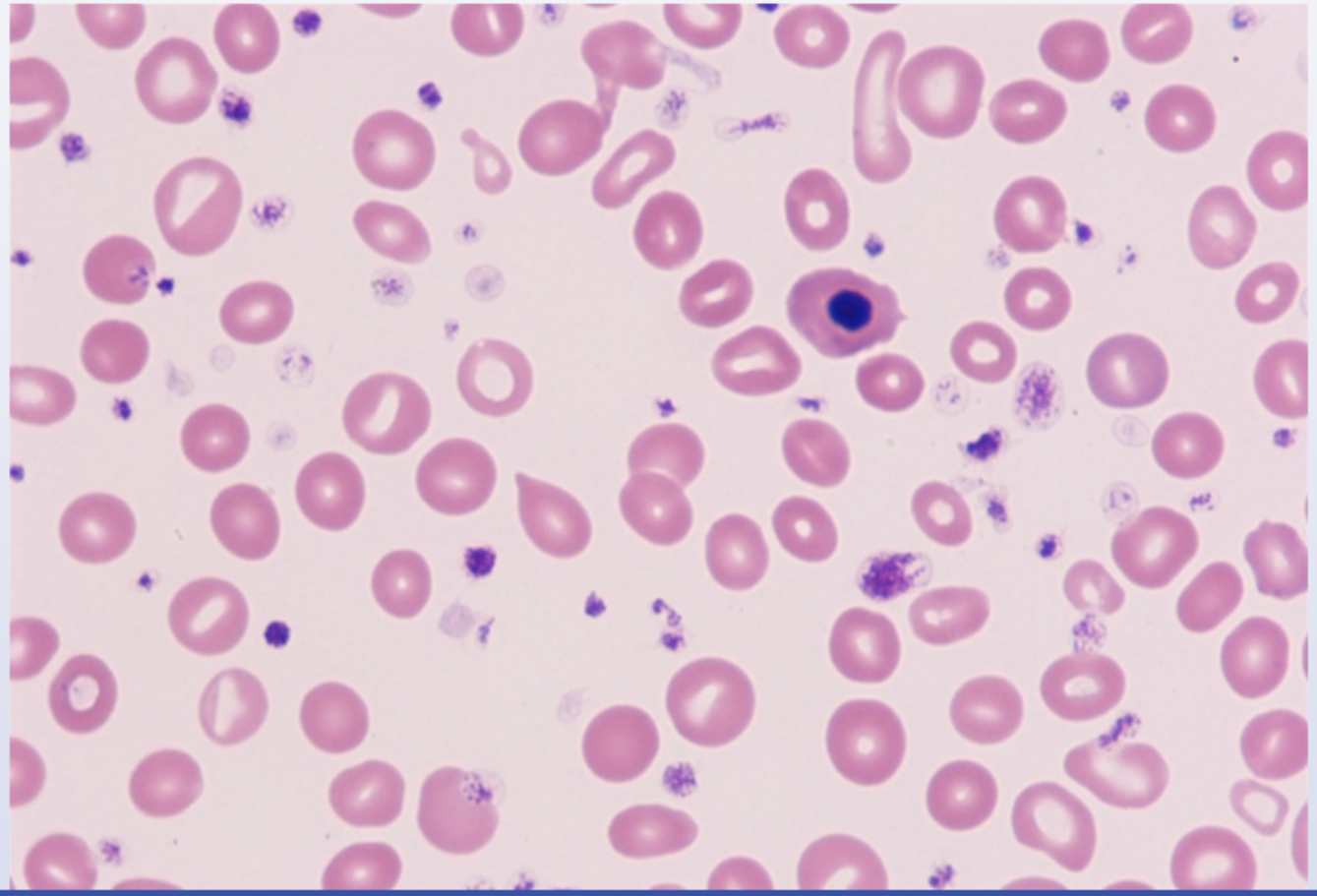

1
2
3
4
5
6
7
8
9
10
11
12
13
14
15
16
17
18
19
20
21
22
23
24
25
26
27
28
29
30

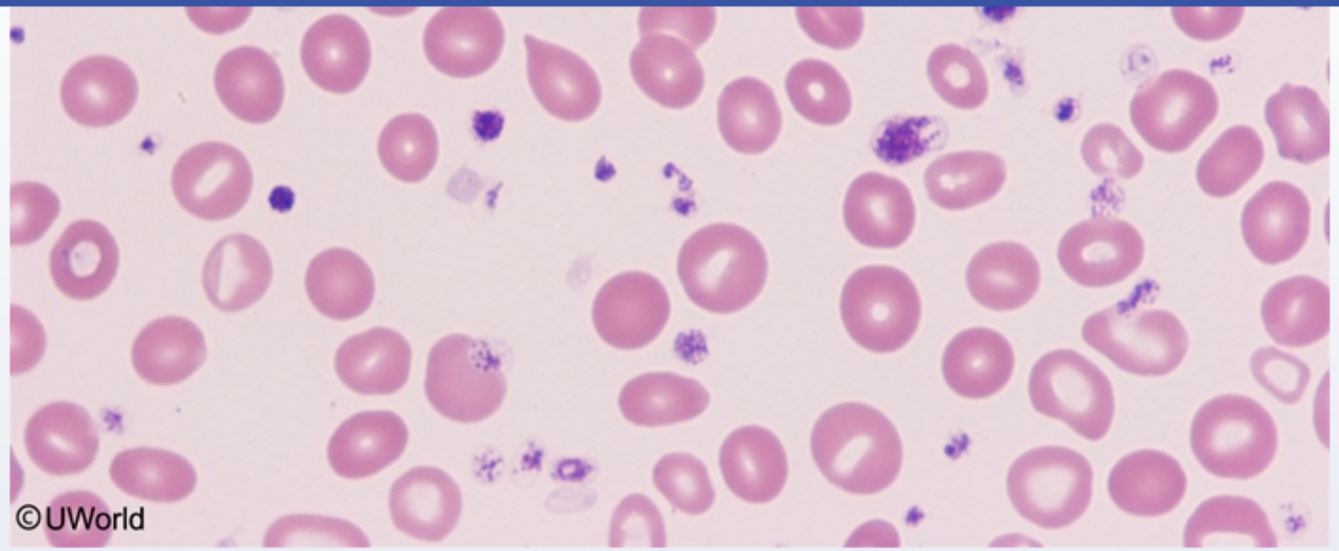

Bone marrow aspiration is attempted but yields no marrow, and a bone marrow biopsy is subsequently performed. Which of the following findings is most likely to be observed in this patient's bone marrow?

A. Diffusely fibrotic marrow with clusters of megakaryocytes

B. Hypercellular marrow composed of clusters of plasma cells

C. Increased staining for storage iron in marrow macrophages

D. Marrow replaced by dysplastic cells of all 3 lineages

E. Severely hypocellular marrow replaced by adipose cells

Submit

1
2
3
4
5
6
7
8
9
10
11
12
13
14
15
16
17
18
19
20
21
22
23
24
25
26
27
28
29
30

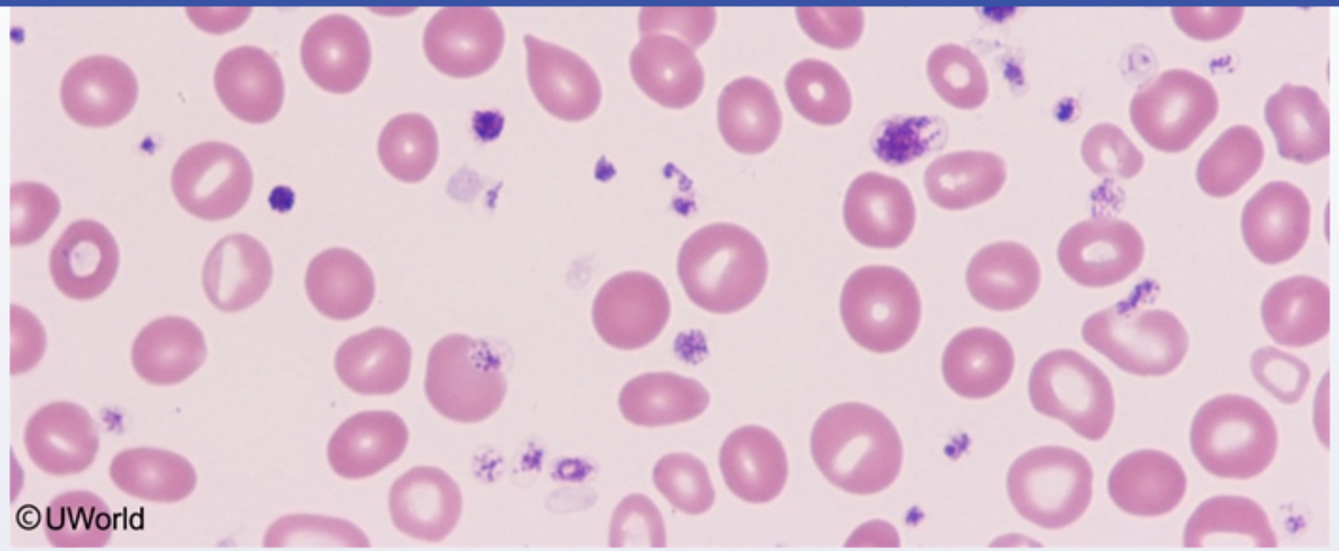

Bone marrow aspiration is attempted but yields no marrow, and a bone marrow biopsy is subsequently performed. Which of the following findings is most likely to be observed in this patient's bone marrow?

- ✓ A. Diffusely fibrotic marrow with clusters of megakaryocytes (61%)
- B. Hypercellular marrow composed of clusters of plasma cells (3%)
- C. Increased staining for storage iron in marrow macrophages (1%)
- D. Marrow replaced by dysplastic cells of all 3 lineages (7%)
- E. Severely hypocellular marrow replaced by adipose cells (26%)

Omitted
Correct answer

61%
Answered correctly

06 secs
Time Spent

01/28/2020
Last Updated

1
2
3
4
5
6
7
8
9
10
11
12
13
14
15
16
17
18
19
20
21
22
23
24
25
26
27
28
29
30

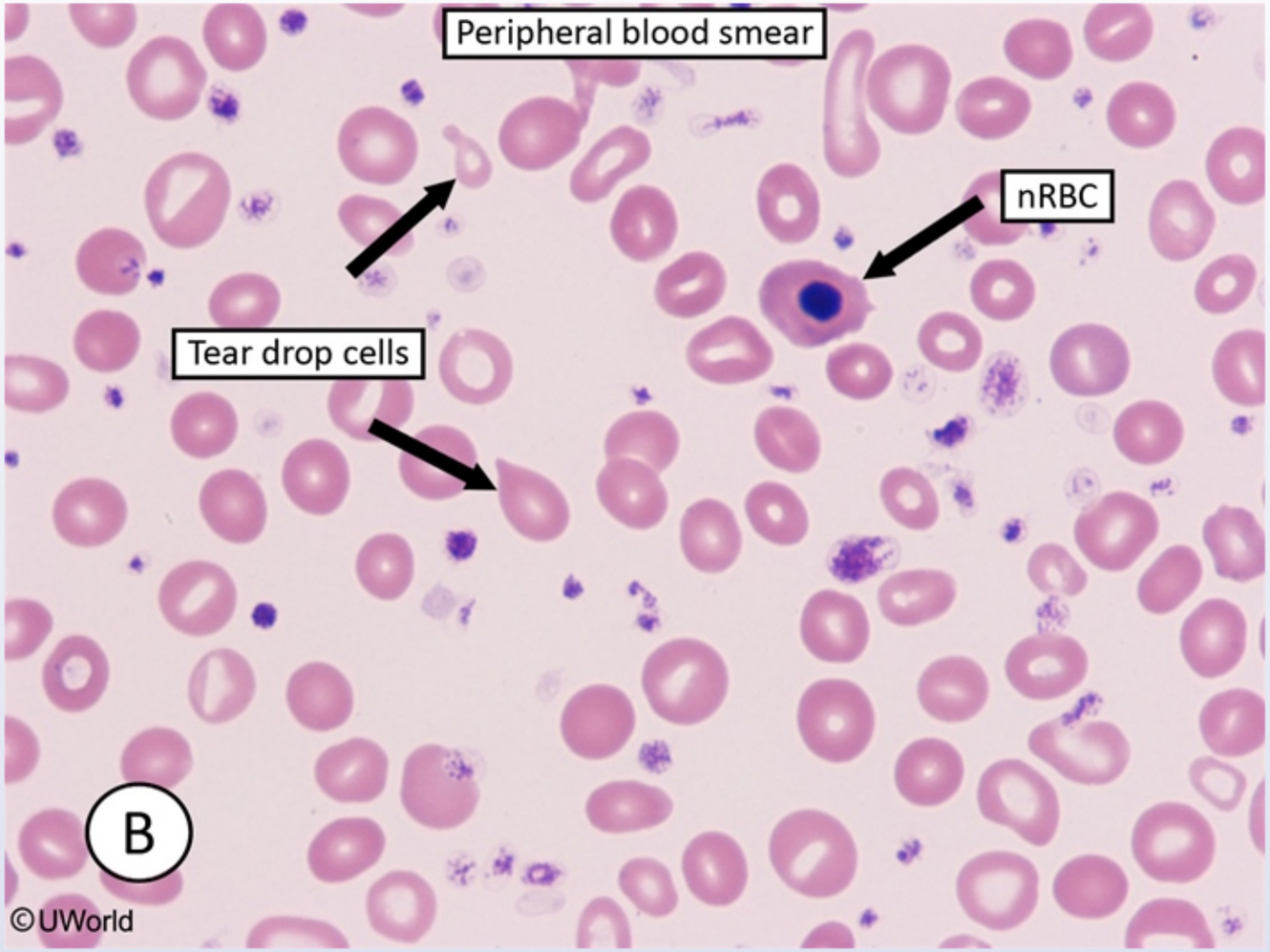

This patient with pancytopenia, hepatosplenomegaly, and teardrop cells on peripheral blood smear likely has **primary myelofibrosis**, a hematopoietic stem cell malignancy associated with the clonal expansion of **megakaryocytes**. Neoplastic megakaryocytes secrete the cytokine **transforming growth factor-beta**, which stimulates bone marrow fibroblasts to fill the medullary space with collagen. Subsequent **bone marrow fibrosis** usually leads to the following:

This patient with pancytopenia, hepatosplenomegaly, and teardrop cells on peripheral blood smear likely has **primary myelofibrosis**, a hematopoietic stem cell malignancy associated with the clonal expansion of **megakaryocytes**. Neoplastic megakaryocytes secrete the cytokine **transforming growth factor-beta**, which stimulates bone marrow fibroblasts to fill the medullary space with collagen. Subsequent **bone marrow fibrosis** usually leads to the following:

- **Extramedullary hematopoiesis** – Because the bone marrow is destroyed by fibrotic tissue, hematopoiesis occurs in secondary hematopoietic tissue such as the spleen and liver. This typically results in **marked splenomegaly** and a palpable liver edge on examination.
- **Cytopenias** – Extramedullary hematopoiesis is much less efficient than medullary hematopoiesis. Therefore, patients often have deficits in 1 (eg, anemia) or more (eg, **pancytopenia**) cell lines.
- **Dacrocytes** on peripheral blood smear – The red cell membrane is damaged when squeezing out of the fibrotic bone marrow or passing through the enlarged spleen, which leads to the formation of teardrop-shaped red cells.

The diagnosis of primary myelofibrosis requires bone marrow examination. Bone marrow aspiration frequently results in a "**dry tap**" (no marrow) due to significant bone marrow fibrosis. Therefore, bone marrow biopsy is usually required; the presence of a diffusely fibrotic marrow with occasional clusters of atypical megakaryocytes confirms the diagnosis.

(Choice B) Multiple myeloma, a clonal disorder of plasma cells, is marked by a monoclonal spike (M-spike) on protein electrophoresis. Patients typically have anemia, hypercalcemia, bone pain (osteolytic lesions), and renal insufficiency. Bone marrow biopsy usually shows a hypercellular marrow with monoclonal clusters of plasma cells.

(Choice C) Anemia of chronic disease is associated with hepcidin-induced changes in iron metabolism that cause iron trapping within macrophages. Bone marrow biopsy with Prussian blue stain demonstrates increased iron within macrophages. Hepatosplenomegaly and teardrop cells would be unexpected.

(Choice D) Myelodysplasia is a malignant stem cell cancer associated with the production of dysplastic, atypical blood cells. Although most patients with myelodysplasia have cytopenias, the bone marrow is usually hypercellular with multi-lineage dysplasia.

(Choice E) Aplastic anemia results from injury (eg, drugs, radiation, viruses) to multipotent hematologic stem cells. It is usually associated with pancytopenia and a profoundly hypocellular bone marrow that is infiltrated with adipose. However, extracellular hematopoiesis is minimal and

- **Extramedullary hematopoiesis** – Because the bone marrow is destroyed by fibrotic tissue, hematopoiesis occurs in secondary hematopoietic tissue such as the spleen and liver. This typically results in **marked splenomegaly** and a palpable liver edge on examination.
- **Cytopenias** – Extramedullary hematopoiesis is much less efficient than medullary hematopoiesis. Therefore, patients often have deficits in 1 (eg, anemia) or more (eg, **pancytopenia**) cell lines.
- **Dacrocytes** on peripheral blood smear – The red cell membrane is damaged when squeezing out of the fibrotic bone marrow or passing through the enlarged spleen, which leads to the formation of teardrop-shaped red cells.

The diagnosis of primary myelofibrosis requires bone marrow examination. Bone marrow aspiration frequently results in a "**dry tap**" (no marrow) due to significant bone marrow fibrosis. Therefore, bone marrow biopsy is usually required; the presence of a diffusely fibrotic marrow with occasional clusters of atypical megakaryocytes confirms the diagnosis.

(Choice B) Multiple myeloma, a clonal disorder of plasma cells, is marked by a monoclonal spike (M-spike) on protein electrophoresis. Patients typically have anemia, hypercalcemia, bone pain (osteolytic lesions), and renal insufficiency. Bone marrow biopsy usually shows a hypercellular marrow with monoclonal clusters of plasma cells.

(Choice C) Anemia of chronic disease is associated with hepcidin-induced changes in iron metabolism that cause iron trapping within macrophages. Bone marrow biopsy with Prussian blue stain demonstrates increased iron within macrophages. Hepatosplenomegaly and teardrop cells would be unexpected.

(Choice D) Myelodysplasia is a malignant stem cell cancer associated with the production of dysplastic, atypical blood cells. Although most patients with myelodysplasia have cytopenias, the bone marrow is usually hypercellular with multi-lineage dysplasia.

(Choice E) Aplastic anemia results from injury (eg, drugs, radiation, viruses) to multipotent hematologic stem cells. It is usually associated with pancytopenia and a profoundly hypocellular bone marrow that is infiltrated with adipose. However, extracellular hematopoiesis is minimal and hepatosplenomegaly and dacrocytes are not typically present.

Educational objective:
Primary myelofibrosis is a myeloproliferative disorder associated with the clonal expansion of megakaryocytes. Bone marrow fibrosis accounts for most of the major manifestations, including hepatosplenomegaly, cytopenias, and blood smear evidence of dacrocytes. Bone marrow aspiration is

- **Extramedullary hematopoiesis** – Because the bone marrow is destroyed by fibrotic tissue, hematopoiesis occurs in secondary

Exhibit Display

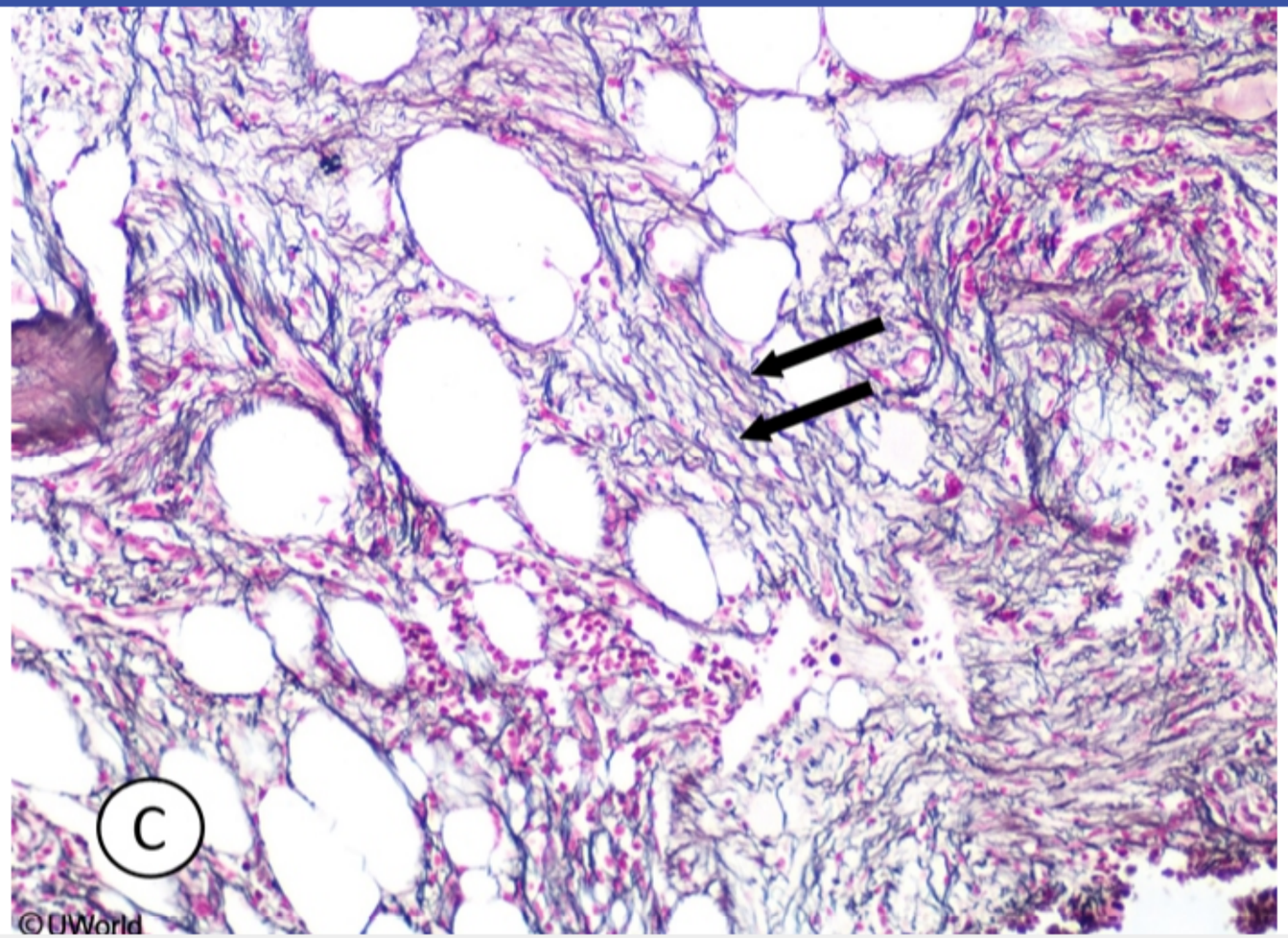

Zoom In | Zoom Out | Reset | Add To New Card | Existing Card

- **Extramedullary hematopoiesis** – Because the bone marrow is destroyed by fibrotic tissue, hematopoiesis occurs in secondary

Exhibit Display

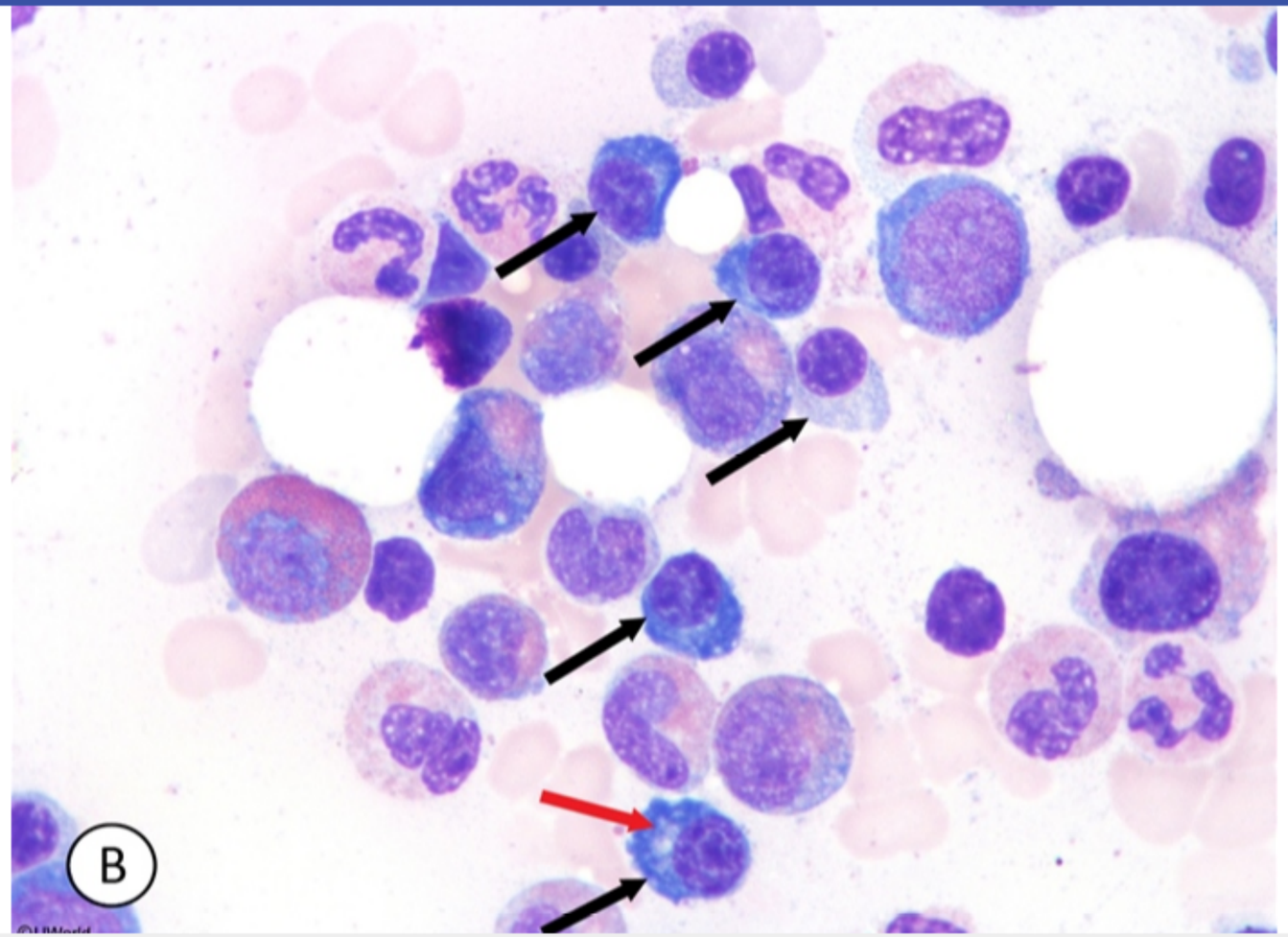

Zoom In | Zoom Out | Reset | Add To New Card | Existing Card

- **Extramedullary hematopoiesis** – Because the bone marrow is destroyed by fibrotic tissue, hematopoiesis occurs in secondary

Exhibit Display

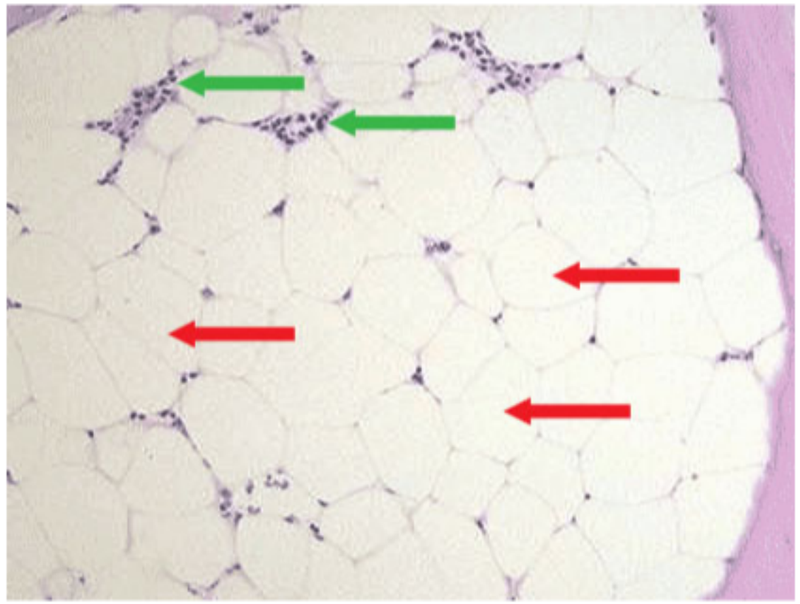

Zoom In | Zoom Out | Reset | Add To New Card | Existing Card

through the enlarged spleen, which leads to the formation of teardrop-shaped red cells.

The diagnosis of primary myelofibrosis requires bone marrow examination. Bone marrow aspiration frequently results in a "**dry tap**" (no marrow) due to significant bone marrow fibrosis. Therefore, bone marrow biopsy is usually required; the presence of a diffusely fibrotic marrow with occasional clusters of atypical megakaryocytes confirms the diagnosis.

(Choice B) Multiple myeloma, a clonal disorder of plasma cells, is marked by a monoclonal spike (M-spike) on protein electrophoresis. Patients typically have anemia, hypercalcemia, bone pain (osteolytic lesions), and renal insufficiency. Bone marrow biopsy usually shows a hypercellular marrow with monoclonal clusters of plasma cells.

(Choice C) Anemia of chronic disease is associated with hepcidin-induced changes in iron metabolism that cause iron trapping within macrophages. Bone marrow biopsy with Prussian blue stain demonstrates increased iron within macrophages. Hepatosplenomegaly and teardrop cells would be unexpected.

(Choice D) Myelodysplasia is a malignant stem cell cancer associated with the production of dysplastic, atypical blood cells. Although most patients with myelodysplasia have cytopenias, the bone marrow is usually hypercellular with multi-lineage dysplasia.

(Choice E) Aplastic anemia results from injury (eg, drugs, radiation, viruses) to multipotent hematologic stem cells. It is usually associated with pancytopenia and a profoundly hypocellular bone marrow that is infiltrated with adipose. However, extracellular hematopoiesis is minimal and hepatosplenomegaly and dacrocytes are not typically present.

Educational objective:
Primary myelofibrosis is a myeloproliferative disorder associated with the clonal expansion of megakaryocytes. Bone marrow fibrosis accounts for most of the major manifestations, including hepatosplenomegaly, cytopenias, and blood smear evidence of dacrocytes. Bone marrow aspiration is usually dry, but bone marrow biopsy will show marked fibrosis with occasional clusters of atypical megakaryocytes.

Pathology	Hematology & Oncology	Myelofibrosis
Subject	System	Topic

Copyright © UWorld. All rights reserved.

1
2
3
4
5
6
7
8
9
10
11
12
13
14
15
16
17
18
19
20
21
22
23
24
25
26
27
28
29
30

A 42-year-old Caucasian male undergoes lymph node biopsy for persistent cervical lymphadenopathy. Histologic examination reveals a population of small lymphocytes arranged in a follicular pattern. The lymphocytes also demonstrate overexpression of the *bcl-2* gene, which normally inhibits which of the following?

A. Cytoplasmic receptor activation

B. Ras-induced signal transmission

C. Nuclear transcription

D. DNA mismatch accumulation

E. Cell death cascade

Submit

A 42-year-old Caucasian male undergoes lymph node biopsy for persistent cervical lymphadenopathy. Histologic examination reveals a population of small lymphocytes arranged in a follicular pattern. The lymphocytes also demonstrate overexpression of the *bcl-2* gene, which normally inhibits which of the following?

A. Cytoplasmic receptor activation (3%)

B. Ras-induced signal transmission (8%)

C. Nuclear transcription (10%)

D. DNA mismatch accumulation (3%)

✓ E. Cell death cascade (74%)

Omitted
Correct answer
E

74%
Answered correctly

01 sec
Time Spent

02/03/2020
Last Updated

Explanation

As a B-cell neoplasm, follicular lymphoma contains tumor cells that express pan B-cell antigens (CD19, CD20, and CD79a), CD21, and CD10. The characteristic cytogenetic abnormality associated with follicular lymphoma is a translocation of the *bcl-2* oncogene from chromosome 18 to the Ig heavy chain locus on chromosome 14 [t(14;18)]. Juxtaposition of the *bcl-2* gene with the Ig heavy chain region results in overexpression of the Bcl-2 protein product. Bcl-2 protein inhibits apoptosis of tumor cells, thereby facilitating neoplastic growth.

(Choices A and C) The *bcl-2* gene does not affect cytoplasmic receptor activation or nuclear transcription.

Correct answer
E

74%
Answered correctly

01 sec
Time Spent

02/03/2020
Last Updated

Explanation

As a B-cell neoplasm, follicular lymphoma contains tumor cells that express pan B-cell antigens (CD19, CD20, and CD79a), CD21, and CD10. The characteristic cytogenetic abnormality associated with follicular lymphoma is a translocation of the *bcl-2* oncogene from chromosome 18 to the Ig heavy chain locus on chromosome 14 [t(14;18)]. Juxtaposition of the *bcl-2* gene with the Ig heavy chain region results in overexpression of the Bcl-2 protein product. Bcl-2 protein inhibits apoptosis of tumor cells, thereby facilitating neoplastic growth.

(Choices A and C) The *bcl-2* gene does not affect cytoplasmic receptor activation or nuclear transcription.

(Choice B) Ras protein is a component of the MAP-kinase pathway, a signaling system that transmits stimuli from the cell surface receptor to the nucleus. Ras overexpression renders cells more sensitive to mitogenic stimuli. This mutation occurs in pancreatic, gallbladder, colon, endometrial, thyroid, and lung cancers.

(Choice D) Mutations of genes responsible for DNA mismatch repair lead to hereditary nonpolyposis colon cancer (Lynch syndrome). This condition is characterized by a familial predisposition to colon cancer and other visceral malignancies.

Educational Objective:
Overexpression of *bcl-2* leads to increased secretion of Bcl-2 protein, which inhibits apoptosis and promotes survival of tumor cells. This overexpression occurs in follicular lymphoma secondary to translocation of the *bcl-2* oncogene from chromosome 18 to the Ig heavy chain locus on chromosome 14 [t(14;18)].

Pathology	Hematology & Oncology	Nonhodgkin lymphoma
Subject	System	Topic

Copyright © UWorld. All rights reserved.

1
2
3
4
5
6
7
8
9
10
11
12
13
14
15
16
17
18
19
20
21
22
23
24
25
26
27
28
29
30

A 23-year-old man comes to the office due to a rapidly enlarging left jaw mass that has developed over the past several weeks. The patient is a political refugee from East Africa. He has no known medical problems and takes no medications. Temperature is 37.1 C (98.8 F). Physical examination shows a large left-sided tumor on his jaw with surrounding lymphadenopathy but no erythema or warmth. The rest of the examination is unremarkable. HIV testing is negative. The lesion is biopsied, and numerous mitotic figures and apoptotic bodies are observed on histopathologic examination. Which of the following genetic features is most likely to be present in this tissue?

A. BCL2 overexpression

B. *BCR-ABL* rearrangement

C. c-*Myc* oncogene overexpression

D. n-*Myc* oncogene overexpression

E. Tyrosine kinase activation

Submit

A 23-year-old man comes to the office due to a rapidly enlarging left jaw mass that has developed over the past several weeks. The patient is a political refugee from East Africa. He has no known medical problems and takes no medications. Temperature is 37.1 C (98.8 F). Physical examination shows a large left-sided tumor on his jaw with surrounding lymphadenopathy but no erythema or warmth. The rest of the examination is unremarkable. HIV testing is negative. The lesion is biopsied, and numerous mitotic figures and apoptotic bodies are observed on histopathologic examination. Which of the following genetic features is most likely to be present in this tissue?

- A. BCL2 overexpression (7%)
- B. *BCR-ABL* rearrangement (3%)
- ✓ C. c-*Myc* oncogene overexpression (85%)
- D. n-*Myc* oncogene overexpression (1%)
- E. Tyrosine kinase activation (1%)

Omitted
Correct answer
C

85%
Answered correctly

02 secs
Time Spent

05/09/2020
Last Updated

Explanation

This patient has the typical presentation of endemic (African-type) **Burkitt lymphoma**, of which jaw involvement is a characteristic feature. Almost all cases of endemic Burkitt lymphoma are associated with Epstein-Barr virus (EBV) infection. EBV has been implicated in the immortalization of lymphoma cells. Histologically, Burkitt lymphoma has a "starry sky" appearance due to the presence of macrophages and apoptotic bodies in a sea of medium-sized lymphocytes.

1
2
3
4
5
6
7
8
9
10
11
12
13
14
15
16
17
18
19
20
21
22
23
24
25
26
27
28
29
30

Explanation

This patient has the typical presentation of endemic (African-type) **Burkitt lymphoma**, of which jaw involvement is a characteristic feature. Almost all cases of endemic Burkitt lymphoma are associated with Epstein-Barr virus (EBV) infection. EBV has been implicated in the immortalization of lymphoma cells. Histologically, Burkitt lymphoma has a "starry sky" appearance due to the presence of macrophages and apoptotic bodies in a sea of medium-sized lymphocytes.

Up to 90% of Burkitt lymphoma cases are associated with translocation of the c-*Myc* gene on chromosome 8, usually onto the Ig heavy chain region of chromosome 14 **[t(8;14)]**. This translocation leads to overexpression of the **c-*Myc*** oncogene and tumor growth. Burkitt lymphoma is a high-grade lymphoma. Although it is very aggressive, the tumor responds well to short-term, intensive high-dose chemotherapy. Patients with limited disease have an excellent prognosis.

(Choice A) In follicular lymphoma, there is overexpression of the antiapoptotic BCL2 as a result of the t(14;18) translocation. Follicular lymphoma causes generalized lymphadenopathy and tends to affect the elderly. Jaw involvement would be very unusual.

(Choices B and E) The *BCR-ABL* rearrangement is found in chronic myelogenous leukemia and some forms of acute lymphoblastic leukemia. The translocation causes increased tyrosine kinase activity.

(Choice D) Overexpression of the n-*Myc* oncogene is usually seen in neuroblastoma.

Educational objective:
Histologically, Burkitt lymphoma has a "starry sky" appearance due to the presence of macrophages and apoptotic bodies in a sea of medium-sized lymphocytes. The rates of mitosis and apoptosis in the cancerous tissue are high. Almost all cases of Burkitt lymphoma are associated with translocations of the c-*Myc* gene on chromosome 8, usually onto the Ig heavy chain region of chromosome 14 [t(8;14)].

Pathology	Hematology & Oncology	Burkitt lymphoma
Subject	System	Topic

Copyright © UWorld. All rights reserved.

1
2
3
4
5
6
7
8
9
10
11
12
13
14
15
16
17
18
19
20
21
22
23
24
25
26
27
28
29
30

Exhibit Display

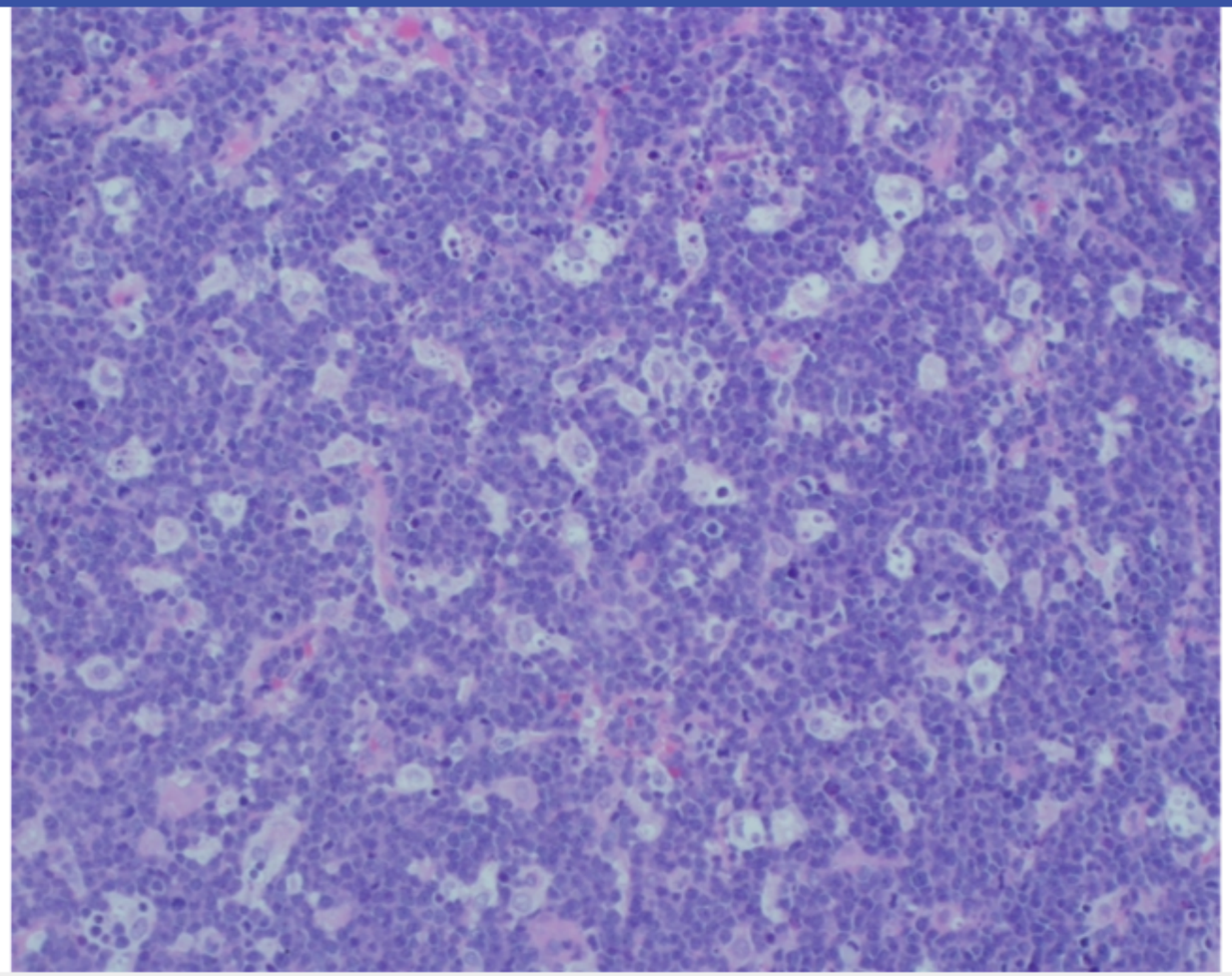

Zoom In | Zoom Out | Reset | Add To New Card | Existing Card

1
2
3
4
5
6
7
8
9
10
11
12
13
14
15
16
17
18
19
20
21
22
23
24
25
26
27
28
29
30

A 3-year-old boy diagnosed with thalassemia major receives multiple transfusions to maintain his blood hemoglobin level. On physical examination, his liver and spleen are mildly enlarged. He also has glucose intolerance as demonstrated by an oral glucose tolerance test. Which of the following therapies would prevent congestive cardiac failure in this patient?

A. Erythropoietin
B. Cobalamin
C. Deferoxamine
D. Ascorbic acid
E. Digoxin

Submit

A 3-year-old boy diagnosed with thalassemia major receives multiple transfusions to maintain his blood hemoglobin level. On physical examination, his liver and spleen are mildly enlarged. He also has glucose intolerance as demonstrated by an oral glucose tolerance test. Which of the following therapies would prevent congestive cardiac failure in this patient?

- A. Erythropoietin (5%)
- B. Cobalamin (2%)
- ✓ C. Deferoxamine (82%)
- D. Ascorbic acid (2%)
- E. Digoxin (6%)

Omitted
Correct answer
C

82%
Answered correctly

02 secs
Time Spent

03/28/2020
Last Updated

Explanation

Many hemolytic diseases (eg, thalassemia major) require frequent, regular treatment with red blood cell transfusions for the maintenance of an adequate hemoglobin level. Over time, these **chronic red blood cell transfusions** cause **iron** to accumulate within the reticuloendothelial system and organs such as the liver and heart. Because iron **cardiotoxicity** may result in arrhythmias and congestive heart failure, it is important to implement chelation therapy within one to two years of beginning red blood cell transfusions.

Chelation therapy allows for the removal of excessive iron from the body, and can delay or prevent the development of cardiac disease. **Deferoxamine** is one of the more effective and safe iron chelators, as it complexes with ferric ions to form ferrioxamine, which is removed by the

C

Answered correctly

Time Spent

Last Updated

Explanation

Many hemolytic diseases (eg, thalassemia major) require frequent, regular treatment with red blood cell transfusions for the maintenance of an adequate hemoglobin level. Over time, these **chronic red blood cell transfusions** cause **iron** to accumulate within the reticuloendothelial system and organs such as the liver and heart. Because iron **cardiotoxicity** may result in arrhythmias and congestive heart failure, it is important to implement chelation therapy within one to two years of beginning red blood cell transfusions.

Chelation therapy allows for the removal of excessive iron from the body, and can delay or prevent the development of cardiac disease. **Deferoxamine** is one of the more effective and safe iron chelators, as it complexes with ferric ions to form ferrioxamine, which is removed by the kidneys.

(Choices A, B, D, and E) Erythropoietin induces erythropoiesis and reticulocyte release from the bone marrow. It is commonly used to treat the anemia of chronic kidney disease. Cobalamin (vitamin B_{12}) is necessary in the treatment of pernicious anemia. Ascorbic acid (vitamin C) is used in the treatment of scurvy. Digoxin causes increased cardiac contractility, enhanced vagal tone, and decreased ventricular rate. As such, it is used in the treatment of congestive heart failure and supraventricular arrhythmias.

None of these therapies are capable of preventing congestive heart failure secondary to iron cardiotoxicity, however.

Educational objective:
Chelation therapy with deferoxamine should be implemented in patients receiving chronic red blood cell transfusions. Deferoxamine prevents iron-induced cardiotoxicity and congestive heart failure from developing in this patient population.

Pathology	Hematology & Oncology	Iron poisoning
Subject	System	Topic

Copyright © UWorld. All rights reserved.

A 53-year-old man comes to the physician due to frequent headaches and dizziness. He has a history of hypertension and peptic ulcer disease. His medications include daily chlorthalidone and antacids as needed. The patient's temperature is 37 C (98.6 F), blood pressure is 146/92 mm Hg, pulse is 89/min, and respirations are 16/min. His BMI is 26 kg/m^2. Physical examination shows facial plethora and moderate splenomegaly. Laboratory results are as follows:

Complete blood count	
Hemoglobin	21.5 g/dL
Hematocrit	64%
Erythrocytes	7.6 million/mm^3
Mean corpuscular volume	90 μm^3
Mean corpuscular hemoglobin	31 pg/cell
Mean corpuscular hemoglobin concentration	33% Hb/cell
Red blood cell distribution width	14.0% (n = 10.3%-14.1%)
Platelets	545,000/mm^3
Leukocytes	15,500/mm^3

This patient most likely has a mutation in which of the following types of proteins?

A. Cytoplasmic tyrosine kinase
B. Growth-stimulating transcription factor
C. Intrinsic receptor tyrosine kinase

Hemoglobin	21.5 g/dL
Hematocrit	64%
Erythrocytes	7.6 million/mm^3
Mean corpuscular volume	90 μm^3
Mean corpuscular hemoglobin	31 pg/cell
Mean corpuscular hemoglobin concentration	33% Hb/cell
Red blood cell distribution width	14.0% (n = 10.3%-14.1%)
Platelets	545,000/mm^3
Leukocytes	15,500/mm^3

This patient most likely has a mutation in which of the following types of proteins?

A. Cytoplasmic tyrosine kinase
B. Growth-stimulating transcription factor
C. Intrinsic receptor tyrosine kinase
D. Tumor suppressor protein
E. Vascular growth factor

Submit

1
2
3
4
5
6
7
8
9
10
11
12
13
14
15
16
17
18
19
20
21
22
23
24
25
26
27
28
29
30

Hemoglobin	21.5 g/dL
Hematocrit	64%
Erythrocytes	7.6 million/mm^3
Mean corpuscular volume	90 μm^3
Mean corpuscular hemoglobin	31 pg/cell
Mean corpuscular hemoglobin concentration	33% Hb/cell
Red blood cell distribution width	14.0% (n = 10.3%-14.1%)
Platelets	545,000/mm^3
Leukocytes	15,500/mm^3

This patient most likely has a mutation in which of the following types of proteins?

- ✓ A. Cytoplasmic tyrosine kinase (33%)
- B. Growth-stimulating transcription factor (25%)
- C. Intrinsic receptor tyrosine kinase (28%)
- D. Tumor suppressor protein (5%)
- E. Vascular growth factor (6%)

Omitted
Correct answer

33%
Answered correctly

03 secs
Time Spent

01/14/2020
Last Updated

1
2
3
4
5
6
7
8
9
10
11
12
13
14
15
16
17
18
19
20
21
22
23
24
25
26
27
28
29
30

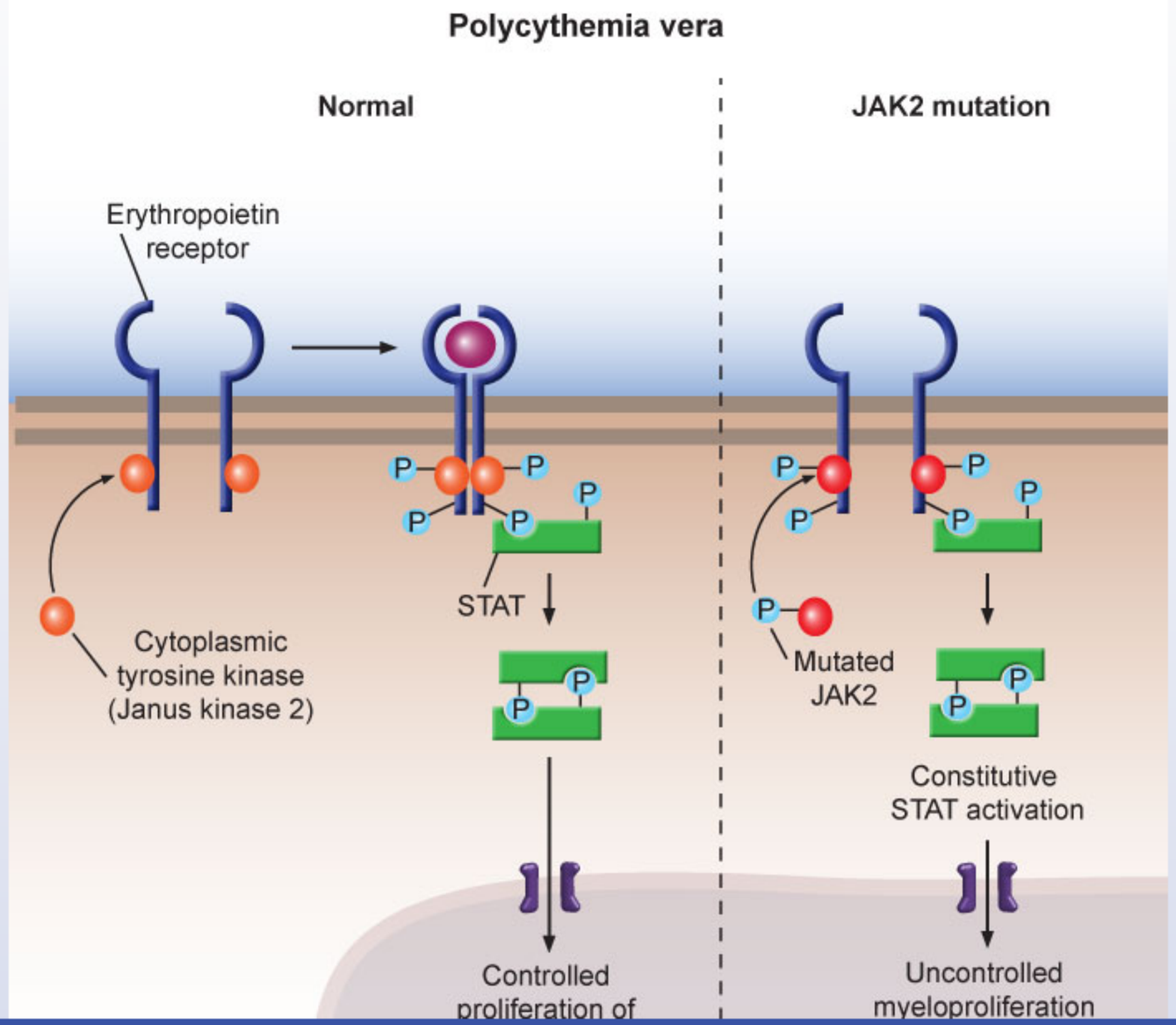

1
2
3
4
5
6
7
8
9
10
11
12
13
14
15
16
17
18
19
20
21
22
23
24
25
26
27
28
29
30

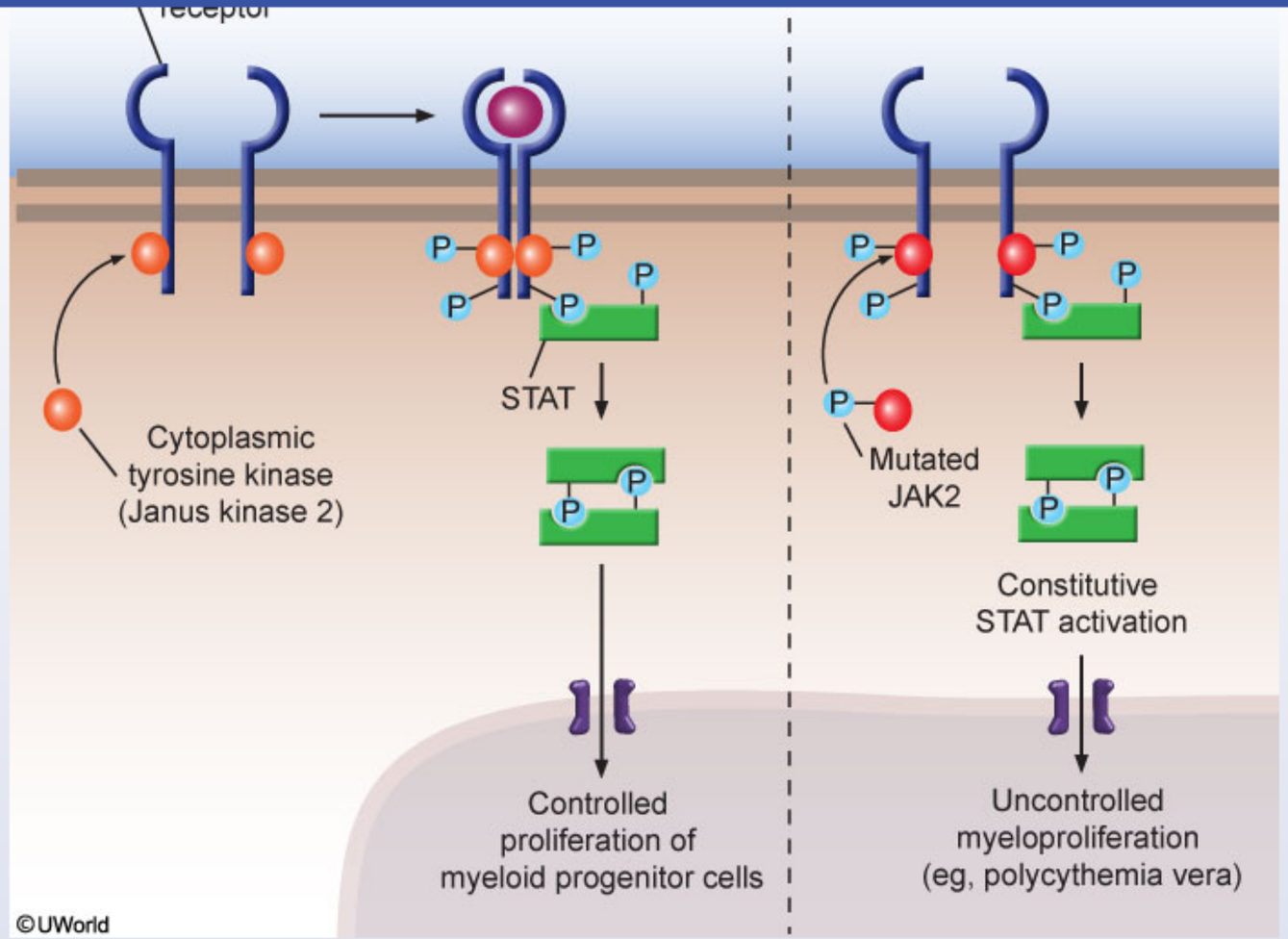

This patient most likely has **polycythemia vera**, a myeloproliferative disorder characterized by uncontrolled erythrocyte production. Patients frequently present with nonspecific symptoms (eg, headache, weakness, diaphoresis), **aquagenic pruritus**, **facial plethora** (reddish complexion), and **splenomegaly**. Associated conditions include peptic ulcer disease (altered mucosal blood flow due to increased viscosity) and gouty arthritis (higher red cell turnover). Laboratory studies show **increased erythrocyte mass**, thrombocytosis, leukocytosis, and low erythropoietin levels. Erythrocyte indices are usually normal.

1 2 3 4 5 6 7 8 9 10 11 12 13 14 15 16 17 18 19 20 21 22 23 24 25 26 27 28 29 30

This patient most likely has **polycythemia vera**, a myeloproliferative disorder characterized by uncontrolled erythrocyte production. Patients frequently present with nonspecific symptoms (eg, headache, weakness, diaphoresis), **aquagenic pruritus**, **facial plethora** (reddish complexion), and **splenomegaly**. Associated conditions include peptic ulcer disease (altered mucosal blood flow due to increased viscosity) and gouty arthritis (higher red cell turnover). Laboratory studies show **increased erythrocyte mass**, thrombocytosis, leukocytosis, and low erythropoietin levels. Erythrocyte indices are usually normal.

Polycythemia vera is caused by abnormal transduction of erythropoietin growth signals. The erythropoietin receptor has no intrinsic kinase activity and must interact with **Janus kinase 2** (JAK2), a **cytoplasmic (non-receptor) tyrosine kinase**, to initiate downstream signaling. Virtually all patients with polycythemia vera have a mutation in JAK2 that causes constitutive activation of its kinase domain, resulting in clonal proliferation of myeloid cells. JAK2 mutations have also been implicated in essential thrombocythemia, primary myelofibrosis, and other myeloproliferative disorders.

(Choice B) Burkitt lymphoma is characterized by translocation of the c-*myc* oncogene on chromosome 8 to the Ig heavy chain region on chromosome 14. This results in constitutive expression of c-Myc, a growth-stimulating transcription factor.

(Choice C) Intrinsic receptor tyrosine kinases are receptors with intrinsic kinase activity that autophosphorylate and induce a downstream signaling cascade upon ligand binding. Examples include the receptors for insulin, insulin-like growth factor, and epidermal growth factor. Mutations causing excessive epidermal growth factor receptor activity occur in many solid tumors.

(Choice D) Mutations of the p53 tumor suppressor are associated with Li-Fraumeni syndrome, an autosomal dominant disorder with predisposition to a variety of cancers, particularly sarcomas and tumors of the breast, brain, and adrenal cortex.

(Choice E) Expression of vascular endothelial growth factor (VEGF) is required for tumor angiogenesis, a critical step in the process of tumor growth and metastasis. VEGF upregulation occurs in the vast majority of cancers.

Educational objective:
Polycythemia vera is a myeloproliferative disorder characterized by uncontrolled erythrocyte production. Virtually all patients with polycythemia vera have a mutation in JAK2, a non-receptor (cytoplasmic) tyrosine kinase associated with the erythropoietin receptor.

References

- JAK2 exon 12 mutations in polycythemia vera and idiopathic erythrocytosis.

This patient most likely has **polycythemia vera**, a myeloproliferative disorder characterized by uncontrolled erythrocyte production. Patients

Exhibit Display

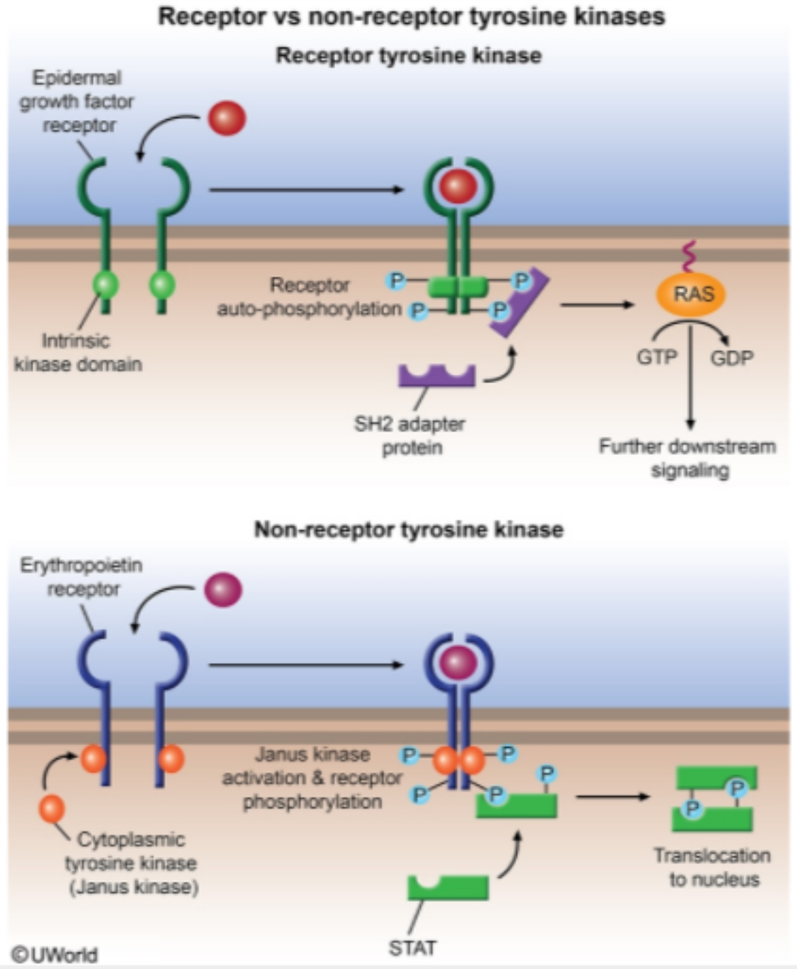

Zoom In Zoom Out Reset Add To New Card | Existing Card

- JAK2 exon 12 mutations in polycythemia vera and idiopathic erythrocytosis.

1
2
3
4
5
6
7
8
9
10
11
12
13
14
15
16
17
18
19
20
21
22
23
24
25
26
27
28
29
30

Hypophosphorylated retinoblastoma protein is most likely to perform which of the following functions?

A. Induction of apoptosis

B. Prevention of the G1/S cell cycle transition

C. Activation of receptor tyrosine kinase

D. Opposition of p53 activity

E. Repair of damaged DNA

Submit

1
2
3
4
5
6
7
8
9
10
11
12
13
14
15
16
17
18
19
20
21
22
23
24
25
26
27
28
29
30

Hypophosphorylated retinoblastoma protein is most likely to perform which of the following functions?

A. Induction of apoptosis (6%)

✓ B. Prevention of the G1/S cell cycle transition (70%)

C. Activation of receptor tyrosine kinase (6%)

D. Opposition of p53 activity (13%)

E. Repair of damaged DNA (3%)

Omitted
Correct answer
B

70%
Answered correctly

01 sec
Time Spent

02/03/2020
Last Updated

Explanation

The cell cycle is defined as the sequence of events that separates one cell division from the next. It consists of an inactive phase, interphase, and mitosis.

1. Gap phase 0 (G0 phase) is the stage in which the cell cycle is suspended. The cells are resting and do not divide.
2. Interphase comprises 90% of the cell cycle and is the stage in which the cell prepares for division. Interphase is subdivided into the G1 phase (ie, synthesis of RNA, protein, lipid, and carbohydrate), S phase (ie, DNA replication), and the G2 phase (ie, ATP synthesis).
3. Mitosis (M) is the stage in which the cell divides into two daughter cells.

At both the G1 to S phase transition and the G2 to M phase transition, the cell cycle can be stopped. These stages are called "checkpoints" and

1 2 3 4 5 6 7 8 9 10 11 12 13 14 15 16 17 18 19 20 21 22 23 24 25 26 27 28 29 30

The cell cycle is defined as the sequence of events that separates one cell division from the next. It consists of an inactive phase, interphase, and mitosis.

1. Gap phase 0 (G0 phase) is the stage in which the cell cycle is suspended. The cells are resting and do not divide.
2. Interphase comprises 90% of the cell cycle and is the stage in which the cell prepares for division. Interphase is subdivided into the G1 phase (ie, synthesis of RNA, protein, lipid, and carbohydrate), S phase (ie, DNA replication), and the G2 phase (ie, ATP synthesis).
3. Mitosis (M) is the stage in which the cell divides into two daughter cells.

At both the G1 to S phase transition and the G2 to M phase transition, the cell cycle can be stopped. These stages are called "checkpoints" and are regulated by cyclins and cyclin-dependent kinases that screen for DNA damage or abnormalities. Cells with normal DNA are allowed to proceed through the checkpoint, while cells with damaged DNA trigger DNA repair mechanisms. If the DNA damage is too substantial to be repaired, the cell undergoes apoptosis.

The Rb (retinoblastoma) tumor suppressor gene located on chromosome 13q14 encodes a nuclear phosphoprotein that regulates the G1→S checkpoint. Rb protein can be in an active (hypophosphorylated) state or an inactive (hyperphosphorylated) state. The inactivated Rb protein allows the cell to proceed through the G1→S checkpoint. The activated Rb protein, in contrast, stops the cell cycle. Abnormal phosphorylation of Rb protein results in its inactivation, thereby allowing cells with damaged DNA to proceed through the G1→S checkpoint and then divide. Mutations of the Rb protein have been linked to retinoblastoma, osteosarcoma, breast adenocarcinoma, small cell carcinoma of the lung, and bladder carcinoma.

(Choice A) The main inducer of apoptosis is the p53 protein, also described as the "molecular policeman."

(Choice C) The Rb protein does not activate receptor tyrosine kinase.

(Choice D) The Rb protein does not oppose p53 activity.

(Choice E) *BRCA1* and *BRCA2* are two of many DNA repair genes that have been identified. When mutated, these genes are associated with an increased risk of breast and ovarian cancer.

Educational Objective:
The Rb tumor suppressor gene encodes the Rb protein, which regulates the cell cycle. Active (hypophosphorylated) Rb protein prevents damaged cells from proceeding past the G1 to S checkpoint, while the inactive (hyperphosphorylated) Rb protein allows the damaged cell to enter

At both the G1 to S phase transition and the G2 to M phase transition, the cell cycle can be stopped. These stages are called "checkpoints" and are regulated by cyclins and cyclin-dependent kinases that screen for DNA damage or abnormalities. Cells with normal DNA are allowed to proceed through the checkpoint, while cells with damaged DNA trigger DNA repair mechanisms. If the DNA damage is too substantial to be repaired, the cell undergoes apoptosis.

The Rb (retinoblastoma) tumor suppressor gene located on chromosome 13q14 encodes a nuclear phosphoprotein that regulates the G1→S checkpoint. Rb protein can be in an active (hypophosphorylated) state or an inactive (hyperphosphorylated) state. The inactivated Rb protein allows the cell to proceed through the G1→S checkpoint. The activated Rb protein, in contrast, stops the cell cycle. Abnormal phosphorylation of Rb protein results in its inactivation, thereby allowing cells with damaged DNA to proceed through the G1→S checkpoint and then divide. Mutations of the Rb protein have been linked to retinoblastoma, osteosarcoma, breast adenocarcinoma, small cell carcinoma of the lung, and bladder carcinoma.

(Choice A) The main inducer of apoptosis is the p53 protein, also described as the "molecular policeman."

(Choice C) The Rb protein does not activate receptor tyrosine kinase.

(Choice D) The Rb protein does not oppose p53 activity.

(Choice E) *BRCA1* and *BRCA2* are two of many DNA repair genes that have been identified. When mutated, these genes are associated with an increased risk of breast and ovarian cancer.

Educational Objective:
The Rb tumor suppressor gene encodes the Rb protein, which regulates the cell cycle. Active (hypophosphorylated) Rb protein prevents damaged cells from proceeding past the G1 to S checkpoint, while the inactive (hyperphosphorylated) Rb protein allows the damaged cell to enter mitosis. Abnormal phosphorylation of Rb protein results in its inactivation.

Pathology	Hematology & Oncology	Cell cycle
Subject	System	Topic

Copyright © UWorld. All rights reserved.

1
2
3
4
5
6
7
8
9
10
11
12
13
14
15
16
17
18
19
20
21
22
23
24
25
26
27
28
29
30

Individuals who demonstrate increased activity of a specific intracellular enzyme are more susceptible to developing benz(o)pyrene-induced lung cancer. Which one of the following enzymes is most likely overactive in these patients?

A. Glutathione-S-transferase

B. Glucuronide transferase

C. Microsomal monooxygenase

D. Mitochondrial cytochrome oxidase

E. Superoxide dismutase

Submit

1
2
3
4
5
6
7
8
9
10
11
12
13
14
15
16
17
18
19
20
21
22
23
24
25
26
27
28
29
30

Individuals who demonstrate increased activity of a specific intracellular enzyme are more susceptible to developing benz(o)pyrene-induced lung cancer. Which one of the following enzymes is most likely overactive in these patients?

A. Glutathione-S-transferase (15%)
B. Glucuronide transferase (8%)
✓ C. Microsomal monooxygenase (23%)
D. Mitochondrial cytochrome oxidase (25%)
E. Superoxide dismutase (27%)

Omitted
Correct answer
C

23%
Answered correctly

01 sec
Time Spent

02/03/2020
Last Updated

Explanation

Many chemicals can induce cancer in humans, with most such substances existing in an inactive, pro-carcinogenic state. Pro-carcinogens are metabolized by cytochrome P450 monooxygenase, an enzyme system present in hepatic microsomes and the endoplasmic reticula of varied other tissues. Cytochrome P450 monooxygenase metabolizes steroids, alcohol, toxins, and other foreign substances by rendering them soluble and easier to excrete. Unfortunately, this metabolic processing also converts pro-carcinogens into carcinogens capable of causing mutations in human DNA.

(Choice A) Glutathione-S-transferase is involved in the detoxification of some chemical carcinogens. Unlike cytochrome P450 oxidase, this

1 2 3 4 5 6 7 8 9 10 11 12 13 14 15 16 17 18 19 20 21 22 23 24 25 26 27 28 29 30

Explanation

Many chemicals can induce cancer in humans, with most such substances existing in an inactive, pro-carcinogenic state. Pro-carcinogens are metabolized by cytochrome P450 monooxygenase, an enzyme system present in hepatic microsomes and the endoplasmic reticula of varied other tissues. Cytochrome P450 monooxygenase metabolizes steroids, alcohol, toxins, and other foreign substances by rendering them soluble and easier to excrete. Unfortunately, this metabolic processing also converts pro-carcinogens into carcinogens capable of causing mutations in human DNA.

(Choice A) Glutathione-S-transferase is involved in the detoxification of some chemical carcinogens. Unlike cytochrome P450 oxidase, this enzyme converts toxic substances into inactive metabolites.

(Choice B) Glucuronide transferase converts bilirubin into soluble bilirubin diglucuronide in the hepatocytes. This enzyme is not involved in the metabolism of chemical carcinogens.

(Choice D) Mitochondrial cytochrome oxidase (cytochrome a+a3) is a component of the electron transport chain that reacts with molecular oxygen to produce water. This enzyme is not involved in the metabolism of chemical carcinogens.

(Choice E) Superoxide dismutase converts superoxide into oxygen and hydrogen peroxide during phagocytosis. This enzyme is not involved in the metabolism of chemical carcinogens.

Educational Objective:
Most chemical carcinogens enter the body in an inactive state (ie, as pro-carcinogens). These pro-carcinogens are converted into active metabolites by the cytochrome P450 oxidase system. Individual susceptibility to chemical carcinogens depends on the activity of these P450 enzymes, which is genetically determined.

Pathology	Hematology & Oncology	Carcinogens
Subject	System	Topic

Copyright © UWorld. All rights reserved.

1
2
3
4
5
6
7
8
9
10
11
12
13
14
15
16
17
18
19
20
21
22
23
24
25
26
27
28
29
30

A 62-year-old man is evaluated for worsening cough, shortness of breath, and episodic hemoptysis over the past 6 months. The patient has also had a 15-kg (33-lb) weight loss over the same period without any change in his diet or activity level. He has a 50-pack-year smoking history and does not use alcohol or illicit drugs. BMI is 18 kg/m^2. The patient appears cachectic with temporal wasting and generalized loss of muscle mass. Chest x-ray reveals a large lung mass with mediastinal lymphadenopathy and pleural effusion. Which of the following cellular processes is most likely responsible for this patient's muscle loss?

A. Covalent attachment of ubiquitin to muscle proteins

B. Plasma membrane rupture with leakage of cellular contents

C. Plasma membrane instability due to defective dystrophin

D. Progressive shortening of chromosomal telomeres

E. Reprogramming of undifferentiated mesenchymal cells

Submit

1
2
3
4
5
6
7
8
9
10
11
12
13
14
15
16
17
18
19
20
21
22
23
24
25
26
27
28
29
30

A 62-year-old man is evaluated for worsening cough, shortness of breath, and episodic hemoptysis over the past 6 months. The patient has also had a 15-kg (33-lb) weight loss over the same period without any change in his diet or activity level. He has a 50-pack-year smoking history and does not use alcohol or illicit drugs. BMI is 18 kg/m^2. The patient appears cachectic with temporal wasting and generalized loss of muscle mass. Chest x-ray reveals a large lung mass with mediastinal lymphadenopathy and pleural effusion. Which of the following cellular processes is most likely responsible for this patient's muscle loss?

- ✓ A. Covalent attachment of ubiquitin to muscle proteins (62%)
- B. Plasma membrane rupture with leakage of cellular contents (19%)
- C. Plasma membrane instability due to defective dystrophin (2%)
- D. Progressive shortening of chromosomal telomeres (5%)
- E. Reprogramming of undifferentiated mesenchymal cells (8%)

Omitted
Correct answer
A

62%
Answered correctly

01 sec
Time Spent

02/15/2020
Last Updated

Explanation

1
2
3
4
5
6
7
8
9
10
11
12
13
14
15
16
17
18
19
20
21
22
23
24
25
26
27
28
29
30

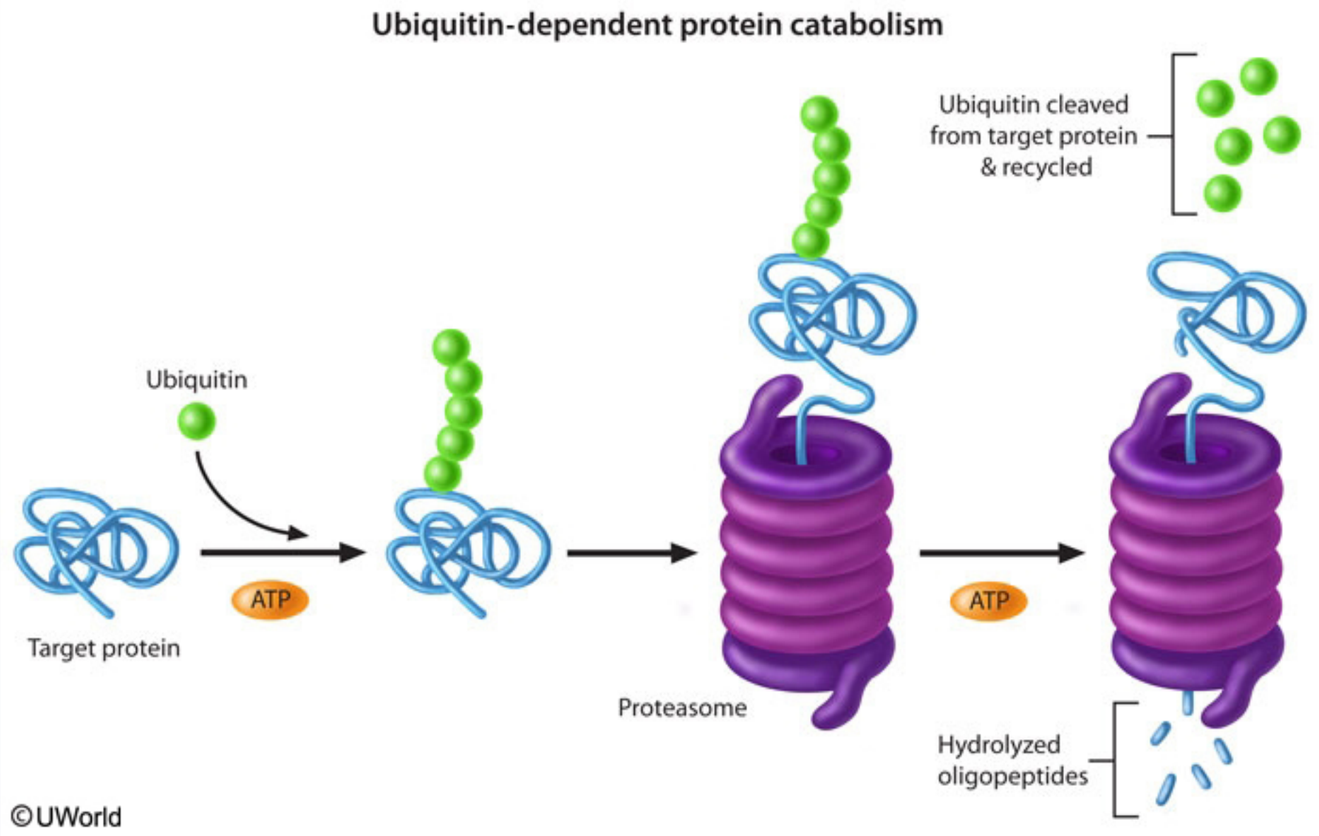

This patient who has a 50-pack-year smoking history and a mediastinal mass likely has muscle atrophy due to cancer-related **cachexia**. Cachexia is a hypermetabolic state driven by elevated pro-inflammatory cytokines (eg, tumor necrosis factor-alpha, interleukin-6), which stimulate the **ubiquitin-proteasome pathway** to degrade skeletal muscle proteins (eg, actin, myosin).

The ubiquitin-proteasome pathway is the major eukaryotic mechanism for **selective proteolysis** (the destruction of targeted proteins). The addition of ubiquitin multimers to a target protein marks it for **rapid** destruction by the proteasome, whereby the protein is unfolded within the proteasome core and chopped into small oligopeptides. These oligopeptides can be further degraded by cytosolic peptidases into individual amino acids.

1
2
3
4
5
6
7
8
9
10
11
12
13
14
15
16
17
18
19
20
21
22
23
24
25
26
27
28
29
30

This patient who has a 50-pack-year smoking history and a mediastinal mass likely has muscle atrophy due to cancer-related **cachexia**. Cachexia is a hypermetabolic state driven by elevated pro-inflammatory cytokines (eg, tumor necrosis factor-alpha, interleukin-6), which stimulate the **ubiquitin-proteasome pathway** to degrade skeletal muscle proteins (eg, actin, myosin).

The ubiquitin-proteasome pathway is the major eukaryotic mechanism for **selective proteolysis** (the destruction of targeted proteins). The addition of ubiquitin multimers to a target protein marks it for **rapid** destruction by the proteasome, whereby the protein is unfolded within the proteasome core and chopped into small oligopeptides. These oligopeptides can be further degraded by cytosolic peptidases into individual amino acids.

Other proteolytic pathways play a less prominent role in the degradation of muscle tissue. Lysosomes, membrane-bound organelles that contain proteases and other digestive enzymes, are primarily tasked with breaking down extracellular components that are brought into the cell via endocytosis and with slowly recycling obsolete cytosolic organelles and debris.

(Choice B) Necrosis is characterized by cellular injury and premature death due to external factors such as infection, toxin, or trauma. It is often characterized by irreparable damage to the cellular membrane with subsequent leakage of cellular contents.

(Choice C) Both Duchenne and Becker muscular dystrophies are caused by X-linked mutations to the dystrophin gene. Dystrophin provides mechanical stability to muscle cells during contraction. Mutations are associated with membrane tears that allow calcium to enter the cell and cause myofiber damage.

(Choice D) Telomeres are DNA-protein structures at the end of chromosomes that shorten with each cell division. When telomeres shorten beyond a certain point, the cell undergoes apoptosis or senescence.

(Choice E) Reprogramming of undifferentiated mesenchymal cells (eg, connective tissue) is a form of metaplasia. Metaplasia is characterized by the substitution of one differentiated cell type for another differentiated cell type not normally found in that tissue (eg, bone formation in muscle tissue after muscle injury).

Educational objective:
The ubiquitin-proteasome pathway mediates targeted protein degradation, which allows for rapid disposal of unneeded intracellular proteins. In cancer-related cachexia, high levels of pro-inflammatory cytokines lead to increased ubiquitination of sarcomeric muscle proteins, which in turn

Other proteolytic pathways play a less prominent role in the degradation of muscle tissue. Lysosomes, membrane-bound organelles that contain proteases and other digestive enzymes, are primarily tasked with breaking down extracellular components that are brought into the cell via endocytosis and with slowly recycling obsolete cytosolic organelles and debris.

(Choice B) Necrosis is characterized by cellular injury and premature death due to external factors such as infection, toxin, or trauma. It is often characterized by irreparable damage to the cellular membrane with subsequent leakage of cellular contents.

(Choice C) Both Duchenne and Becker muscular dystrophies are caused by X-linked mutations to the dystrophin gene. Dystrophin provides mechanical stability to muscle cells during contraction. Mutations are associated with membrane tears that allow calcium to enter the cell and cause myofiber damage.

(Choice D) Telomeres are DNA-protein structures at the end of chromosomes that shorten with each cell division. When telomeres shorten beyond a certain point, the cell undergoes apoptosis or senescence.

(Choice E) Reprogramming of undifferentiated mesenchymal cells (eg, connective tissue) is a form of metaplasia. Metaplasia is characterized by the substitution of one differentiated cell type for another differentiated cell type not normally found in that tissue (eg, bone formation in muscle tissue after muscle injury).

Educational objective:
The ubiquitin-proteasome pathway mediates targeted protein degradation, which allows for rapid disposal of unneeded intracellular proteins. In cancer-related cachexia, high levels of pro-inflammatory cytokines lead to increased ubiquitination of sarcomeric muscle proteins, which in turn leads to extensive skeletal muscle loss.

References

- Mechanisms of muscle wasting. The role of the ubiquitin-proteasome pathway.

Pathology	Hematology & Oncology	Cancer anorexia cachexia syndrome
Subject	System	Topic

Copyright © UWorld. All rights reserved.

1
2
3
4
5
6
7
8
9
10
11
12
13
14
15
16
17
18
19
20
21
22
23
24
25
26
27
28
29
30

Exhibit Display

Endosomal pathway

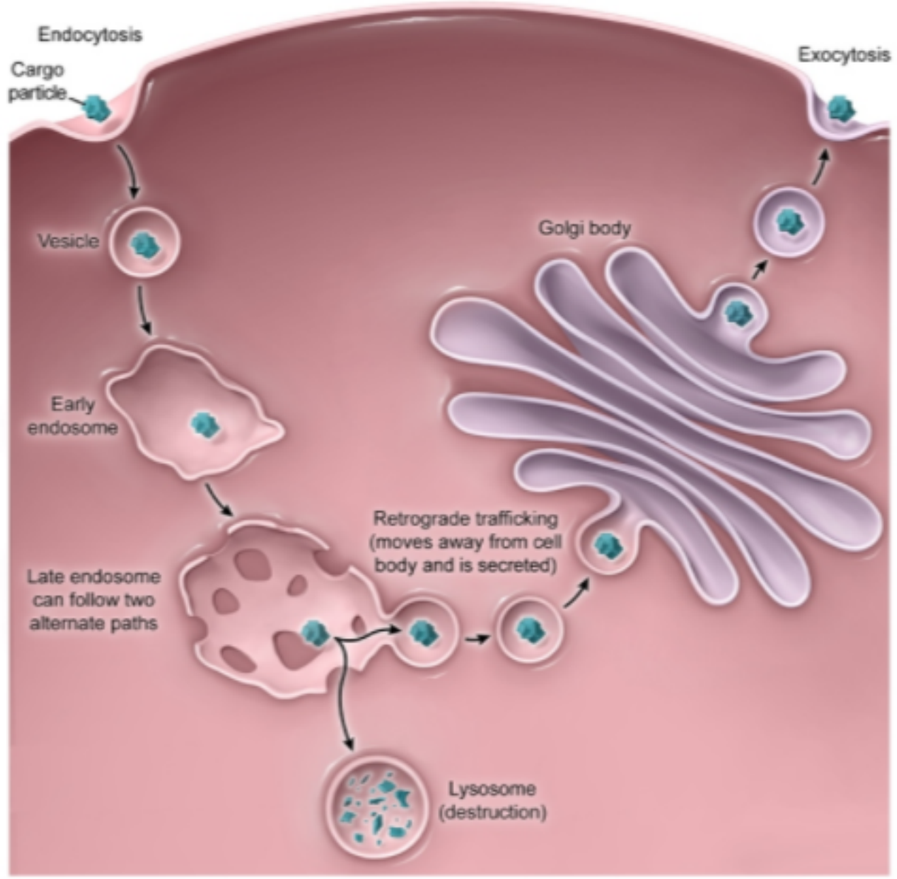

©UWorld

Zoom In | Zoom Out | Reset | Add To New Card | Existing Card

cancer-related cachexia, high levels of pro-inflammatory cytokines lead to increased ubiquitination of sarcomeric muscle proteins, which in turn

1
2
3
4
5
6
7
8
9
10
11
12
13
14
15
16
17
18
19
20
21
22
23
24
25
26
27
28
29
30

Exhibit Display

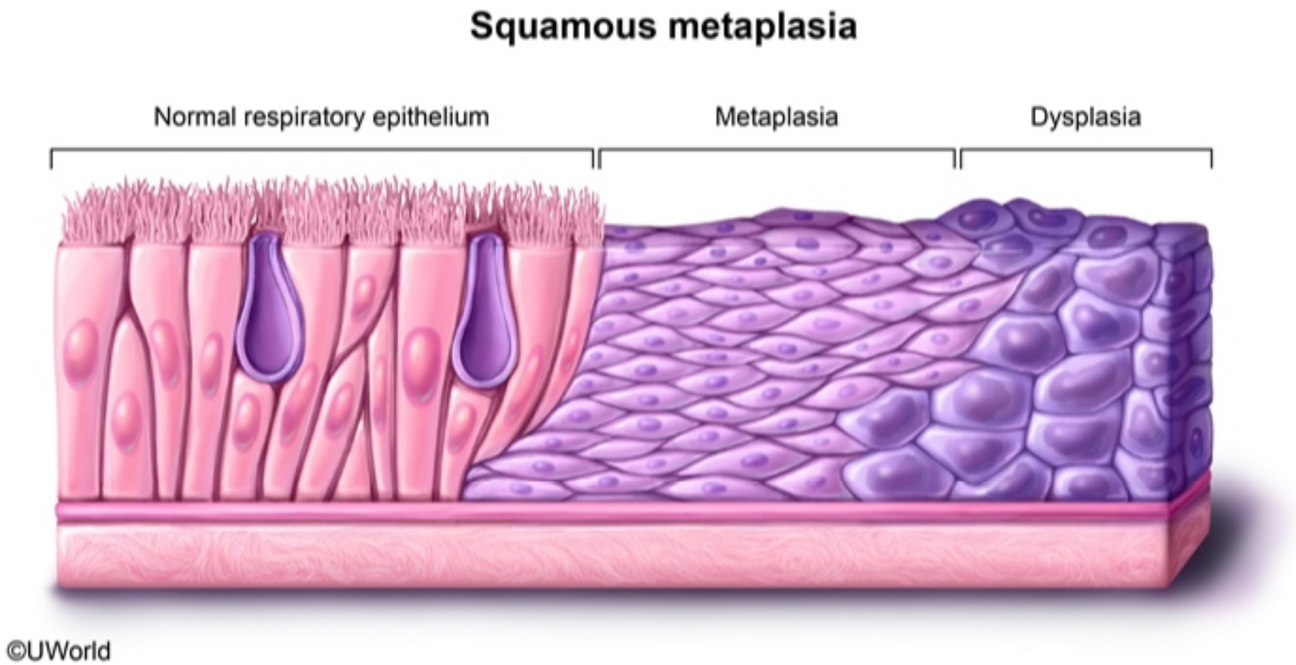

Zoom In | Zoom Out | Reset | Add To New Card | Existing Card

cancer-related cachexia, high levels of pro-inflammatory cytokines lead to increased ubiquitination of sarcomeric muscle proteins, which in turn

1
2
3
4
5
6
7
8
9
10
11
12
13
14
15
16
17
18
19
20
21
22
23
24
25
26
27
28
29
30

A 53-year-old female treated with high-dose folic acid for anemia experiences a moderate increase in her hemoglobin level. She returns to clinic complaining of bilateral foot numbness and difficulty in walking. The latter symptoms are most likely related to which of the following?

A. Folate overdose

B. Iron deficiency

C. Cobalamin deficiency

D. Hemolysis

E. Aplastic anemia

Submit

1
2
3
4
5
6
7
8
9
10
11
12
13
14
15
16
17
18
19
20
21
22
23
24
25
26
27
28
29
30

A 53-year-old female treated with high-dose folic acid for anemia experiences a moderate increase in her hemoglobin level. She returns to clinic complaining of bilateral foot numbness and difficulty in walking. The latter symptoms are most likely related to which of the following?

A. Folate overdose (4%)

B. Iron deficiency (1%)

✓ C. Cobalamin deficiency (90%)

D. Hemolysis (1%)

E. Aplastic anemia (1%)

Omitted
Correct answer
C

90%
Answered correctly

02 secs
Time Spent

02/21/2020
Last Updated

Explanation

The clinical decision to treat this patient with folic acid suggests that her anemia was megaloblastic and therefore likely secondary to a deficiency in folate and/or vitamin B_{12} (cobalamin). Her subsequent development of neurological symptoms (a finding not associated with folate deficiency alone) indicates that she is deficient in vitamin B_{12}.

A moderate improvement in the hemoglobin level often occurs when a deficiency in vitamin B_{12} is treated with folate, or vice versa. However, the treatment of vitamin B_{12} deficiency with folate will not reverse any neurologic dysfunction caused by the vitamin B_{12} deficiency. In fact, the usage of folate alone can worsen demyelination and cause abnormal myelin synthesis by depleting the concentration of unmethylated cobalamin

The clinical decision to treat this patient with folic acid suggests that her anemia was megaloblastic and therefore likely secondary to a deficiency in folate and/or vitamin B_{12} (cobalamin). Her subsequent development of neurological symptoms (a finding not associated with folate deficiency alone) indicates that she is deficient in vitamin B_{12}.

A moderate improvement in the hemoglobin level often occurs when a deficiency in vitamin B_{12} is treated with folate, or vice versa. However, the treatment of vitamin B_{12} deficiency with folate will not reverse any neurologic dysfunction caused by the vitamin B_{12} deficiency. In fact, the usage of folate alone can worsen demyelination and cause abnormal myelin synthesis by depleting the concentration of unmethylated cobalamin available for methylmalonyl-CoA processing. The walking difficulties and paresthesias seen in this patient were therefore likely precipitated by the administration of folate alone.

(Choice A) High doses of folate may antagonize phenytoin, thereby precipitating seizures in a select group of patients. Walking difficulties and paresthesias are not typically associated with folate overdose, however.

(Choice B) Iron deficiency is characterized by a hypochromic, microcytic anemia that is best treated with iron supplementation. Walking difficulties and paresthesias are not typically associated with iron deficiency anemia.

(Choices D and E) Anemia of any cause can provoke nonspecific neurologic symptoms (eg, tinnitus, irritability, generalized weakness). Walking difficulties and paresthesias are not commonly associated with hemolysis or aplastic anemia, however.

Educational Objective:
Deficiency of vitamin B_{12} is associated with both megaloblastic anemia and neurologic dysfunction, while folate deficiency is associated with megaloblastic anemia alone. Moderate improvement in the hemoglobin level often occurs when a deficiency in vitamin B_{12} is treated with folate, or vice versa. Treatment of vitamin B_{12} deficiency with folate alone can actually worsen neurologic dysfunction.

Pathology	Hematology & Oncology	Vitamin b12 deficiency
Subject	System	Topic

Copyright © UWorld. All rights reserved.

1
2
3
4
5
6
7
8
9
10
11
12
13
14
15
16
17
18
19
20
21
22
23
24
25
26
27
28
29
30

A 2-week-old girl is brought to her primary care provider for a routine visit. The patient was born by normal spontaneous vaginal delivery at 39 weeks gestation. The mother is breastfeeding exclusively, and the infant has regained her birth weight. Newborn screening results from hemoglobin electrophoresis are as follows:

Hemoglobin F	70%
Hemoglobin A	20%
Hemoglobin S	10%

The patient's mother has sickle cell trait, and a maternal cousin has sickle cell anemia. Examination shows a well-appearing infant with no pallor or splenomegaly. Which of the following is most likely true about this patient?

A. Life expectancy will be shorter than average

B. Mean corpuscular volume will be decreased

C. Reticulocyte count will be elevated

D. She has relative protection from *Plasmodium falciparum*

E. She will likely develop pain crises

Submit

A 2-week-old girl is brought to her primary care provider for a routine visit. The patient was born by normal spontaneous vaginal delivery at 39 weeks gestation. The mother is breastfeeding exclusively, and the infant has regained her birth weight. Newborn screening results from hemoglobin electrophoresis are as follows:

Hemoglobin F	70%
Hemoglobin A	20%
Hemoglobin S	10%

The patient's mother has sickle cell trait, and a maternal cousin has sickle cell anemia. Examination shows a well-appearing infant with no pallor or splenomegaly. Which of the following is most likely true about this patient?

A. Life expectancy will be shorter than average (1%)

B. Mean corpuscular volume will be decreased (2%)

C. Reticulocyte count will be elevated (5%)

✓ D. She has relative protection from *Plasmodium falciparum* (85%)

E. She will likely develop pain crises (4%)

Omitted
Correct answer
D

85%
Answered correctly

03 secs
Time Spent

03/23/2020
Last Updated

Explanation

Sickle cell trait	
Clinical features	• Usually no symptoms of sickle cell anemia • More prevalent in African, Middle-Eastern & Mediterranean countries; African American & Hispanic individuals • No change in overall life expectancy
Diagnosis	• Normal hemoglobin, reticulocyte count, RBC indices & morphology • Hemoglobin electrophoresis shows both Hb A & Hb S, with the amount of Hb A greater than Hb S

Hb A = hemoglobin A; **Hb S** = hemoglobin S; **RBC** = red blood cells.

©UWorld

This patient's hemoglobin electrophoresis from her newborn screen is most consistent with **sickle cell trait**. At birth, infants who are **heterozygous** for sickle cell trait typically have the greatest amount of fetal hemoglobin (Hb F), followed by hemoglobin A (Hb A), and the smallest amount of hemoglobin S (Hb S). Hb A continues to be higher than Hb S throughout the lifetime of these patients as Hb F naturally declines, offering protection from sickle cell anemia, aplastic crises, and splenic sequestration. Patients with sickle cell trait are usually **asymptomatic** with normal hemoglobin level, reticulocyte count, and red blood cell (RBC) indices. However, they may develop hematuria, priapism, and increased incidence of urinary tract infections. Splenic infarction at high altitudes has also been reported.

Patients with sickle cell trait have **relative protection from *Plasmodium falciparum* (malaria)**, resulting in lower rates of severe malaria and hospitalization than seen in the general population. Possible mechanisms include increased sickling of parasitized sickle cell trait RBCs and accelerated removal of these cells by the splenic monocyte-macrophage system. These patients are not immune to malaria, however, and those visiting malaria-endemic areas should still receive prophylaxis.

©UWorld

This patient's hemoglobin electrophoresis from her newborn screen is most consistent with **sickle cell trait**. At birth, infants who are **heterozygous** for sickle cell trait typically have the greatest amount of fetal hemoglobin (Hb F), followed by hemoglobin A (Hb A), and the smallest amount of hemoglobin S (Hb S). Hb A continues to be higher than Hb S throughout the lifetime of these patients as Hb F naturally declines, offering protection from sickle cell anemia, aplastic crises, and splenic sequestration. Patients with sickle cell trait are usually **asymptomatic** with normal hemoglobin level, reticulocyte count, and red blood cell (RBC) indices. However, they may develop hematuria, priapism, and increased incidence of urinary tract infections. Splenic infarction at high altitudes has also been reported.

Patients with sickle cell trait have **relative protection from *Plasmodium falciparum* (malaria)**, resulting in lower rates of severe malaria and hospitalization than seen in the general population. Possible mechanisms include increased sickling of parasitized sickle cell trait RBCs and accelerated removal of these cells by the splenic monocyte-macrophage system. These patients are not immune to malaria, however, and those visiting malaria-endemic areas should still receive prophylaxis.

(Choice A) Life expectancy of patients with sickle cell trait is no different than that of the general population. Patients who are homozygous for the sickle cell mutation have a decreased life expectancy due to significant complications of disease (eg, acute chest syndrome, infection from encapsulated organisms).

(Choices B and C) Patients with sickle cell trait typically have normal RBC indices and reticulocyte counts. Individuals with sickle cell anemia (eg, no normal Hb A) will have an elevated reticulocyte count but will maintain a normal mean corpuscular volume.

(Choice E) It is unlikely that this patient will develop painful crises as she is protected by the predominance of Hb A (normal hemoglobin) over Hb S. Vaso-occlusive pain crises that develop in patients with sickle cell anemia are thought to occur when Hb S polymerizes and causes the RBCs to assume a sickle shape, typically in response to a trigger (eg, cold weather, dehydration).

Educational objective:
Patients with sickle cell trait are typically asymptomatic and have relative protection from malaria caused by *Plasmodium falciparum*. These patients usually have normal hemoglobin, reticulocyte, and red blood cell index values. Life expectancy is the same as that of the general population.

References

- Complications associated with sickle cell trait: a brief narrative review

Patients with sickle cell trait have **relative protection from *Plasmodium falciparum* (malaria)**, resulting in lower rates of severe malaria and hospitalization than seen in the general population. Possible mechanisms include increased sickling of parasitized sickle cell trait RBCs and accelerated removal of these cells by the splenic monocyte-macrophage system. These patients are not immune to malaria, however, and those visiting malaria-endemic areas should still receive prophylaxis.

(Choice A) Life expectancy of patients with sickle cell trait is no different than that of the general population. Patients who are homozygous for the sickle cell mutation have a decreased life expectancy due to significant complications of disease (eg, acute chest syndrome, infection from encapsulated organisms).

(Choices B and C) Patients with sickle cell trait typically have normal RBC indices and reticulocyte counts. Individuals with sickle cell anemia (eg, no normal Hb A) will have an elevated reticulocyte count but will maintain a normal mean corpuscular volume.

(Choice E) It is unlikely that this patient will develop painful crises as she is protected by the predominance of Hb A (normal hemoglobin) over Hb S. Vaso-occlusive pain crises that develop in patients with sickle cell anemia are thought to occur when Hb S polymerizes and causes the RBCs to assume a sickle shape, typically in response to a trigger (eg, cold weather, dehydration).

Educational objective:
Patients with sickle cell trait are typically asymptomatic and have relative protection from malaria caused by *Plasmodium falciparum*. These patients usually have normal hemoglobin, reticulocyte, and red blood cell index values. Life expectancy is the same as that of the general population.

References

- Complications associated with sickle cell trait: a brief narrative review.
- Sickle cell trait protects against Plasmodium falciparum infection.

Pathology	Hematology & Oncology	Sickle cell
Subject	System	Topic

Copyright © UWorld. All rights reserved.

1
2
3
4
5
6
7
8
9
10
11
12
13
14
15
16
17
18
19
20
21
22
23
24
25
26
27
28
29
30

A 65-year-old man comes to the office due to 4 months of worsening fatigue. The patient feels tired with simple household chores. He has a 15-pack-year smoking history and drinks 2 or 3 beers daily. Temperature is 37 C (98.6 F), blood pressure is 134/86 mm Hg, and pulse is 76/min. Physical examination reveals a late systolic ejection murmur with a soft S2. The lungs are clear to auscultation. The abdomen is soft and nontender with no hepatosplenomegaly. There are no focal neurological deficits. Laboratory testing reveals hemoglobin is 9 g/dL and mean corpuscular volume is 93 μm^3. Peripheral blood smear is shown below:

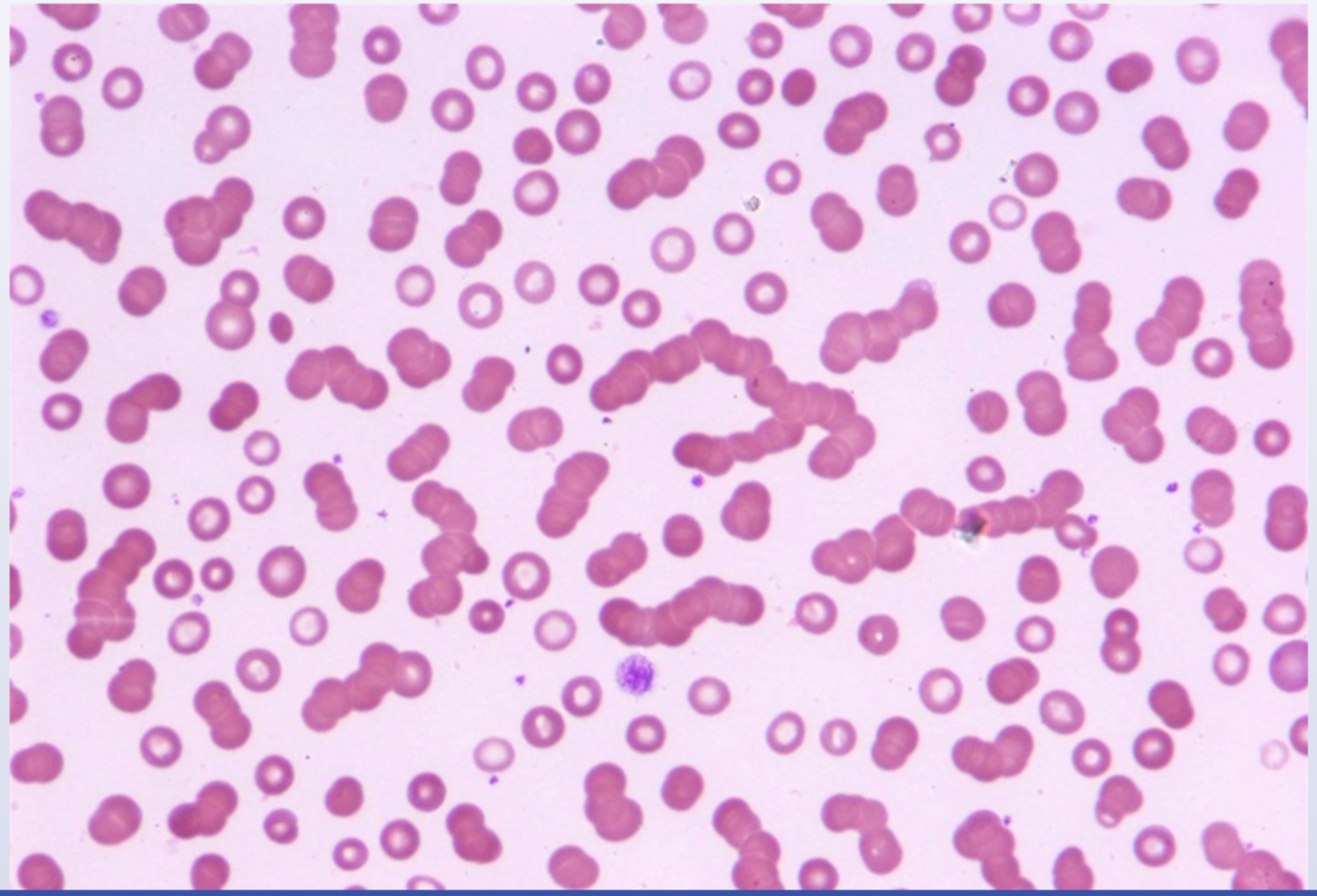

1
2
3
4
5
6
7
8
9
10
11
12
13
14
15
16
17
18
19
20
21
22
23
24
25
26
27
28
29
30

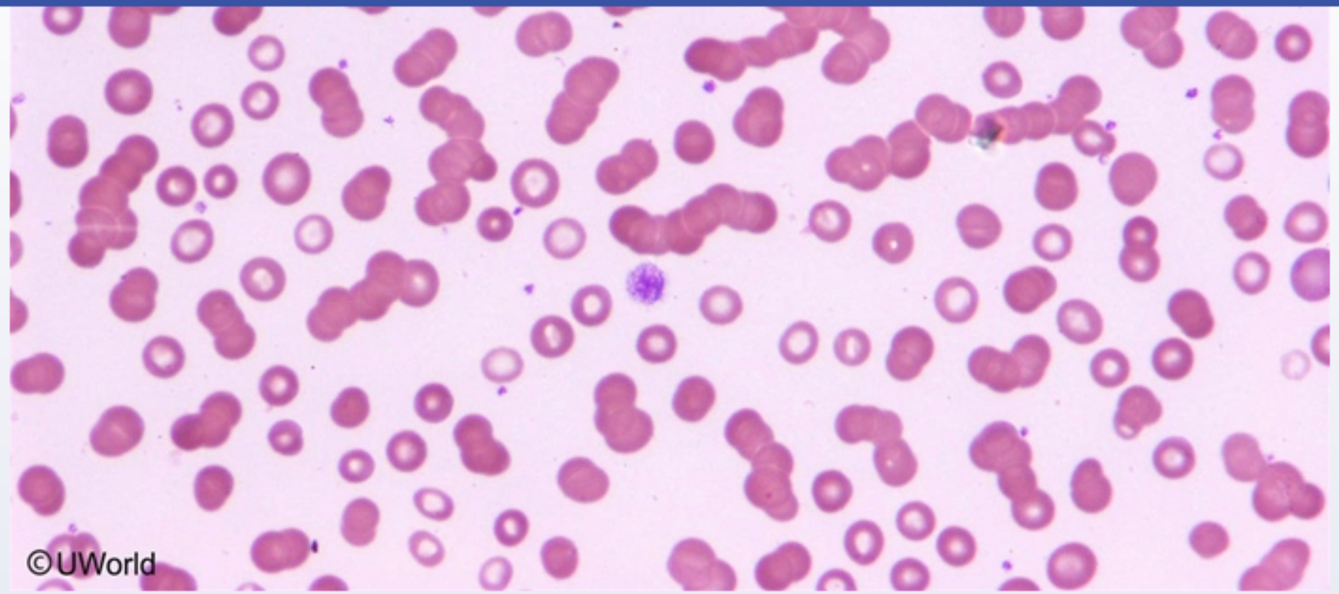

Which of the following best explains the observed erythrocyte findings in this patient?

- A. Chronic gastrointestinal blood loss
- B. Excessive cold agglutinin production
- C. Increased serum paraproteins
- D. Mechanical erythrocyte injury
- E. Nutritional vitamin B_{12} deficiency

Submit

1
2
3
4
5
6
7
8
9
10
11
12
13
14
15
16
17
18
19
20
21
22
23
24
25
26
27
28
29
30

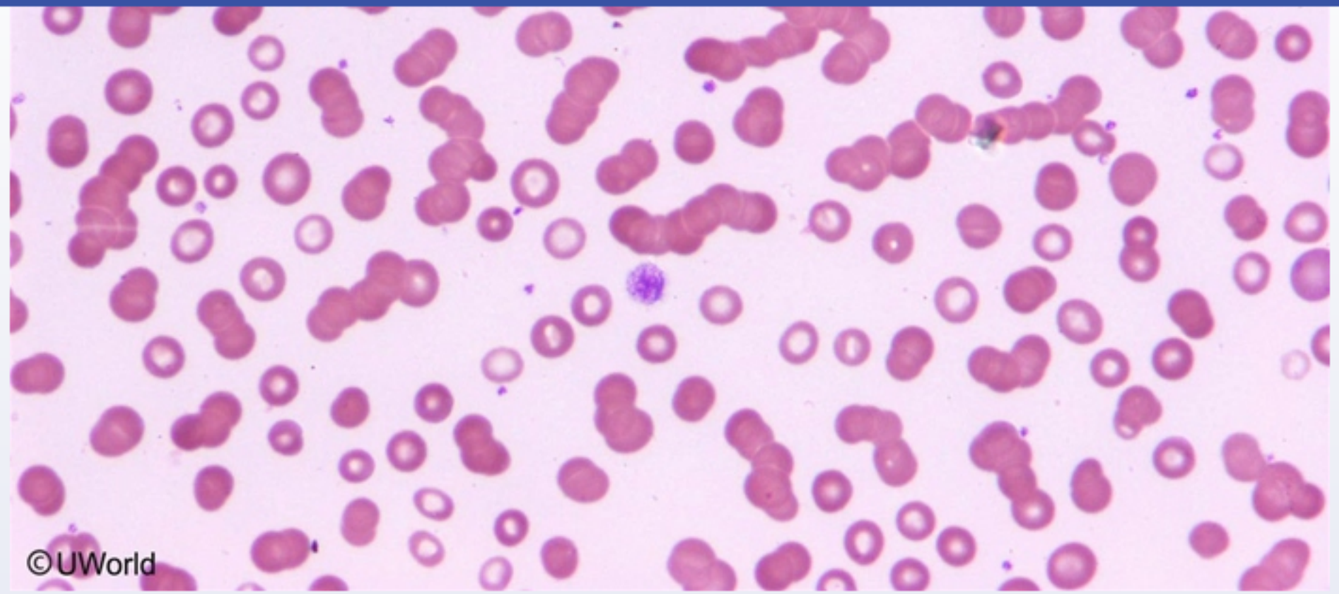

Which of the following best explains the observed erythrocyte findings in this patient?

- A. Chronic gastrointestinal blood loss (9%)
- B. Excessive cold agglutinin production (25%)
- ✓ C. Increased serum paraproteins (56%)
- D. Mechanical erythrocyte injury (5%)
- E. Nutritional vitamin B_{12} deficiency (2%)

Omitted
Correct answer

56%
Answered correctly

05 secs
Time Spent

06/03/2020
Last Updated

1
2
3
4
5
6
7
8
9
10
11
12
13
14
15
16
17
18
19
20
21
22
23
24
25
26
27
28
29
30

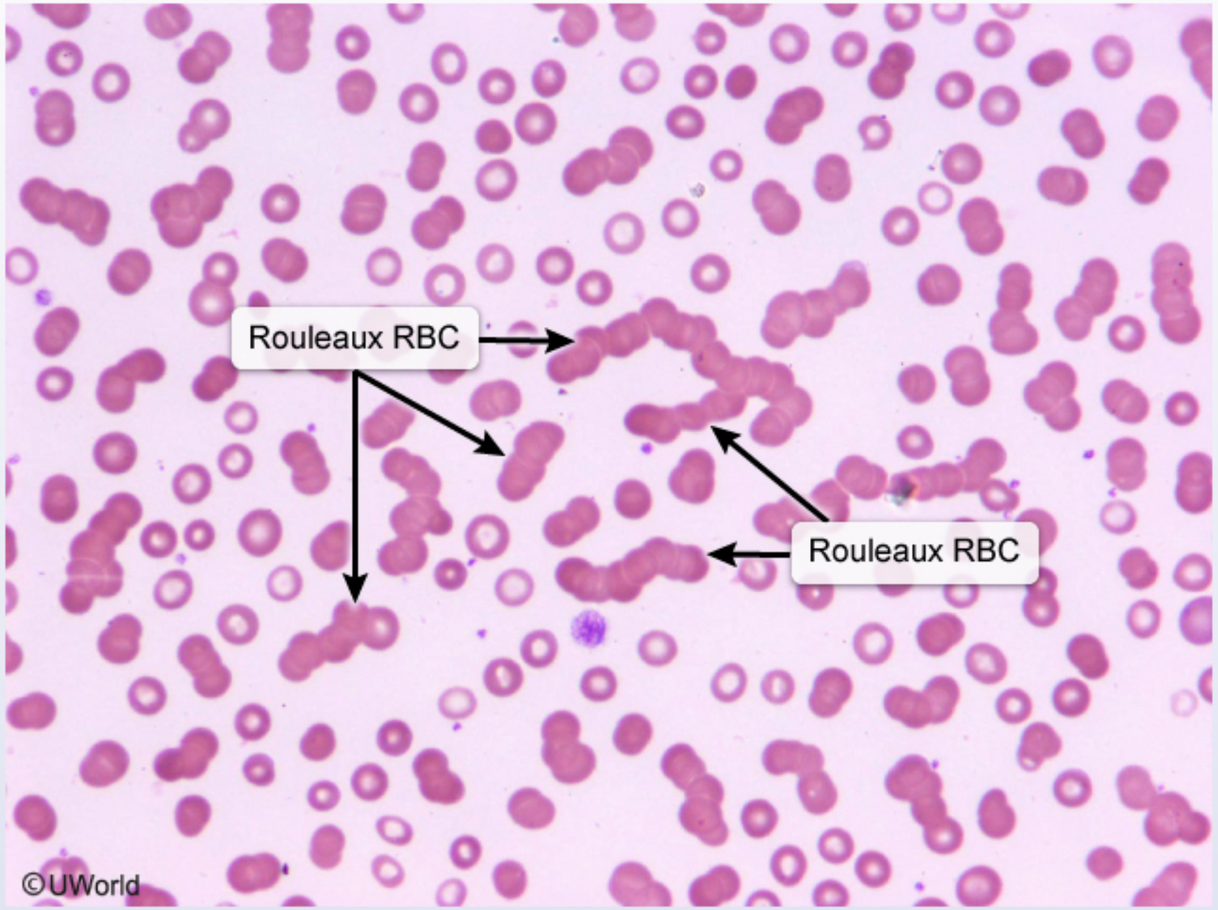

This patient's peripheral blood smear shows rows of erythrocytes stacked on one another like coins (**rouleaux formation**). This occurs due to elevated levels of **circulating proteins**, which disrupts the repulsive electrostatic charge on the erythrocyte surface and causes stacked aggregation. Although rouleaux formation can be seen with inflammatory conditions (eg, infection, rheumatic disease) that increase acute-phase reactants (eg, fibrinogen), it is classically linked to lymphoproliferative/plasma cell disorders such as **multiple myeloma** and Waldenstrom macroglobulinemia, which generate high levels of **monoclonal paraprotein** (immunoglobulins).

This patient's peripheral blood smear shows rows of erythrocytes stacked on one another like coins (**rouleaux formation**). This occurs due to elevated levels of **circulating proteins**, which disrupts the repulsive electrostatic charge on the erythrocyte surface and causes stacked aggregation. Although rouleaux formation can be seen with inflammatory conditions (eg, infection, rheumatic disease) that increase acute-phase reactants (eg, fibrinogen), it is classically linked to lymphoproliferative/plasma cell disorders such as **multiple myeloma** and Waldenstrom macroglobulinemia, which generate high levels of **monoclonal paraprotein** (immunoglobulins).

Multiple myeloma is a plasma cell malignancy often associated with **normocytic anemia**, osteolytic bone lesions, and hypercalcemia due to proliferation of neoplastic cells in the bone marrow. Patients also frequently have renal insufficiency (due to immunoglobulin light-chain cast nephropathy) and nonspecific symptoms (eg, fatigue). Elevated circulating levels of monoclonal immunoglobulin cause rouleaux formation in >50% of cases. Diagnosis is generally made using serum/urine protein electrophoresis (monoclonal M-spike) and bone marrow biopsy.

(Choice A) Chronic gastrointestinal blood loss is a leading cause of iron-deficiency anemia, which usually results in microcytosis and hypochromia on peripheral smear (sometimes with target cells). Rouleaux formation is not a typical feature, and normocytic anemia is uncommon.

(Choice B) Cold agglutinins are cross-reactive IgM antibodies that form with some infections (particularly *Mycoplasma pneumoniae*) and hematologic malignancies. Cold agglutinins typically cause clumping agglutination (not stacked-coin agglutination) and intravascular hemolysis.

(Choice D) Mechanical erythrocyte injury is common in patients with damaged or artificial heart valves. Although this patient has a cardiac murmur that indicates possible aortic stenosis, mechanical erythrocyte injury is usually associated with schistocytes on peripheral blood smear, not rouleaux formation.

(Choice E) Vitamin B_{12} deficiency causes abnormal hematologic cell nuclear maturation, which leads to macrocytic anemia and hypersegmented neutrophils on peripheral blood smear.

Educational objective:
Multiple myeloma is associated with elevated circulating paraproteins (monoclonal immunoglobulins), which causes erythrocytes to stack like coins (rouleaux formation). Patients classically have normocytic anemia, hypercalcemia, bone pain, and renal insufficiency.

Pathology	Hematology & Oncology	Multiple myeloma
Subject	System	Topic

1
2
3
4
5
6
7
8
9
10
11
12
13
14
15
16
17
18
19
20
21
22
23
24
25
26
27
28
29
30

Exhibit Display

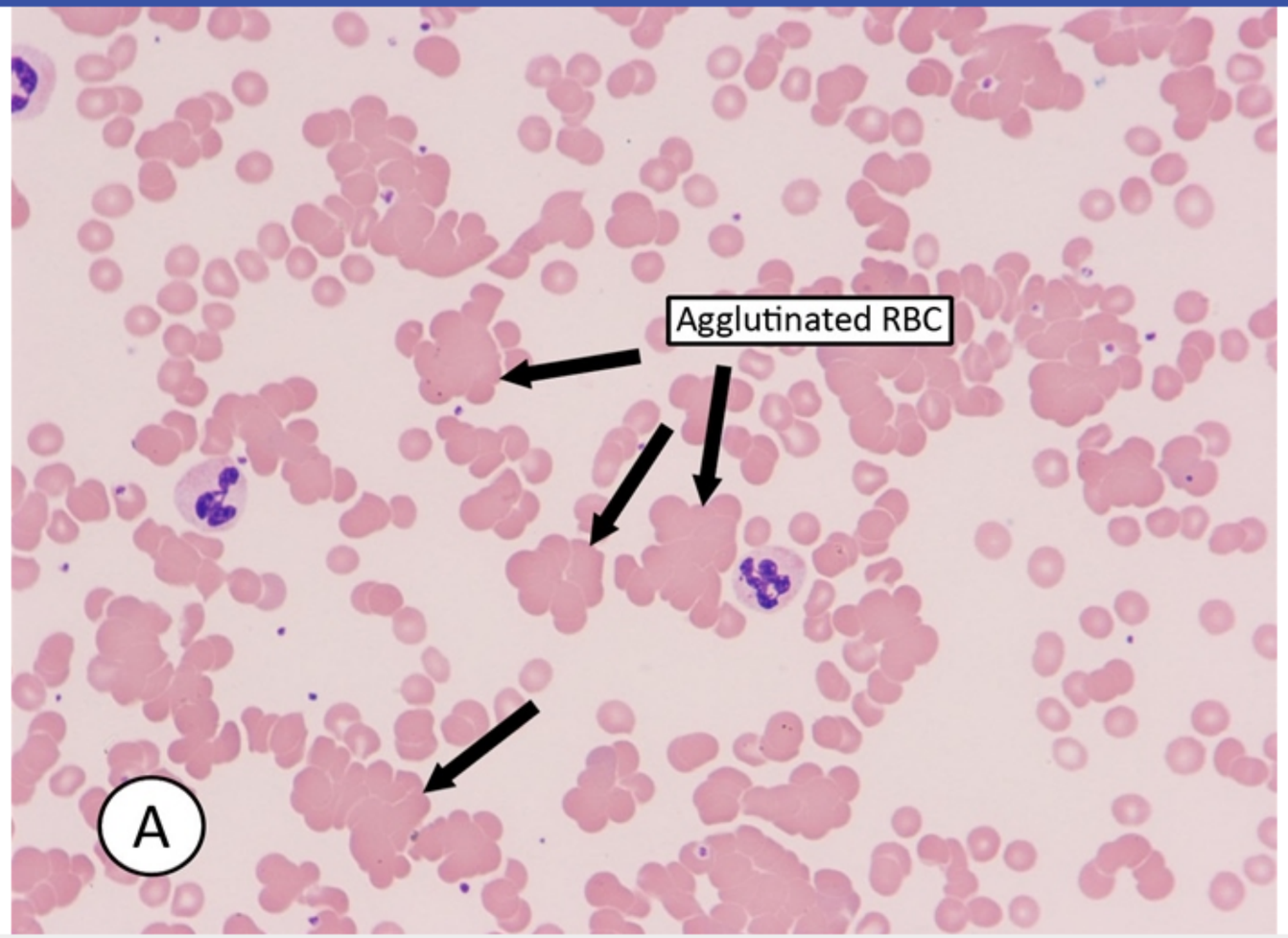

Zoom In | Zoom Out | Reset | Add To New Card | Existing Card

1
2
3
4
5
6
7
8
9
10
11
12
13
14
15
16
17
18
19
20
21
22
23
24
25
26
27
28
29
30

Exhibit Display

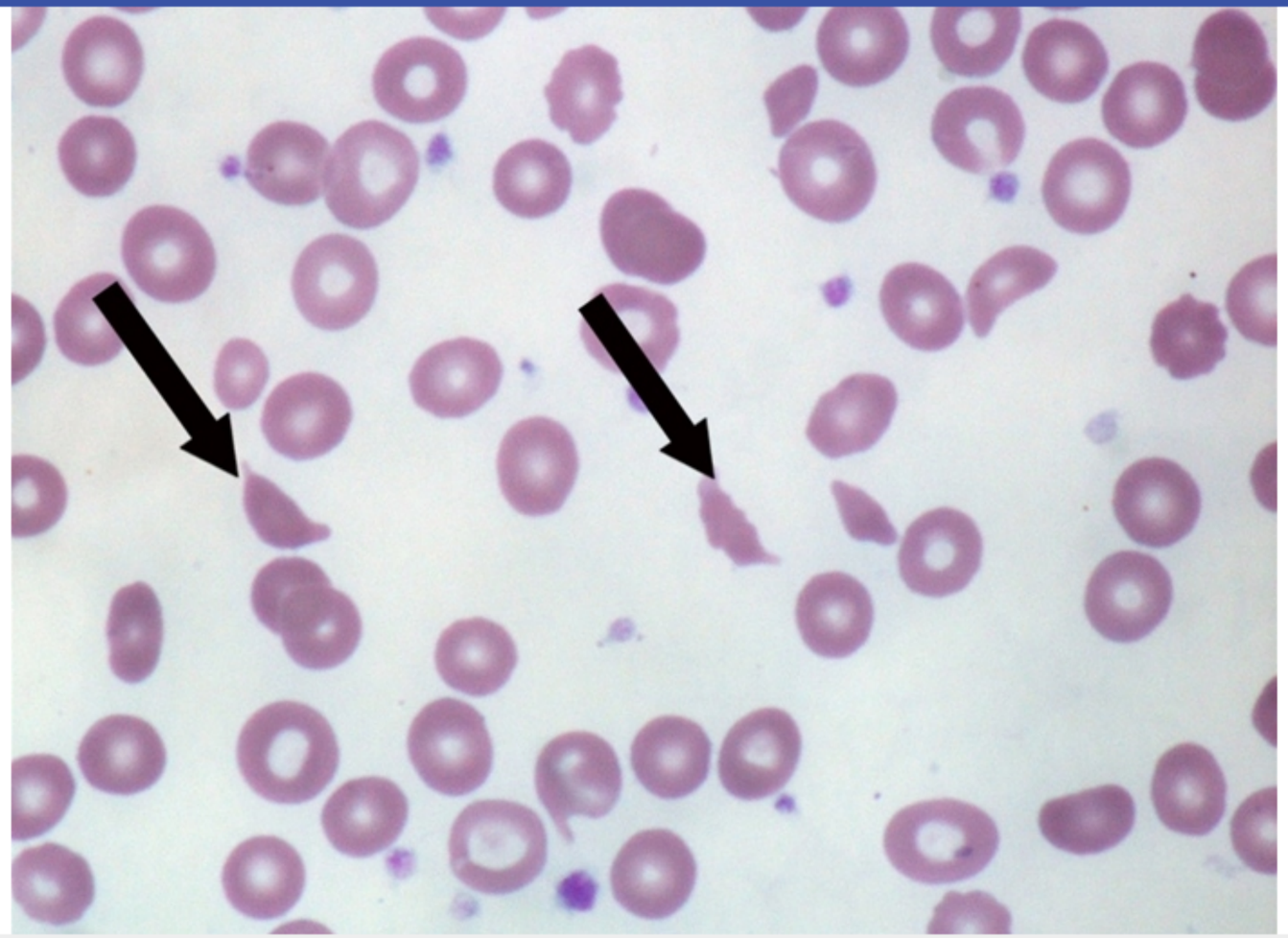

Zoom In | Zoom Out | Reset | Add To New Card | Existing Card

1
2
3
4
5
6
7
8
9
10
11
12
13
14
15
16
17
18
19
20
21
22
23
24
25
26
27
28
29
30

Exhibit Display

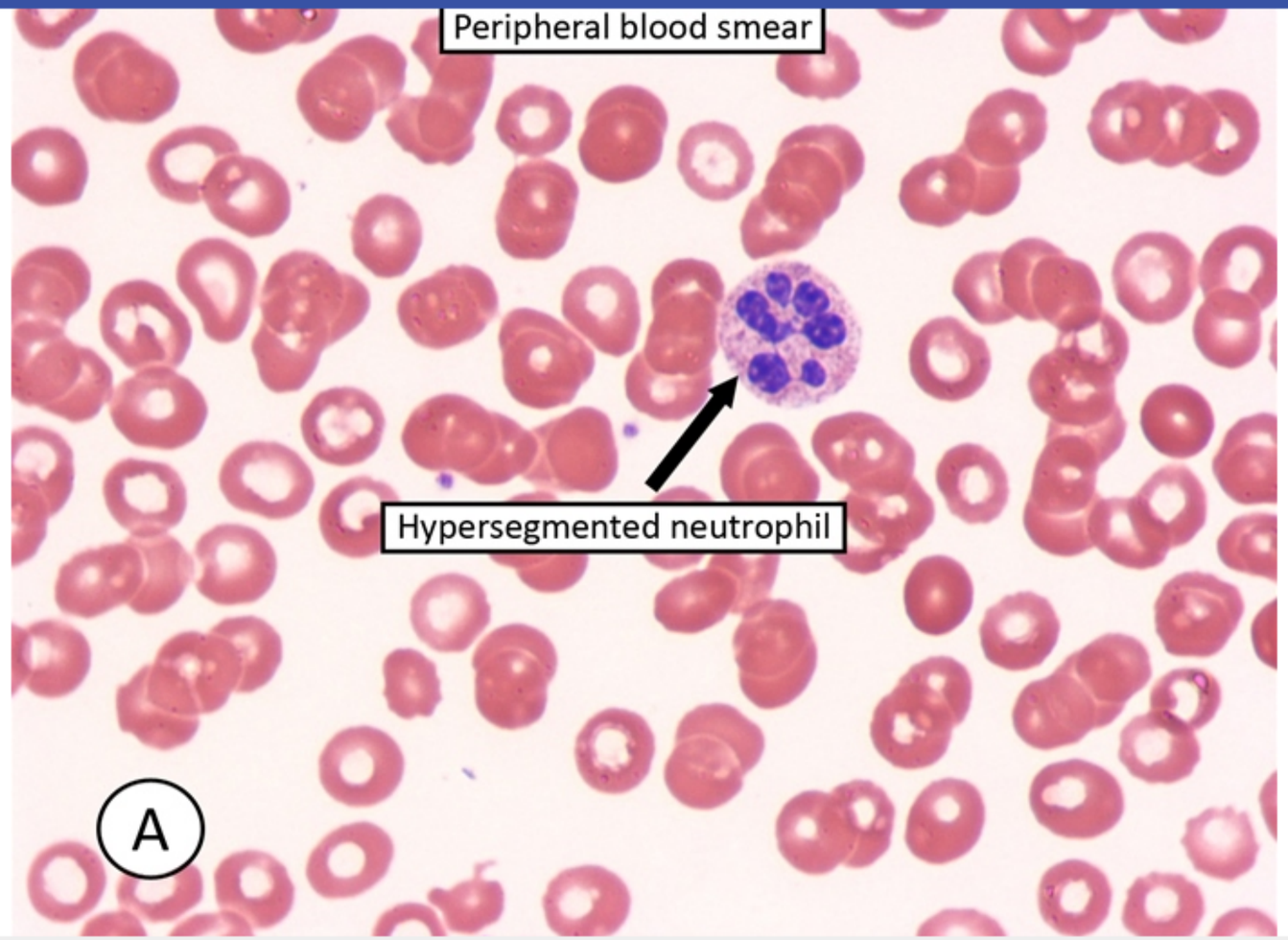

Zoom In | Zoom Out | Reset | Add To New Card | Existing Card

1
2
3
4
5
6
7
8
9
10
11
12
13
14
15
16
17
18
19
20
21
22
23
24
25
26
27
28
29
30

Exhibit Display

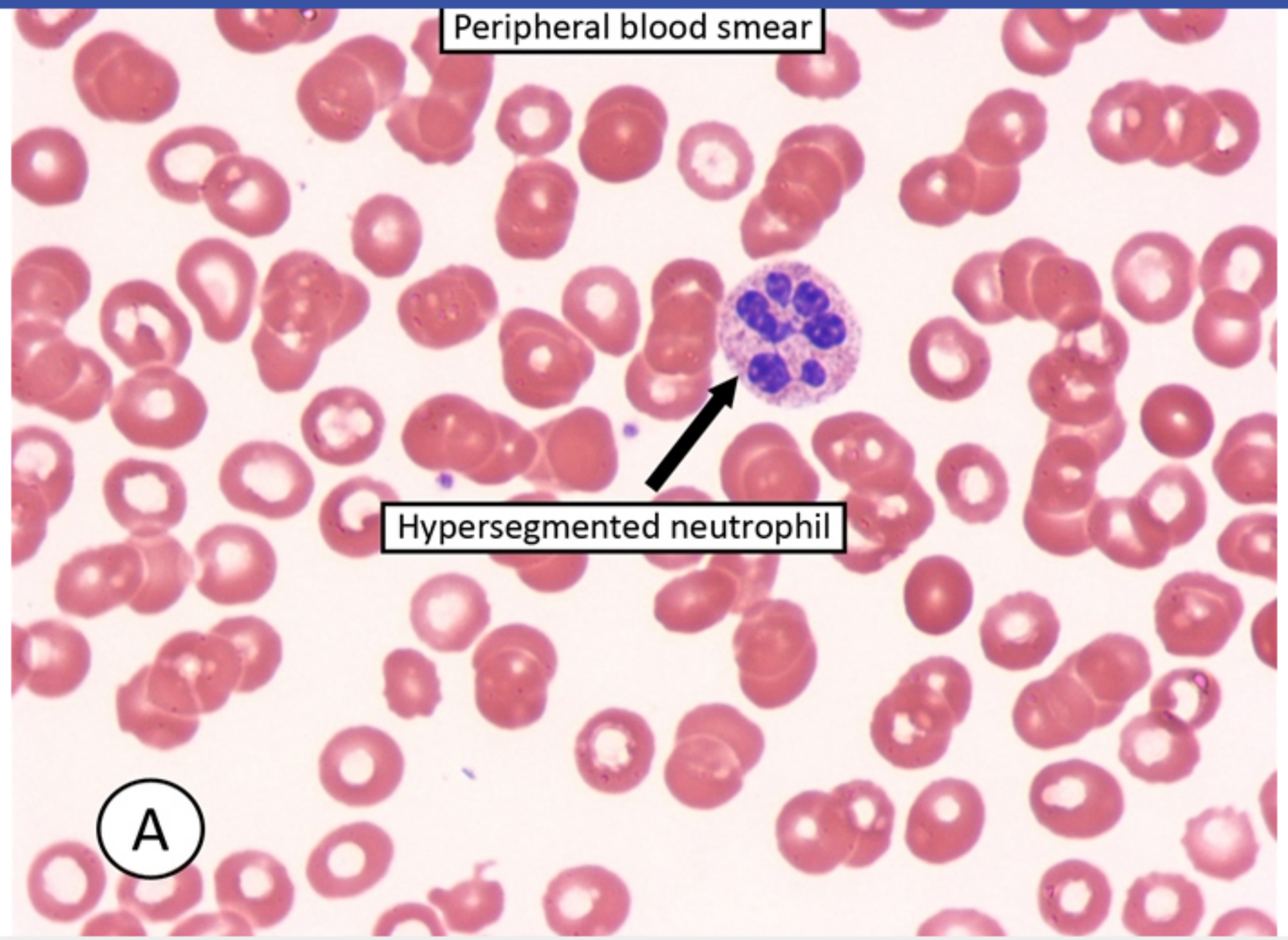

Zoom In | Zoom Out | Reset | Add To New Card | Existing Card

1
2
3
4
5
6
7
8
9
10
11
12
13
14
15
16
17
18
19
20
21
22
23
24
25
26
27
28
29
30

The following vignette applies to the next **2** items. The items in the set must be answered in sequential order. Once you click **Proceed to Next Item**, you will not be able to add or change an answer.

A 36-year-old woman comes to the office after she noticed some lumps under her arm while getting dressed. She says she feels fine and has no other symptoms. Her medical history is significant for hypothyroidism. Family history is negative. On physical examination, her body mass index is 24 kg/m^2. Breast examination shows nontender left axillary lymphadenopathy. The patient is sent for an ultrasound-guided biopsy. Microscopy of the tissue specimen shows clumps of cells that have positive immunohistochemical staining for cytokeratin.

Item 1 of 2

These cells most likely belong to which of the following lineages?

A. Epithelial
B. Lymphoid
C. Mesenchymal
D. Myeloid
E. Neuroendocrine

Submit

The following vignette applies to the next **2** items. The items in the set must be answered in sequential order. Once you click **Proceed to Next Item**, you will not be able to add or change an answer.

A 36-year-old woman comes to the office after she noticed some lumps under her arm while getting dressed. She says she feels fine and has no other symptoms. Her medical history is significant for hypothyroidism. Family history is negative. On physical examination, her body mass index is 24 kg/m^2. Breast examination shows nontender left axillary lymphadenopathy. The patient is sent for an ultrasound-guided biopsy. Microscopy of the tissue specimen shows clumps of cells that have positive immunohistochemical staining for cytokeratin.

Item 1 of 2

These cells most likely belong to which of the following lineages?

- ✓ A. Epithelial (84%)
- B. Lymphoid (4%)
- C. Mesenchymal (7%)
- D. Myeloid (1%)
- E. Neuroendocrine (2%)

Omitted
Correct answer
A

84%
Answered correctly

02 secs
Time Spent

04/16/2020
Last Updated

Explanation

Explanation

Cytokeratins are proteins that help form the keratin-containing intermediate filaments that make up the cytoskeleton of almost all epithelial cells. Keratin proteins are highly abundant in exposed stratified squamous epithelium such as the epidermis and oral mucosa and are less abundant but still present in simple epithelium such as that found in the liver, gut, and pancreas. As a result, cytokeratin is a commonly used immunohistochemical **marker for epithelial-derived tumors**, such as breast cancer. Keratin is also the major protein component of hair and nails.

Keratin is composed of large amounts of alanine and glycine that, because of their small structure, are able to coil tightly and form large numbers of hydrogen bonds. In addition, keratin contains a significant amount of the sulfur-containing amino acid cysteine, and formation of disulfide bonds between cysteine residues gives additional rigidity and toughness to the protein.

(Choice B) CD20 is a marker used to identify B lymphocytes, and CD3 is used to identify T lymphocytes.

(Choice C) Vimentin is an intermediate filament present in mesenchymal tissue and can be used to detect sarcomas.

(Choice D) Myeloperoxidase is a peroxidase enzyme that can be used as a marker for myeloid cells such as those in acute myeloid leukemia.

(Choice E) Chromogranin A and synaptophysin are markers used for neuroendocrine tumors.

Educational objective:
Cytokeratin is a commonly used immunohistochemical marker of epithelial cell carcinomas.

References

- Recommendations for human epidermal growth factor receptor 2 testing in breast cancer: American Society of Clinical Oncology/College of American Pathologists clinical practice guideline update.

Pathology	Hematology & Oncology	Breast cancer
Subject	System	Topic

Copyright © UWorld. All rights reserved.

Item 2 of 2

The cells identified by the special immunohistochemical stain are shown to overexpress a 185 kD glycoprotein that spans the cell membrane and has tyrosine kinase activity in the intracellular domain. Which of the following is the most likely function of this protein?

A. Accelerates cell proliferation

B. Acts as a sex hormone receptor

C. Governs intercellular binding

D. Induces cytokine release

E. Mediates endocytosis

Submit

Item 2 of 2

The cells identified by the special immunohistochemical stain are shown to overexpress a 185 kD glycoprotein that spans the cell membrane and has tyrosine kinase activity in the intracellular domain. Which of the following is the most likely function of this protein?

- ✓ A. Accelerates cell proliferation (68%)
- B. Acts as a sex hormone receptor (11%)
- C. Governs intercellular binding (9%)
- D. Induces cytokine release (8%)
- E. Mediates endocytosis (2%)

Omitted
Correct answer
A

68%
Answered correctly

02 secs
Time Spent

04/16/2020
Last Updated

Explanation

The **HER2 oncogene** codes for a human epidermal growth factor receptor with tyrosine kinase activity in the intracellular domain. It is known to play a role in the activation of transduction pathways that control epithelial growth and differentiation. Epithelial cell carcinomas that overexpress HER2 demonstrate **increased proliferation** and resistance to apoptosis. Consequently, HER2-positive breast cancers have a higher risk of disease recurrence and **worse prognosis** compared to HER2-negative breast cancers. **Trastuzumab** (a monoclonal antibody against HER2) is used to treat women who test positive for overexpression of the HER2 oncogene.

(Choice B) Estrogen and progesterone receptors are intracellular receptors that are frequently overexpressed in patients with breast cancer.

The **HER2 oncogene** codes for a human epidermal growth factor receptor with tyrosine kinase activity in the intracellular domain. It is known to play a role in the activation of transduction pathways that control epithelial growth and differentiation. Epithelial cell carcinomas that overexpress HER2 demonstrate **increased proliferation** and resistance to apoptosis. Consequently, HER2-positive breast cancers have a higher risk of disease recurrence and **worse prognosis** compared to HER2-negative breast cancers. **Trastuzumab** (a monoclonal antibody against HER2) is used to treat women who test positive for overexpression of the HER2 oncogene.

(Choice B) Estrogen and progesterone receptors are intracellular receptors that are frequently overexpressed in patients with breast cancer. Stimulation of these hormone receptors increases cellular proliferation, and patients with hormone-receptor-positive breast cancer are treated with antiestrogen medications to suppress tumor growth.

(Choice C) Intercellular binding is mediated by cell surface proteins such as intercellular adhesion molecules (ICAMs), selectins, and numerous others. Many adhesion proteins, including ICAMS, also play a role in signal transduction.

(Choice D) Various hormones, cytokines, and other stimuli can induce cytokine release from a number of cell types. One example of a receptor that induces cytokine release is the Toll-like receptor, which detects conserved microbial molecular structures.

(Choice E) Clathrin is an intracellular protein that helps form rounded vesicles in the cytoplasm. Clathrin-coated vesicles help mediate intracellular trafficking and endocytosis.

Educational objective:
The HER2 oncogene encodes for a transmembrane glycoprotein with intrinsic tyrosine kinase activity and is a member of the family of epidermal growth factor receptors. Overexpression of this protein is associated with a worse prognosis and increased risk of disease recurrence.

References

- Expression of the p185 encoded by HER2 oncogene in normal and transformed human tissues.

Pathology	Hematology & Oncology	Breast cancer
Subject	System	Topic

Copyright © UWorld. All rights reserved.

1
2
3
4
5
6
7
8
9
10
11
12
13
14
15
16
17
18
19
20
21
22
23
24
25
26
27
28
29
30

A 60-year-old African-American female is evaluated for fatigue. Past surgical history includes mitral valve repair with a mechanical valve due to severe mitral insufficiency. She has 30-pack year history of smoking and occasionally drinks alcohol. Examination shows pallor. Laboratory studies show the following:

Complete blood count

Hemoglobin	9.0 g/L
Reticulocytes	6.8%
Platelets	218,000/mm^3
Leukocyte count	4,500/mm^3

Serum chemistries are within normal limits. Her peripheral smear shows red blood cell fragments, "burr cells," and "helmet cells". Which of the following is the most likely cause of her condition?

A. Microvascular thrombi
B. Cytoskeleton abnormality
C. Impaired DNA synthesis
D. Gastrointestinal blood loss
E. Mutation in beta globin chain
F. Complement mediated hemolysis
G. Mechanical trauma

1 2 3 4 5 6 7 8 9 10 11 12 13 14 15 16 17 18 19 20 21 22 23 24 25 26 27 28 29 30

severe mitral insufficiency. She has 30-pack year history of smoking and occasionally drinks alcohol. Examination shows pallor. Laboratory studies show the following:

Complete blood count

Hemoglobin	9.0 g/L
Reticulocytes	6.8%
Platelets	218,000/mm^3
Leukocyte count	4,500/mm^3

Serum chemistries are within normal limits. Her peripheral smear shows red blood cell fragments, "burr cells," and "helmet cells". Which of the following is the most likely cause of her condition?

A. Microvascular thrombi
B. Cytoskeleton abnormality
C. Impaired DNA synthesis
D. Gastrointestinal blood loss
E. Mutation in beta globin chain
F. Complement mediated hemolysis
G. Mechanical trauma

Submit

severe mitral insufficiency. She has 30-pack year history of smoking and occasionally drinks alcohol. Examination shows pallor. Laboratory studies show the following:

Complete blood count

Hemoglobin	9.0 g/L
Reticulocytes	6.8%
Platelets	218,000/mm^3
Leukocyte count	4,500/mm^3

Serum chemistries are within normal limits. Her peripheral smear shows red blood cell fragments, "burr cells," and "helmet cells". Which of the following is the most likely cause of her condition?

A. Microvascular thrombi (6%)
B. Cytoskeleton abnormality (3%)
C. Impaired DNA synthesis (1%)
D. Gastrointestinal blood loss (1%)
E. Mutation in beta globin chain (3%)
F. Complement mediated hemolysis (3%)
✓ G. Mechanical trauma (80%)

Omitted
Correct answer

80%
Answered correctly

04 secs
Time Spent

02/03/2020
Last Updated

1
2
3
4
5
6
7
8
9
10
11
12
13
14
15
16
17
18
19
20
21
22
23
24
25
26
27
28
29
30

Explanation

All of the choices represent mechanisms for anemia. The key to answering this question is this patient's history and peripheral smear. Red blood cell fragments, burr cells and helmet cells are consistent with traumatic hemolysis, which can result from either microangiopathic hemolytic anemia or mechanical damage (e.g. prosthetic valve).

Prosthetic valves produce excessive shear and turbulence in the cardiac circulation, causing mechanical trauma to the RBCs.

Burr cells are erythrocytes with short, evenly-spaced projections. They can occur as an artifact or in association with uremia, pyruvate kinase deficiency, microangiopathic hemolytic anemia, or mechanical damage.

(Choice A) Microvascular thrombi are the pathophysiologic mechanism for microangiopathic hemolytic anemia, which causes thrombocytopenia. In this patient, platelet count is normal.

(Choice B) Cytoskeleton abnormalities describe an intracorpuscular defect characteristic of a group of anemias that includes hereditary spherocytosis, hereditary elliptocytosis, and hereditary stomatocytosis. Respectively, spherocytes, elliptocytes, or stomatocytes are characteristically seen in the peripheral blood smear.

(Choice C) Impaired DNA synthesis is the pathophysiologic mechanism for megaloblastic anemia. Ovalo-macrocytes are the associated morphologic RBC variant seen in this group of anemia. In addition, hypersegmented neutrophils are also characteristic.

(Choice D) Gastrointestinal blood loss results in hypochromic, microcytic anemia due to iron deficiency.

(Choice E) Mutation of the beta globin chain results in beta thalassemia; target cells are the RBC morphologic variant commonly seen.

(Choice F) Paroxysmal nocturnal hemoglobinuria is an episodic hemolysis caused by a complement-mediated mechanism. Leukopenia and thrombocytopenia (pancytopenia) are commonly associated.

Educational Objective:

- Red blood cell fragments, burr cells, and helmet cells are associated with either microangiopathic hemolytic anemia or mechanical red cell destruction.
- In patients with prosthetic valves, red blood cells are exposed to excessive shear and turbulence in the circulation, causing damage from

1
2
3
4
5
6
7
8
9
10
11
12
13
14
15
16
17
18
19
20
21
22
23
24
25
26
27
28
29
30

A 32-year-old man comes to the office due to progressive fatigue, easy bruising, and recurring episodes of gum bleeding. Physical examination shows several ecchymoses in his lower extremities. Laboratory studies are as follows:

Complete blood count	
Hemoglobin	7.8 g/dL
Platelets	65,000/mm^3
Leukocytes	3,000/mm^3
Coagulation studies	
Prothrombin time	22 sec
Activated partial thromboplastin time	53 sec
Plasma fibrinogen	134 mg/dL (normal: 200-400 mg/dL)
D-dimer	4.1 µg/dL (normal: <0.5 µg/dL)

Bone marrow biopsy is performed and fluorescence in situ hybridization studies reveal a balanced translocation between the long arms of chromosomes 15 and 17. Which of the following proteins is most likely to be abnormal in the hematopoietic cells of this patient?

A. Epidermal growth factor receptor
B. GTP-binding protein
C. Platelet-derived growth factor receptor
D. Retinoblastoma gene product
E. Retinoic acid receptor

Hemoglobin	7.8 g/dL
Platelets	65,000/mm^3
Leukocytes	3,000/mm^3
Coagulation studies	
Prothrombin time	22 sec
Activated partial thromboplastin time	53 sec
Plasma fibrinogen	134 mg/dL (normal: 200-400 mg/dL)
D-dimer	4.1 µg/dL (normal: <0.5 µg/dL)

Bone marrow biopsy is performed and fluorescence in situ hybridization studies reveal a balanced translocation between the long arms of chromosomes 15 and 17. Which of the following proteins is most likely to be abnormal in the hematopoietic cells of this patient?

A. Epidermal growth factor receptor
B. GTP-binding protein
C. Platelet-derived growth factor receptor
D. Retinoblastoma gene product
E. Retinoic acid receptor

Submit

Hemoglobin	7.8 g/dL
Platelets	65,000/mm^3
Leukocytes	3,000/mm^3
Coagulation studies	
Prothrombin time	22 sec
Activated partial thromboplastin time	53 sec
Plasma fibrinogen	134 mg/dL (normal: 200-400 mg/dL)
D-dimer	4.1 µg/dL (normal: <0.5 µg/dL)

Bone marrow biopsy is performed and fluorescence in situ hybridization studies reveal a balanced translocation between the long arms of chromosomes 15 and 17. Which of the following proteins is most likely to be abnormal in the hematopoietic cells of this patient?

A. Epidermal growth factor receptor (4%)
B. GTP-binding protein (5%)
C. Platelet-derived growth factor receptor (14%)
D. Retinoblastoma gene product (3%)
✓ E. Retinoic acid receptor (71%)

Omitted
Correct answer

71%
Answered correctly

03 secs
Time Spent

02/03/2020
Last Updated

1 2 3 4 5 6 7 8 9 10 11 12 13 14 15 16 17 18 19 20 21 22 23 24 25 26 27 28 29 30

Explanation

Acute myelogenous leukemia (AML), characterized by failure of immature myeloid precursors (myeloblasts) to differentiate into mature granulocytes, is divided into 8 types (M0 through M7). **Acute promyelocytic leukemia** (APML), the M3 variant of AML, is associated with the **t(15;17)** cytogenetic translocation involving the promyelocytic leukemia (*PML*) gene on chromosome 15 and the retinoic acid receptor alpha (*RARA*) gene on chromosome 17. Fusion of these 2 genes produces ***PML/RARA***, a chimeric gene (illustrated in this fluorescence in situ hybridization image) that codes for an abnormal **retinoic acid receptor**, which then inhibits myeloblast differentiation. Abnormal promyelocytes and Auer rods are seen on the smear.

The clinical manifestations of AML, including anemia (fatigue, pallor), thrombocytopenia (petechiae, hemorrhages), and neutropenia (fever, opportunistic infections), result from marrow replacement by leukemic cells. As seen in this patient, APML is associated with **disseminated intravascular coagulation (DIC)**, which is characterized by activation of the coagulation cascade. Laboratory findings seen in DIC include thrombocytopenia, elevated D-dimer due to fibrinolysis, and prolonged coagulation profile times (eg, prothrombin time, activated partial thromboplastin time) and low fibrinogen due to consumption.

All-trans retinoic acid is used for treatment of APML.

(Choice A) Mutations in the genes that code for the epidermal growth factor receptors are associated with certain lung (*ERBB1*), breast (*ERBB2*, also known as *HER2/neu*), ovarian, and gastric tumors.

(Choice B) GTP-binding proteins are involved in cellular signal transduction.

(Choice C) A defective platelet-derived growth factor receptor plays a role in the pathogenesis of several cancers, including ovarian cancers.

(Choice D) An abnormal *RB* gene predisposes to development of retinoblastoma and osteosarcoma.

Educational objective:
The cytogenetic defect t(15;17) is associated with acute promyelocytic leukemia (APML). A translocation involving the retinoic acid receptor alpha (*RARA*) gene from chromosome 17 and the promyelocytic leukemia (*PML*) gene on chromosome 15 leads to the formation of *PML/RARA*, a fusion gene whose product inhibits differentiation of myeloblasts and triggers the development of APML.

1
2
3
4
5
6
7
8
9
10
11
12
13
14
15
16
17
18
19
20
21
22
23
24
25
26
27
28
29
30

Explanation

Exhibit Display

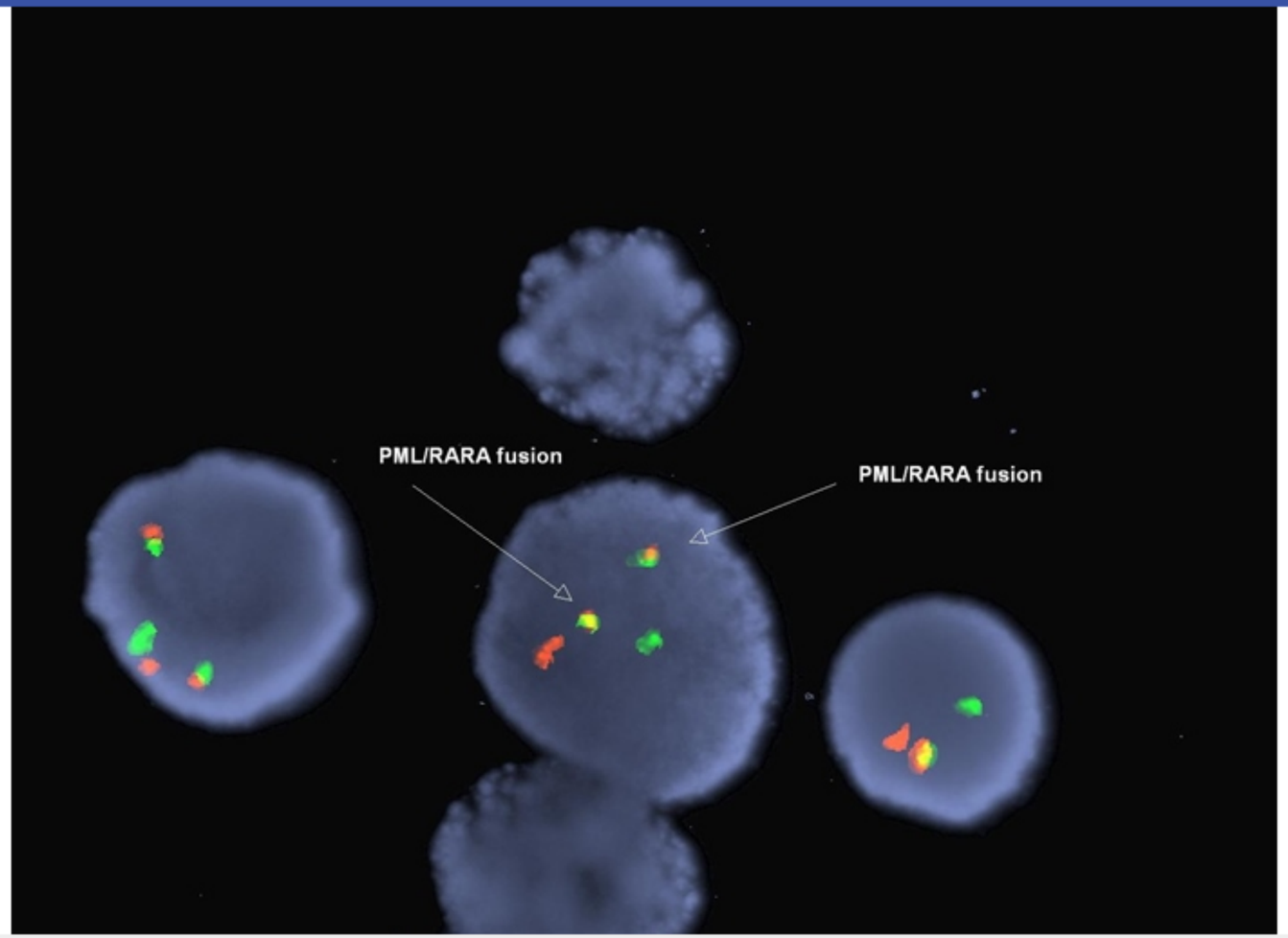

Zoom In | Zoom Out | Reset | Add To New Card | Existing Card

1 2 3 4 5 6 7 8 9 10 11 12 13 14 15 16 17 18 19 20 21 22 23 24 25 26 27 28 29 30

granulocytes, is divided into 8 types (M0 through M7). **Acute promyelocytic leukemia** (APML), the M3 variant of AML, is associated with the **t(15;17)** cytogenetic translocation involving the promyelocytic leukemia (*PML*) gene on chromosome 15 and the retinoic acid receptor alpha (*RARA*) gene on chromosome 17. Fusion of these 2 genes produces ***PML/RARA***, a chimeric gene (illustrated in this fluorescence in situ hybridization image) that codes for an abnormal **retinoic acid receptor**, which then inhibits myeloblast differentiation. Abnormal promyelocytes and Auer rods are seen on the smear.

The clinical manifestations of AML, including anemia (fatigue, pallor), thrombocytopenia (petechiae, hemorrhages), and neutropenia (fever, opportunistic infections), result from marrow replacement by leukemic cells. As seen in this patient, APML is associated with **disseminated intravascular coagulation (DIC)**, which is characterized by activation of the coagulation cascade. Laboratory findings seen in DIC include thrombocytopenia, elevated D-dimer due to fibrinolysis, and prolonged coagulation profile times (eg, prothrombin time, activated partial thromboplastin time) and low fibrinogen due to consumption.

All-trans retinoic acid is used for treatment of APML.

(Choice A) Mutations in the genes that code for the epidermal growth factor receptors are associated with certain lung (*ERBB1*), breast (*ERBB2*, also known as *HER2/neu*), ovarian, and gastric tumors.

(Choice B) GTP-binding proteins are involved in cellular signal transduction.

(Choice C) A defective platelet-derived growth factor receptor plays a role in the pathogenesis of several cancers, including ovarian cancers.

(Choice D) An abnormal *RB* gene predisposes to development of retinoblastoma and osteosarcoma.

Educational objective:
The cytogenetic defect t(15;17) is associated with acute promyelocytic leukemia (APML). A translocation involving the retinoic acid receptor alpha (*RARA*) gene from chromosome 17 and the promyelocytic leukemia (*PML*) gene on chromosome 15 leads to the formation of *PML/RARA*, a fusion gene whose product inhibits differentiation of myeloblasts and triggers the development of APML.

Pathology	Hematology & Oncology	Acute promyelocytic leukemia
Subject	System	Topic

Copyright © UWorld. All rights reserved.

1
2
3
4
5
6
7
8
9
10
11
12
13
14
15
16
17
18
19
20
21
22
23
24
25
26
27
28
29
30

A 26-year-old Caucasian female is found to have a single amino acid substitution (glutamine for arginine) near the protein C cleavage site in her coagulation factor V gene product. The patient is at greatest risk for developing which of the following conditions?

A. Petechiae and ecchymoses

B. Recurrent hemarthroses

C. Renal artery stenosis

D. Splenic infarction

E. Pulmonary thromboembolism

Submit

1
2
3
4
5
6
7
8
9
10
11
12
13
14
15
16
17
18
19
20
21
22
23
24
25
26
27
28
29
30

A 26-year-old Caucasian female is found to have a single amino acid substitution (glutamine for arginine) near the protein C cleavage site in her coagulation factor V gene product. The patient is at greatest risk for developing which of the following conditions?

A. Petechiae and ecchymoses (14%)
B. Recurrent hemarthroses (12%)
C. Renal artery stenosis (1%)
D. Splenic infarction (5%)
✓ E. Pulmonary thromboembolism (65%)

Omitted
Correct answer
E

65%
Answered correctly

01 sec
Time Spent

02/03/2020
Last Updated

Explanation

The major clinical manifestations of factor V Leiden include deep vein thrombosis (DVT), cerebral vein thrombosis, and recurrent pregnancy loss. Because pulmonary thromboembolism occurs in approximately 50% of all individuals with untreated DVTs, the young woman presented here is at significant risk of developing a pulmonary thromboembolism at some point in her lifetime.

Factor V Leiden is the most common cause of inherited thrombophilia, with the heterozygote prevalence of this genetic mutation ranging from 1-9% in Caucasian populations worldwide. Heterozygote carriers of factor V Leiden have five to ten times the risk of developing a thrombosis, while homozygote carriers of factor V Leiden have fifty to one hundred times the risk of developing a thrombosis.

1 2 3 4 5 6 7 8 9 10 11 12 13 14 15 16 17 18 19 20 21 22 23 24 25 26 27 28 29 30

The major clinical manifestations of factor V Leiden include deep vein thrombosis (DVT), cerebral vein thrombosis, and recurrent pregnancy loss. Because pulmonary thromboembolism occurs in approximately 50% of all individuals with untreated DVTs, the young woman presented here is at significant risk of developing a pulmonary thromboembolism at some point in her lifetime.

Factor V Leiden is the most common cause of inherited thrombophilia, with the heterozygote prevalence of this genetic mutation ranging from 1-9% in Caucasian populations worldwide. Heterozygote carriers of factor V Leiden have five to ten times the risk of developing a thrombosis, while homozygote carriers of factor V Leiden have fifty to one hundred times the risk of developing a thrombosis.

Factor V Leiden causes thrombophilia through two pathophysiological mechanisms. In normal hemostasis, activated protein C (APC) restricts clot formation by proteolytically inactivating factors Va and VIIIa. Factor Va Leiden has reduced susceptibility to cleavage by APC, however. Because factor Va is a cofactor in the conversion of prothrombin to thrombin, persistently circulating factor Va Leiden results in increased thrombin production. Additionally, factor V Leiden is unable to support APC anticoagulant activity. This combination of increased coagulation and decreased anticoagulation produces the hypercoagulable state seen in those with factor V Leiden.

(Choice A) Petechiae and ecchymoses are more consistent with qualitative or quantitative platelet abnormalities than factor V Leiden.

(Choice B) Recurrent hemarthroses are suggestive of hemophilia (factor VIII or IX deficiency), not factor V Leiden.

(Choice C) Renal artery stenosis is primarily caused by atherosclerosis and fibromuscular disease, not thrombosis. Moreover, factor V Leiden is associated with an increased risk of deep venous (not arterial) thrombosis.

(Choice D) Major causes of splenic infarction include sickle cell anemia, infectious endocarditis, and myeloproliferative disorders. Moreover, the factor V Leiden mutation is associated with deep venous (not arterial) thrombosis.

Educational Objective:
One to nine percent of Caucasians worldwide are heterozygote carriers of factor V Leiden, which is modified to resist activated protein C. The resulting hypercoagulable state predisposes to deep vein thromboses, which are the source of most pulmonary emboli.

Pathology	Hematology & Oncology	Inherited thrombophilia
Subject	System	Topic

1 2 3 4 5 6 7 8 9 10 11 12 13 14 15 16 17 18 19 20 21 22 23 24 25 26 27 28 29 30

Because pulmonary thromboembolism occurs in approximately 50% of all individuals with untreated DVTs, the young woman presented here is at significant risk of developing a pulmonary thromboembolism at some point in her lifetime.

Factor V Leiden is the most common cause of inherited thrombophilia, with the heterozygote prevalence of this genetic mutation ranging from 1-9% in Caucasian populations worldwide. Heterozygote carriers of factor V Leiden have five to ten times the risk of developing a thrombosis, while homozygote carriers of factor V Leiden have fifty to one hundred times the risk of developing a thrombosis.

Factor V Leiden causes thrombophilia through two pathophysiological mechanisms. In normal hemostasis, activated protein C (APC) restricts clot formation by proteolytically inactivating factors Va and VIIIa. Factor Va Leiden has reduced susceptibility to cleavage by APC, however. Because factor Va is a cofactor in the conversion of prothrombin to thrombin, persistently circulating factor Va Leiden results in increased thrombin production. Additionally, factor V Leiden is unable to support APC anticoagulant activity. This combination of increased coagulation and decreased anticoagulation produces the hypercoagulable state seen in those with factor V Leiden.

(Choice A) Petechiae and ecchymoses are more consistent with qualitative or quantitative platelet abnormalities than factor V Leiden.

(Choice B) Recurrent hemarthroses are suggestive of hemophilia (factor VIII or IX deficiency), not factor V Leiden.

(Choice C) Renal artery stenosis is primarily caused by atherosclerosis and fibromuscular disease, not thrombosis. Moreover, factor V Leiden is associated with an increased risk of deep venous (not arterial) thrombosis.

(Choice D) Major causes of splenic infarction include sickle cell anemia, infectious endocarditis, and myeloproliferative disorders. Moreover, the factor V Leiden mutation is associated with deep venous (not arterial) thrombosis.

Educational Objective:
One to nine percent of Caucasians worldwide are heterozygote carriers of factor V Leiden, which is modified to resist activated protein C. The resulting hypercoagulable state predisposes to deep vein thromboses, which are the source of most pulmonary emboli.

Pathology	Hematology & Oncology	Inherited thrombophilia
Subject	System	Topic

Copyright © UWorld. All rights reserved.

1
2
3
4
5
6
7
8
9
10
11
12
13
14
15
16
17
18
19
20
21
22
23
24
25
26
27
28
29
30

A 35-year-old woman comes to the hospital due to sudden-onset numbness of the left arm and face. The patient has no weakness but has had several days of generalized headache, dyspnea on exertion, and easy fatigability. She has a history of well-controlled asthma. Temperature is 37.7 C (99.8 F), blood pressure is 110/60 mm Hg, and pulse is 80/min. Light touch sensation is decreased in the left upper extremity and the lower left face. Strength and reflexes are normal. Cardiopulmonary and abdominal examinations are unremarkable. She has no skin rash. Laboratory results are as follows:

Hemoglobin	8.6 g/dL
Platelets	24,000/mm^3
Blood urea nitrogen	32 mg/dL
Creatinine	1.9 mg/dL

Prothrombin time and activated partial thromboplastin time are normal. Peripheral blood smear shows numerous schistocytes. Urinalysis is positive for hematuria and proteinuria. Which of the following is the most likely primary pathogenesis of this patient's current condition?

A. IgA immune complex deposition
B. Impaired cleavage of von Willebrand factor
C. Plasma cell proliferation
D. Rupture of atheromatous plaque
E. Systemic coagulation factor activation

Submit

A 35-year-old woman comes to the hospital due to sudden-onset numbness of the left arm and face. The patient has no weakness but has had several days of generalized headache, dyspnea on exertion, and easy fatigability. She has a history of well-controlled asthma. Temperature is 37.7 C (99.8 F), blood pressure is 110/60 mm Hg, and pulse is 80/min. Light touch sensation is decreased in the left upper extremity and the lower left face. Strength and reflexes are normal. Cardiopulmonary and abdominal examinations are unremarkable. She has no skin rash. Laboratory results are as follows:

Hemoglobin	8.6 g/dL
Platelets	24,000/mm^3
Blood urea nitrogen	32 mg/dL
Creatinine	1.9 mg/dL

Prothrombin time and activated partial thromboplastin time are normal. Peripheral blood smear shows numerous schistocytes. Urinalysis is positive for hematuria and proteinuria. Which of the following is the most likely primary pathogenesis of this patient's current condition?

- A. IgA immune complex deposition (21%)
- ✓ B. Impaired cleavage of von Willebrand factor (39%)
- C. Plasma cell proliferation (7%)
- D. Rupture of atheromatous plaque (9%)
- E. Systemic coagulation factor activation (22%)

Omitted
Correct answer

39%
Answered correctly

02 secs
Time Spent

03/17/2020
Last Updated

Thrombotic thrombocytopenic purpura	
Pathophysiology	• ↓ **ADAMTS13 level** → uncleaved vWF multimers → platelet trapping & activation • Acquired (autoantibody) or hereditary
Clinical features	• Hemolytic **anemia** (↑ LDH, ↓ haptoglobin) with **schistocytes** • **Thrombocytopenia** (↑ bleeding time, normal PT/PTT) Sometimes with: • Renal failure • Neurologic manifestations • Fever
Management	• Plasma exchange • Glucocorticoids • Rituximab

LDH = lactate dehydrogenase; **vWF** = von Willebrand factor.

This patient, who has new-onset neurologic symptoms, anemia with schistocytes, thrombocytopenia, and acute kidney injury, likely has **thrombotic thrombocytopenic purpura** (TTP). Her left arm and lower facial sensory loss are consistent with a pure sensory lacunar stroke, and her exertional dyspnea and easy fatigability are secondary to anemia. Patients may also develop cutaneous petechiae or purpuric lesions due to significantly low platelet counts.

TTP results from **deficiency of ADAMTS13**, a von Willebrand factor (vWF)-cleaving protease. Normally, circulating vWF (produced by megakaryocytes and endothelial cells) is released as large vWF multimers that are cleaved to their regular size by ADAMTS13. These vWF multimers aid hemostasis by bridging platelets and subendothelial components to sites of vascular injury. In TTP, the large **uncleaved vWF multimers** are significantly more prothrombotic and result in diffuse **microvascular thrombosis**. **Thrombocytopenia** and **microangiopathic hemolytic anemia** with schistocyte formation occur as erythrocytes are sheared by platelet-rich thrombi. Prothrombin time and partial thromboplastin time are usually normal as coagulation cascade activation plays a less significant role.

1 2 3 4 5 6 7 8 9 10 11 12 13 14 15 16 17 18 19 20 21 22 23 24 25 26 27 28 29 30

This patient, who has new-onset neurologic symptoms, anemia with schistocytes, thrombocytopenia, and acute kidney injury, likely has **thrombotic thrombocytopenic purpura** (TTP). Her left arm and lower facial sensory loss are consistent with a pure sensory lacunar stroke, and her exertional dyspnea and easy fatigability are secondary to anemia. Patients may also develop cutaneous petechiae or purpuric lesions due to significantly low platelet counts.

TTP results from **deficiency of ADAMTS13**, a von Willebrand factor (vWF)-cleaving protease. Normally, circulating vWF (produced by megakaryocytes and endothelial cells) is released as large vWF multimers that are cleaved to their regular size by ADAMTS13. These vWF multimers aid hemostasis by bridging platelets and subendothelial components to sites of vascular injury. In TTP, the large **uncleaved vWF multimers** are significantly more prothrombotic and result in diffuse **microvascular thrombosis**. **Thrombocytopenia** and **microangiopathic hemolytic anemia** with schistocyte formation occur as erythrocytes are sheared by platelet-rich thrombi. Prothrombin time and partial thromboplastin time are usually normal as coagulation cascade activation plays a less significant role.

(Choice A) Henoch-Schönlein purpura (IgA vasculitis) is characterized by IgA immune complex deposition. Typical manifestations include palpable purpura, renal disease, and arthritis/arthralgias. Platelet counts are usually normal.

(Choice C) Some features of this presentation could be explained by plasma cell dyscrasias, such as multiple myeloma (renal failure, anemia due to bone marrow replacement, kidney injury) and Waldenström macroglobulinemia (neurologic symptoms due to hyperviscosity, autoimmune hemolytic anemia). However, microangiopathic hemolytic anemia would be unusual.

(Choice D) A cerebral vascular accident caused by plaque rupture could cause neurologic deficits but would not account for the concurrent hematologic and renal abnormalities.

(Choice E) Disseminated intravascular coagulation (eg, due to sepsis or major trauma) causes systemic activation of the coagulation cascade, leading to consumption of clotting factors and platelets. The classic presentation includes both thrombosis and bleeding as clotting factors are consumed rapidly, resulting in prolonged prothrombin and activated partial thromboplastin times.

Educational objective:
Thrombotic thrombocytopenic purpura results from impaired function of the von Willebrand factor (vWF)-cleaving protease ADAMTS13, resulting in uncleaved vWF multimers that are significantly more prothrombotic and cause diffuse microvascular thrombosis, microangiopathic hemolytic anemia, and thrombocytopenia.

1
2
3
4
5
6
7
8
9
10
11
12
13
14
15
16
17
18
19
20
21
22
23
24
25
26
27
28
29
30

Exhibit Display

Platelet adhesion & activation via vWF

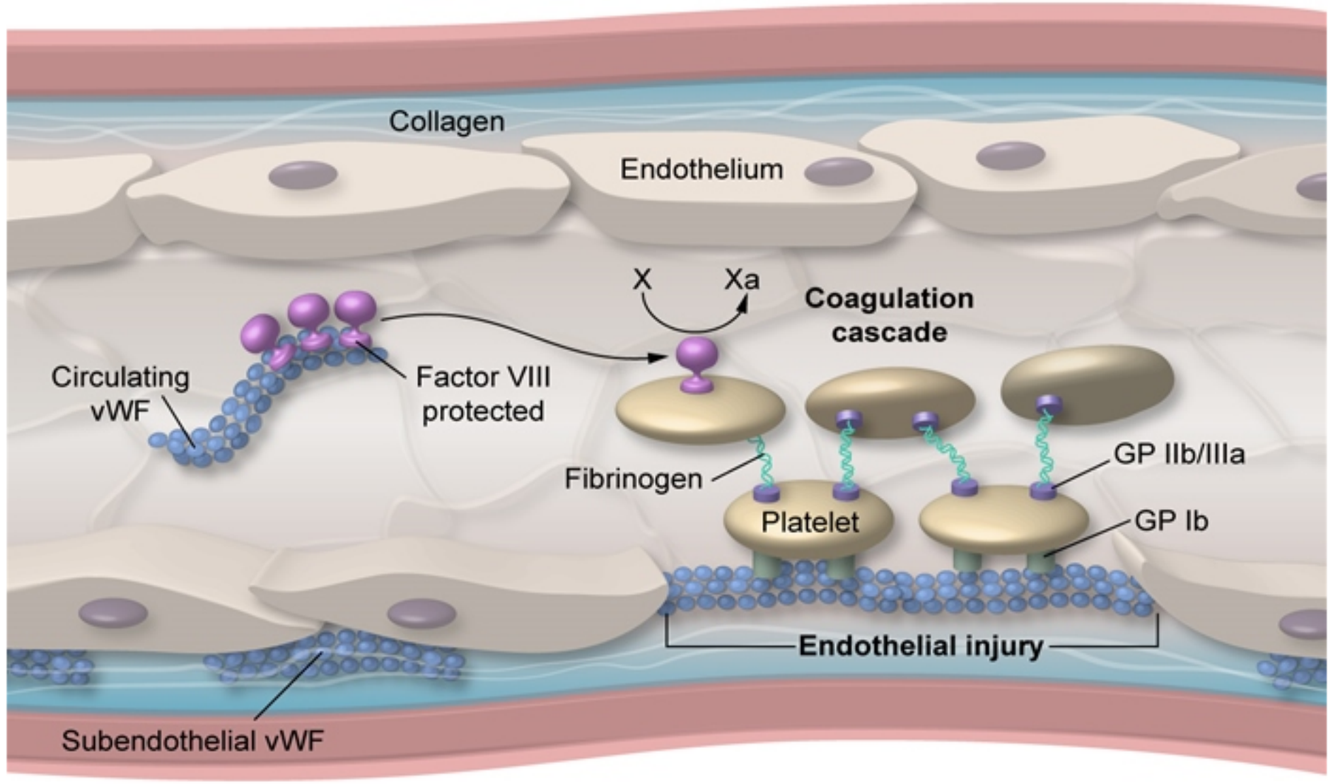

GP = glycoprotein; **vWF** = von Willebrand factor.

©UWorld

Zoom In | Zoom Out | Reset | Add To New Card | Existing Card

anemia, and thrombocytopenia.

1 2 3 4 5 6 7 8 9 10 11 12 13 14 15 16 17 18 19 20 21 22 23 24 25 26 27 28 29 30

(Choice A) Henoch-Schönlein purpura (IgA vasculitis) is characterized by IgA immune complex deposition. Typical manifestations include palpable purpura, renal disease, and arthritis/arthralgias. Platelet counts are usually normal.

(Choice C) Some features of this presentation could be explained by plasma cell dyscrasias, such as multiple myeloma (renal failure, anemia due to bone marrow replacement, kidney injury) and Waldenström macroglobulinemia (neurologic symptoms due to hyperviscosity, autoimmune hemolytic anemia). However, microangiopathic hemolytic anemia would be unusual.

(Choice D) A cerebral vascular accident caused by plaque rupture could cause neurologic deficits but would not account for the concurrent hematologic and renal abnormalities.

(Choice E) Disseminated intravascular coagulation (eg, due to sepsis or major trauma) causes systemic activation of the coagulation cascade, leading to consumption of clotting factors and platelets. The classic presentation includes both thrombosis and bleeding as clotting factors are consumed rapidly, resulting in prolonged prothrombin and activated partial thromboplastin times.

Educational objective:
Thrombotic thrombocytopenic purpura results from impaired function of the von Willebrand factor (vWF)-cleaving protease ADAMTS13, resulting in uncleaved vWF multimers that are significantly more prothrombotic and cause diffuse microvascular thrombosis, microangiopathic hemolytic anemia, and thrombocytopenia.

References

- Thrombotic thrombocytopenic purpura: basic pathophysiology and therapeutic strategies.
- Pathophysiology of thrombotic thrombocytopenic purpura.
- Pathogenesis of thrombotic microangiopathies.

Pathology	Hematology & Oncology	Thrombotic thrombocytopenic purpura
Subject	System	Topic

Copyright © UWorld. All rights reserved.

A research scientist injects hepatocellular carcinoma cells into the liver parenchyma of an experimental guinea pig. Serial observations show that the tumor cells progressively proliferate and invade the liver parenchyma to form a large mass. After some time, malignant cells begin to penetrate the vascular basement membrane to gain access to the circulation. During the process of basement membrane invasion, expression of which of the following substances is most likely to be increased in the tumor cells?

A. Acid hydrolase

B. Alkaline phosphatase

C. Carboxypeptidase

D. E-cadherin

E. Hyaluronic acid

F. Metalloproteinase

Submit

A research scientist injects hepatocellular carcinoma cells into the liver parenchyma of an experimental guinea pig. Serial observations show that the tumor cells progressively proliferate and invade the liver parenchyma to form a large mass. After some time, malignant cells begin to penetrate the vascular basement membrane to gain access to the circulation. During the process of basement membrane invasion, expression of which of the following substances is most likely to be increased in the tumor cells?

- A. Acid hydrolase (3%)
- B. Alkaline phosphatase (3%)
- C. Carboxypeptidase (2%)
- D. E-cadherin (19%)
- E. Hyaluronic acid (4%)
- ✓ F. Metalloproteinase (66%)

Omitted
Correct answer
F

66%
Answered correctly

02 secs
Time Spent

01/29/2020
Last Updated

Explanation

Metalloproteinases are zinc-containing enzymes that degrade components of the extracellular matrix (ECM) and basement membrane, which are composed primarily of laminin and collagens IV and VII. These enzymes participate in many physiologic processes, such as tissue remodeling and embryogenesis. They also facilitate **basement membrane penetration**, which distinguishes an invasive tumor from carcinoma in situ and includes the following steps:

1 2 3 4 5 6 7 8 9 10 11 12 13 14 15 16 17 18 19 20 21 22 23 24 25 26 27 28 29 30

Explanation

Metalloproteinases are zinc-containing enzymes that degrade components of the extracellular matrix (ECM) and basement membrane, which are composed primarily of laminin and collagens IV and VII. These enzymes participate in many physiologic processes, such as tissue remodeling and embryogenesis. They also facilitate **basement membrane penetration**, which distinguishes an invasive tumor from carcinoma in situ and includes the following steps:

1. Tumor cells **detach** from surrounding cells in a process commonly determined by decreased (rather than increased) expression of adhesion molecules, including **E-cadherins (Choice D)**
2. Tumor cells **adhere** to the basement membrane; this is facilitated by increased expression of **laminin** and other adhesion molecules
3. Tumor cells **invade** the basement membrane via enhanced secretion of **proteolytic enzymes** (eg, **metalloproteinases**, cathepsin D protease)

(Choice A) Acid hydrolases, which function at acidic pH, are primarily degradative lysosomal enzymes.

(Choice B) In humans, alkaline phosphatase is concentrated in liver cells; elevated levels suggest an obstructive biliary process.

(Choice C) Carboxypeptidases cleave peptide bonds at the carboxy-terminal; some participate in the synthesis of insulin and neuropeptides.

(Choice E) Hyaluronic acid is an ECM component.

Educational objective:
Metalloproteinases are zinc-containing enzymes that degrade the extracellular matrix. They participate in normal tissue remodeling and in tumor invasion through the basement membrane and connective tissue.

Pathology	Hematology & Oncology	Matrix metalloprotease
Subject	System	Topic

Copyright © UWorld. All rights reserved.

1
2
3
4
5
6
7
8
9
10
11
12
13
14
15
16
17
18
19
20
21
22
23
24
25
26
27
28
29
30

An 18-year-old man is evaluated due to 3 months of lower extremity pain. The pain is persistent and present both day and night. He has no fever, chills, or history of leg trauma. Imaging shows an expansile lesion of the distal femur. Surgical resection is performed, and the specimen is shown below.

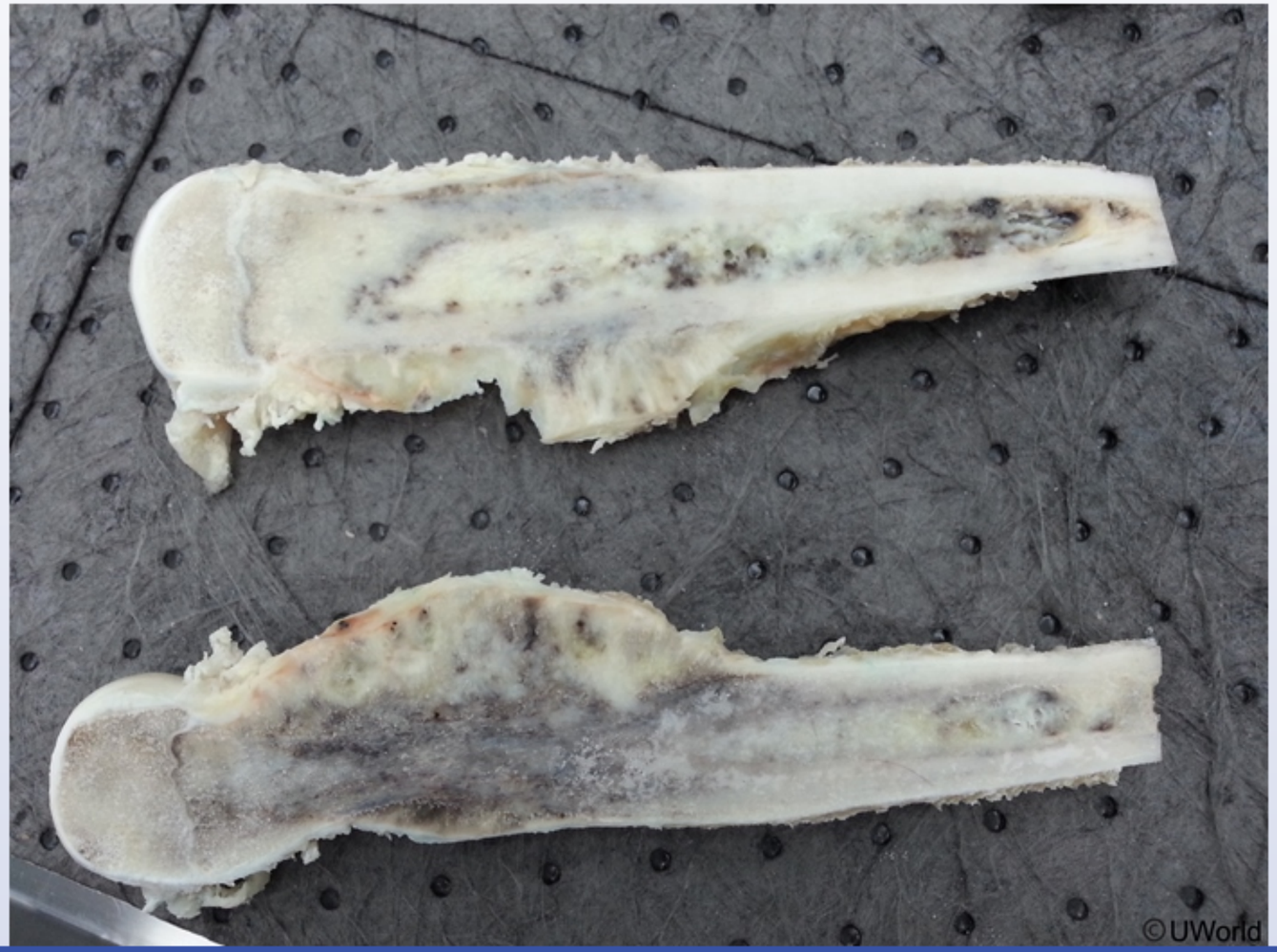

1
2
3
4
5
6
7
8
9
10
11
12
13
14
15
16
17
18
19
20
21
22
23
24
25
26
27
28
29
30

Mutations involving which of the following genes are most likely present in this patient?

- A. *BRAF*
- B. *HER2*
- C. *KRAS*
- D. *RB1*
- E. *RET*

Submit

1
2
3
4
5
6
7
8
9
10
11
12
13
14
15
16
17
18
19
20
21
22
23
24
25
26
27
28
29
30

Mutations involving which of the following genes are most likely present in this patient?

A. *BRAF* (9%)

B. *HER2* (0%)

C. *KRAS* (9%)

✓ D. *RB1* (71%)

E. *RET* (8%)

Omitted
Correct answer

71%
Answered correctly

05 secs
Time Spent

02/01/2020
Last Updated

Proto-oncogenes 1-hit GAIN of function		Tumor suppressor genes 2-hit LOSS of function	
RAS (GTP-binding protein)	• Cholangiocarcinoma • Pancreatic adenocarcinoma	***BRCA1/2*** (DNA repair genes)	• Breast & ovarian cancer
MYC (Transcription factor)	• Burkitt lymphoma	***APC/β-catenin*** (Wnt signaling pathway)	• Colon, gastric & pancreatic cancer • Familial adenomatous polyposis
ERBB1 (EGFR) (Receptor tyrosine kinase)	• Lung adenocarcinoma	***TP53*** (Genomic stability)	• Most cancers • Li-Fraumeni syndrome
ERBB2 (HER2) (Receptor tyrosine kinase)	• Breast cancer	***RB*** (G_1/S transition inhibitor)	• Retinoblastoma • Osteosarcoma
ABL (Nonreceptor	• Chronic myelogenous	***WT1*** (Urogenital	• Wilms tumor

ERBB2 (HER2) (Receptor tyrosine kinase)	• Breast cancer	***RB*** (G_1/S transition inhibitor)	• Retinoblastoma • Osteosarcoma
ABL (Nonreceptor tyrosine kinase)	• Chronic myelogenous leukemia	***WT1*** (Urogenital differentiation)	• Wilms tumor
BRAF (Ras signal transduction)	• Hairy cell leukemia • Melanoma	***VHL*** (Ubiquitin ligase component)	• Renal cell carcinoma • Von Hippel-Lindau syndrome

©UWorld

This patient's expansile tumor in the distal femur likely indicates **osteosarcoma**, the most common primary bone tumor affecting children and **young adults**. Most cases arise at the metaphysis of long bones and present with progressive pain and swelling.

Osteosarcomas typically form when a **mesenchymal stem cell** develops mutations in the following genes:

- ***RB1*** tumor suppressor gene, which encodes for RB, a protein that regulates cell-cycle progression. Inactivating mutations to *RB1* promote unchecked and unregulated cellular replication and are associated with osteosarcoma, **retinoblastoma**, melanoma, and soft-tissue sarcomas.
- *TP53* tumor suppressor gene, which encodes for P53, a protein that regulates cell-cycle progression and maintains genomic integrity by activating DNA repair following damage. Germ-line mutations to *TP53* are associated with **Li-Fraumeni syndrome**, which increases the risk for multiple tumors (eg, osteosarcoma, other bone and soft-tissue sarcomas, breast cancer, brain tumors, adrenal carcinomas).

1 2 3 4 5 6 7 8 9 10 11 12 13 14 15 16 17 18 19 20 21 22 23 24 25 26 27 28 29 30

This patient's expansile tumor in the distal femur likely indicates **osteosarcoma**, the most common primary bone tumor affecting children and **young adults**. Most cases arise at the metaphysis of long bones and present with progressive pain and swelling.

Osteosarcomas typically form when a **mesenchymal stem cell** develops mutations in the following genes:

- ***RB1*** tumor suppressor gene, which encodes for RB, a protein that regulates cell-cycle progression. Inactivating mutations to *RB1* promote unchecked and unregulated cellular replication and are associated with osteosarcoma, **retinoblastoma**, melanoma, and soft-tissue sarcomas.
- *TP53* tumor suppressor gene, which encodes for P53, a protein that regulates cell-cycle progression and maintains genomic integrity by activating DNA repair following damage. Germ-line mutations to *TP53* are associated with **Li-Fraumeni syndrome**, which increases the risk for multiple tumors (eg, osteosarcoma, other bone and soft-tissue sarcomas, breast cancer, brain tumors, adrenal carcinomas).

(Choice A) Activating mutations of *BRAF* are responsible for most cases of hairy cell leukemia, a B-cell neoplasm that typically presents in older patients with pancytopenia, splenomegaly, and systemic symptoms (eg, fatigue, recurrent infections). It is also present in many cases of malignant melanoma.

(Choice B) *HER2*, an oncogene encoding for an epidermal growth factor receptor, is amplified or overexpressed in many forms of invasive breast cancer. Treatment of the *HER2* gene product can improve outcomes in these individuals.

(Choice C) Activating mutations in the *KRAS* proto-oncogene are common in colorectal cancer and non-small cell lung cancer. *KRAS* encodes for a GTPase that relays cellular growth and proliferation signals from outside the cell.

(Choice E) Germ-line mutations of the *RET* proto-oncogene cause multiple endocrine neoplasia type 2, which is associated with pheochromocytoma, medullary thyroid cancer, parathyroid hyperplasia, and/or mucosal neuromas.

Educational objective:
Osteosarcoma is the most common primary bone malignancy in children and young adults. It occurs most frequently at the metaphyses of long bones and presents with local pain and swelling. Most cases are associated with sporadic or inherited mutations in *RB1* (hereditary retinoblastoma) and *TP53* (Li-Fraumeni syndrome).

References

1
2
3
4
5
6
7
8
9
10
11
12
13
14
15
16
17
18
19
20
21
22
23
24
25
26
27
28
29
30

Exhibit Display

Osteosarcoma

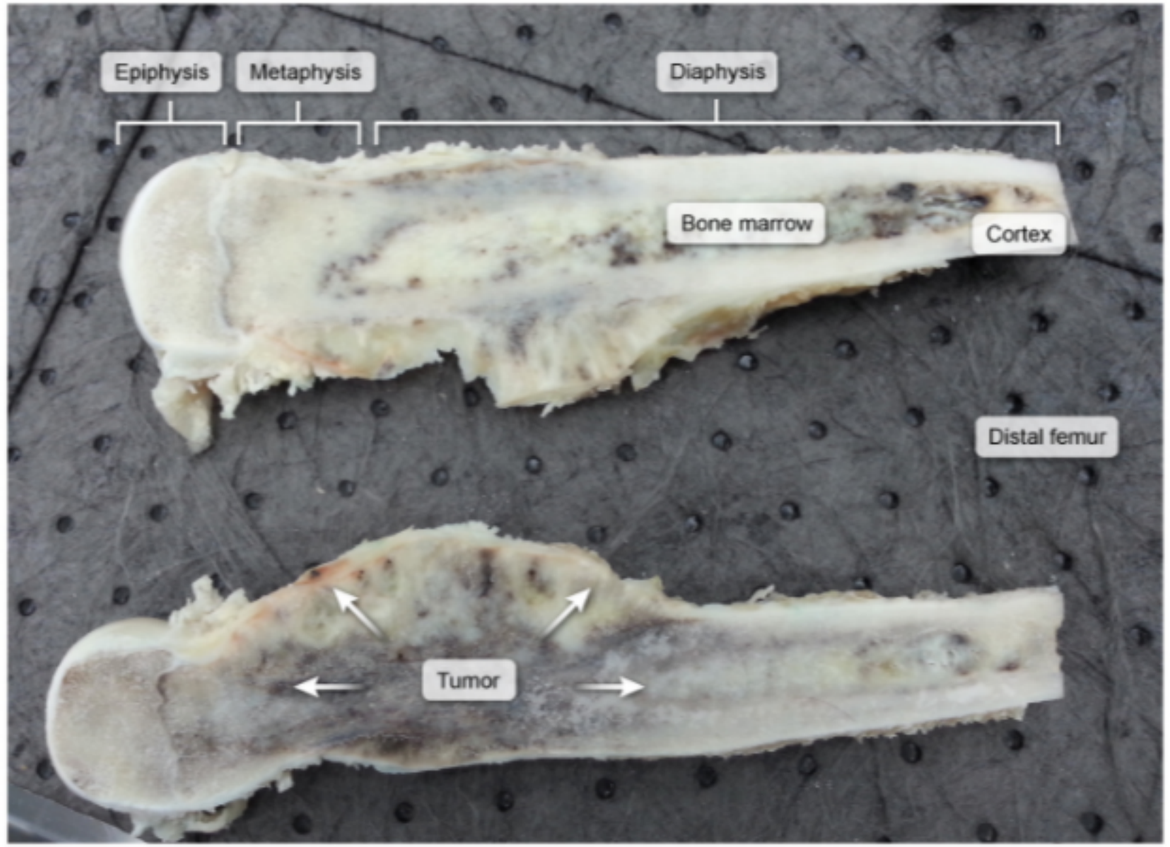

©UWorld

Zoom In | Zoom Out | Reset | Add To New Card | Existing Card

References

sarcomas.

- *TP53* tumor suppressor gene, which encodes for P53, a protein that regulates cell-cycle progression and maintains genomic integrity by activating DNA repair following damage. Germ-line mutations to *TP53* are associated with **Li-Fraumeni syndrome**, which increases the risk for multiple tumors (eg, osteosarcoma, other bone and soft-tissue sarcomas, breast cancer, brain tumors, adrenal carcinomas).

(Choice A) Activating mutations of *BRAF* are responsible for most cases of hairy cell leukemia, a B-cell neoplasm that typically presents in older patients with pancytopenia, splenomegaly, and systemic symptoms (eg, fatigue, recurrent infections). It is also present in many cases of malignant melanoma.

(Choice B) *HER2*, an oncogene encoding for an epidermal growth factor receptor, is amplified or overexpressed in many forms of invasive breast cancer. Treatment of the *HER2* gene product can improve outcomes in these individuals.

(Choice C) Activating mutations in the *KRAS* proto-oncogene are common in colorectal cancer and non-small cell lung cancer. *KRAS* encodes for a GTPase that relays cellular growth and proliferation signals from outside the cell.

(Choice E) Germ-line mutations of the *RET* proto-oncogene cause multiple endocrine neoplasia type 2, which is associated with pheochromocytoma, medullary thyroid cancer, parathyroid hyperplasia, and/or mucosal neuromas.

Educational objective:
Osteosarcoma is the most common primary bone malignancy in children and young adults. It occurs most frequently at the metaphyses of long bones and presents with local pain and swelling. Most cases are associated with sporadic or inherited mutations in *RB1* (hereditary retinoblastoma) and *TP53* (Li-Fraumeni syndrome).

References

- Understanding the osteosarcoma pathobiology: a comparative oncology approach.

Pathology	Hematology & Oncology	Bone tumor
Subject	System	Topic

Copyright © UWorld. All rights reserved.

1
2
3
4
5
6
7
8
9
10
11
12
13
14
15
16
17
18
19
20
21
22
23
24
25
26
27
28
29
30

A 72-year-old man comes to the office due to progressive weakness, fatigue, anorexia, and a 10-kg (22-lb) weight loss over the past 4 months. He says that food doesn't taste as good as it once did, and he feels full after eating only a small amount. The patient has had a morning cough for the past several years and had streaks of blood in his sputum 2 weeks ago. He has a 50-pack-year smoking history. On examination, the patient appears frail with a sunken face and bitemporal wasting. His arms are thin with notable muscle wasting. Lung examination reveals wheezing on the right side. Chest x-ray reveals an irregular right perihilar mass. Which of the following is most likely contributing to this patient's muscle wasting?

A. Calcium channel autoantibody
B. Interferon-α
C. Interleukin-3
D. Transforming growth factor-β
E. Tumor necrosis factor-α
F. Vasopressin

Submit

A 72-year-old man comes to the office due to progressive weakness, fatigue, anorexia, and a 10-kg (22-lb) weight loss over the past 4 months. He says that food doesn't taste as good as it once did, and he feels full after eating only a small amount. The patient has had a morning cough for the past several years and had streaks of blood in his sputum 2 weeks ago. He has a 50-pack-year smoking history. On examination, the patient appears frail with a sunken face and bitemporal wasting. His arms are thin with notable muscle wasting. Lung examination reveals wheezing on the right side. Chest x-ray reveals an irregular right perihilar mass. Which of the following is most likely contributing to this patient's muscle wasting?

- A. Calcium channel autoantibody (13%)
- B. Interferon-α (5%)
- C. Interleukin-3 (1%)
- D. Transforming growth factor-β (6%)
- ✓ E. Tumor necrosis factor-α (71%)
- F. Vasopressin (1%)

Omitted
Correct answer
E

71%
Answered correctly

02 secs
Time Spent

06/13/2020
Last Updated

Explanation

Cachexia is a syndrome that encompasses anorexia, malaise, anemia, weight loss, and generalized **wasting** due to underlying systemic disease. Cachexia in this patient is likely a manifestation of the lung **neoplasm** revealed on his chest x-ray. **Tumor necrosis factor-α** (TNF-α) is

1 2 3 4 5 6 7 8 9 10 11 12 13 14 15 16 17 18 19 20 21 22 23 24 25 26 27 28 29 30

Cachexia is a syndrome that encompasses anorexia, malaise, anemia, weight loss, and generalized **wasting** due to underlying systemic disease. Cachexia in this patient is likely a manifestation of the lung **neoplasm** revealed on his chest x-ray. **Tumor necrosis factor-α** (TNF-α) is a cytokine that causes necrosis of some tumors in vitro and produces symptoms of cachexia in experimental animals. TNF-α is also called cachectin and is considered a main mediator of paraneoplastic cachexia (along with interleukin [IL]-1β, and IL-6).

TNF-α is produced by macrophages in response to infection as well as by some neoplastic cells. Its role in cachexia is explained by its influence on the hypothalamus, leading to appetite suppression. It also increases basal metabolic rate. In bacterial infections, TNF-α produces fever (along with IL-1), mediates many of the symptoms of septic shock, and causes hepatic release of acute-phase reactants (eg, C-reactive protein and fibrinogen).

(Choice A) Eaton-Lambert syndrome is a paraneoplastic condition that manifests as progressive, symmetric proximal muscle weakness (rather than wasting) along with ocular and autonomic symptoms. It is due to autoantibodies to voltage-gated calcium channels.

(Choice B) Interferon-α is synthesized by leukocytes and has antiviral as well as anti-tumor activity.

(Choice C) IL-3 is produced by activated CD4+ T_H cells. It stimulates growth and differentiation of myeloid cells.

(Choice D) The main function of transforming growth factor-β is inhibition of the inflammatory response. It decreases T cell proliferation and cytokine production.

(Choice F) Production of vasopressin by some tumors (eg, small cell lung cancer) results in the syndrome of inappropriate antidiuretic hormone secretion.

Educational objective:
Tumor necrosis factor-α is thought to mediate paraneoplastic cachexia in humans by suppressing appetite and increasing basal metabolic rate.

Pathology	Hematology & Oncology	Cancer anorexia cachexia syndrome
Subject	System	Topic

Copyright © UWorld. All rights reserved.

1
2
3
4
5
6
7
8
9
10
11
12
13
14
15
16
17
18
19
20
21
22
23
24
25
26
27
28
29
30

A 68-year-old man comes to the office due to persistent back pain for the past several months. He is a retired veteran and has not seen a doctor for many years. He has smoked a pack of cigarettes daily for 36 years. His blood pressure is 145/85 mm Hg and pulse is 88/min and regular. Cardiopulmonary examination is unremarkable. The abdomen is soft and nontender. There is focal tenderness over the 10th rib and L1-L2 vertebral region. Neurologic examination is normal. Radionuclide bone imaging reveals increased activity in multiple vertebrae and ribs, corresponding to the patient's painful areas. Routine radiographs show sclerotic lesions matching the bone scan areas of increased uptake, which are highly suspicious for metastatic cancer. Which of the following additional findings is most likely to be seen in this patient?

A. Hematuria and polycythemia

B. Monoclonal immunoglobulin spike

C. Lung mass and elevated parathyroid hormone-related peptide

D. Lymphadenopathy and BCL-2 overexpression

E. Nodular prostate and elevated prostate-specific antigen level

F. Rapidly enlarging, large, irregular mole

Submit

A 68-year-old man comes to the office due to persistent back pain for the past several months. He is a retired veteran and has not seen a doctor for many years. He has smoked a pack of cigarettes daily for 36 years. His blood pressure is 145/85 mm Hg and pulse is 88/min and regular. Cardiopulmonary examination is unremarkable. The abdomen is soft and nontender. There is focal tenderness over the 10th rib and L1-L2 vertebral region. Neurologic examination is normal. Radionuclide bone imaging reveals increased activity in multiple vertebrae and ribs, corresponding to the patient's painful areas. Routine radiographs show sclerotic lesions matching the bone scan areas of increased uptake, which are highly suspicious for metastatic cancer. Which of the following additional findings is most likely to be seen in this patient?

- A. Hematuria and polycythemia (2%)
- B. Monoclonal immunoglobulin spike (18%)
- C. Lung mass and elevated parathyroid hormone-related peptide (12%)
- D. Lymphadenopathy and BCL-2 overexpression (1%)
- ✓ E. Nodular prostate and elevated prostate-specific antigen level (64%)
- F. Rapidly enlarging, large, irregular mole (0%)

Omitted
Correct answer
E

64%
Answered correctly

02 secs
Time Spent

04/26/2020
Last Updated

Explanation

Bone metastases

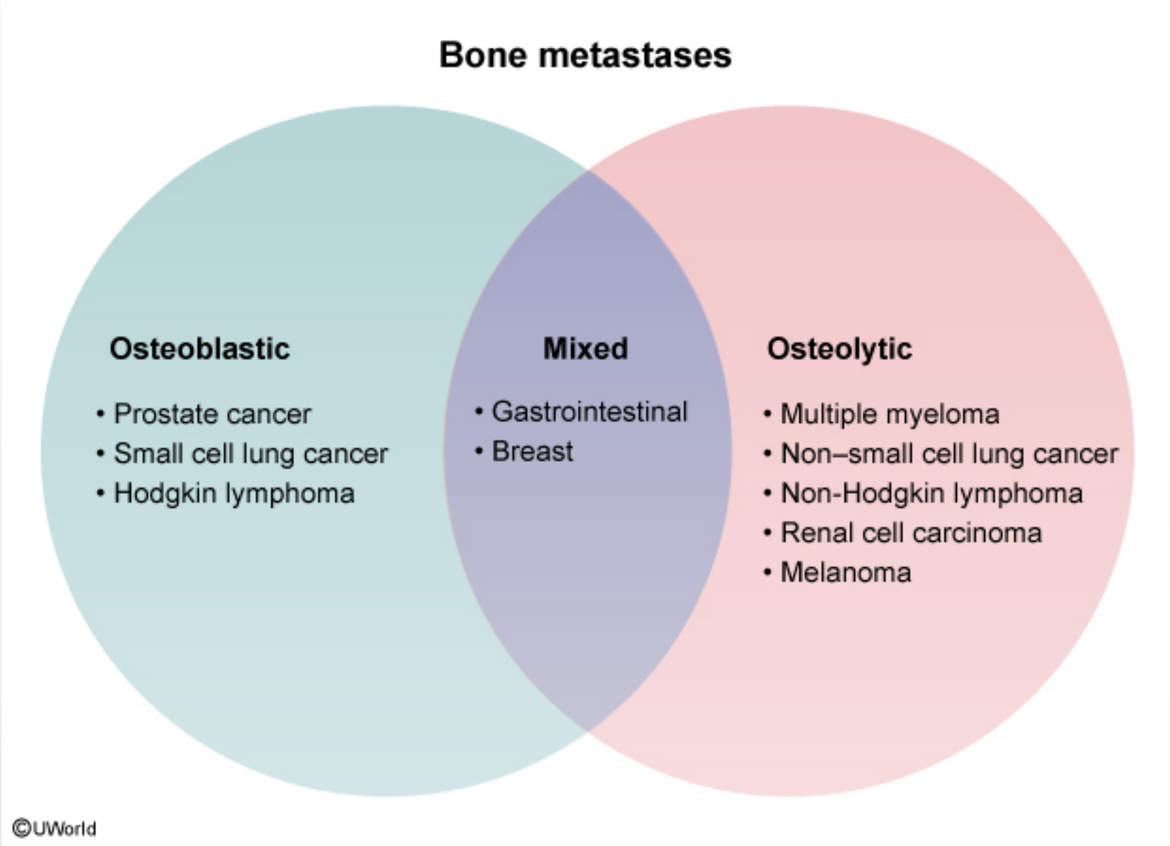

This patient with sclerotic bony metastases most likely has prostate cancer. Imaging of **bone metastases** assists in cancer diagnosis, as it allows the lesions to be characterized as:

- **Osteolytic (lucent):** Due to osteoclast stimulation, tend to represent aggressive cancer
- **Osteoblastic (sclerotic):** Due to osteoblasts, indicates a more indolent course

Metastatic **prostate cancer** commonly has **osteoblastic** (sclerotic) bone lesions. Bone pain is a typical clinical presentation; other symptoms include cancer cachexia and urinary symptoms (which are not always present). Prostate cancer is the most common non-skin cancer in men, and

This patient with sclerotic bony metastases most likely has prostate cancer. Imaging of **bone metastases** assists in cancer diagnosis, as it allows the lesions to be characterized as:

- **Osteolytic (lucent):** Due to osteoclast stimulation, tend to represent aggressive cancer
- **Osteoblastic (sclerotic):** Due to osteoblasts, indicates a more indolent course

Metastatic **prostate cancer** commonly has **osteoblastic** (sclerotic) bone lesions. Bone pain is a typical clinical presentation; other symptoms include cancer cachexia and urinary symptoms (which are not always present). Prostate cancer is the most common non-skin cancer in men, and African American men are at highest risk. An irregular prostate gland on digital rectal examination is suggestive of the diagnosis, which is then confirmed by biopsy. The prostate-specific antigen tumor marker is commonly elevated.

(Choice A) Hematuria and polycythemia (due to erythropoietin release) are suggestive of renal cell cancer. Renal cell cancer bone metastases are commonly osteolytic.

(Choice B) Monoclonal immunoglobulin spikes are found in multiple myeloma. Myeloma cells suppress osteoblasts and would cause osteolytic lesions, which are not present in this patient. Patients commonly have bone pain, recurrent infections, and symptoms of anemia.

(Choice C) Elevated parathyroid hormone-related peptide (PTH-rP) levels can occur with non-small cell lung cancer (NSCLC) and are associated with symptoms of hypercalcemia (confusion, abdominal pain, bony pain). Osteolytic bone lesions would be seen in NSCLC.

(Choice D) Lymphadenopathy and BCL-2 overexpression are found in lymphomas. BCL-2 is an anti-apoptosis factor, and overexpression plays a role in resistance to chemotherapy. Common manifestations of lymphoma also include night sweats, weight loss, and fatigue.

(Choice F) A rapidly enlarging irregular mole is suggestive of a melanoma. The liver, bone, and brain are the most common metastatic sites. Melanoma causes lytic bone lesions.

Educational objective:
Imaging of bone metastases assists in cancer diagnosis. Bone metastases are characterized as osteolytic or osteoblastic. Bony pain in an older man with osteoblastic lesions on imaging is highly suspicious for prostate cancer.

References

- Mechanism of bone metastasis.

African American men are at highest risk. An irregular prostate gland on digital rectal examination is suggestive of the diagnosis, which is then confirmed by biopsy. The prostate-specific antigen tumor marker is commonly elevated.

(Choice A) Hematuria and polycythemia (due to erythropoietin release) are suggestive of renal cell cancer. Renal cell cancer bone metastases are commonly osteolytic.

(Choice B) Monoclonal immunoglobulin spikes are found in multiple myeloma. Myeloma cells suppress osteoblasts and would cause osteolytic lesions, which are not present in this patient. Patients commonly have bone pain, recurrent infections, and symptoms of anemia.

(Choice C) Elevated parathyroid hormone-related peptide (PTH-rP) levels can occur with non-small cell lung cancer (NSCLC) and are associated with symptoms of hypercalcemia (confusion, abdominal pain, bony pain). Osteolytic bone lesions would be seen in NSCLC.

(Choice D) Lymphadenopathy and BCL-2 overexpression are found in lymphomas. BCL-2 is an anti-apoptosis factor, and overexpression plays a role in resistance to chemotherapy. Common manifestations of lymphoma also include night sweats, weight loss, and fatigue.

(Choice F) A rapidly enlarging irregular mole is suggestive of a melanoma. The liver, bone, and brain are the most common metastatic sites. Melanoma causes lytic bone lesions.

Educational objective:
Imaging of bone metastases assists in cancer diagnosis. Bone metastases are characterized as osteolytic or osteoblastic. Bony pain in an older man with osteoblastic lesions on imaging is highly suspicious for prostate cancer.

References

- Mechanism of bone metastasis.
- Bone metastasis: mechanism and therapeutic opportunities.

Pathology	Hematology & Oncology	Prostate cancer
Subject	System	Topic

Copyright © UWorld. All rights reserved.

1
2
3
4
5
6
7
8
9
10
11
12
13
14
15
16
17
18
19
20
21
22
23
24
25
26
27
28
29
30

A 34-year-old woman comes to the office due to vague abdominal pain over the past several months. She has no significant past medical history. The patient does not use tobacco or alcohol. Temperature is 36.7 C (98.1 F). On physical examination, right upper quadrant fullness is present. Abdominal imaging reveals a dense liver mass. Angiography shows a well-demarcated, highly vascularized tumor surrounded by normal liver parenchyma. Which of the following substances most likely contributed the most to blood vessel development in this patient's tumor?

A. Epidermal growth factor

B. Fibroblast growth factor

C. Insulin-like growth factor 1

D. Interferon-γ

E. Interleukin-1

Submit

A 34-year-old woman comes to the office due to vague abdominal pain over the past several months. She has no significant past medical history. The patient does not use tobacco or alcohol. Temperature is 36.7 C (98.1 F). On physical examination, right upper quadrant fullness is present. Abdominal imaging reveals a dense liver mass. Angiography shows a well-demarcated, highly vascularized tumor surrounded by normal liver parenchyma. Which of the following substances most likely contributed the most to blood vessel development in this patient's tumor?

- A. Epidermal growth factor (34%)
- ✓ B. Fibroblast growth factor (53%)
- C. Insulin-like growth factor 1 (9%)
- D. Interferon-γ (1%)
- E. Interleukin-1 (1%)

Omitted
Correct answer
B

53%
Answered correctly

01 sec
Time Spent

04/25/2020
Last Updated

Explanation

This patient has a highly vascularized liver tumor, possibly a benign hepatic hemangioma. Many cases are discovered incidentally.

Angiogenesis (blood vessel formation) is predominantly driven by the following 2 substances:

- **Vascular endothelial growth factor** (VEGF): VEGF stimulates angiogenesis in a variety of tissues (normal, chronically inflamed, healing, or neoplastic). As VEGF increases endothelial cell motility and proliferation, new capillaries begin to sprout.
- **Fibroblast growth factor** (FGF): FGF-2 is produced by a wide range of cells and is involved in endothelial cell proliferation, migration, and

This patient has a highly vascularized liver tumor, possibly a benign hepatic hemangioma. Many cases are discovered incidentally.

Angiogenesis (blood vessel formation) is predominantly driven by the following 2 substances:

- **Vascular endothelial growth factor** (VEGF): VEGF stimulates angiogenesis in a variety of tissues (normal, chronically inflamed, healing, or neoplastic). As VEGF increases endothelial cell motility and proliferation, new capillaries begin to sprout.
- **Fibroblast growth factor** (FGF): FGF-2 is produced by a wide range of cells and is involved in endothelial cell proliferation, migration, and differentiation. FGF-2 also appears to play an important role in embryogenesis by stimulating angioblast production. As a group, FGFs not only contribute to angiogenesis, but also to embryonic development, hematopoiesis, and wound repair (by recruiting macrophages, fibroblasts, and endothelial cells to damaged tissues).

However, the laminin in basement membranes may pose a physical barrier to the sprouting of new blood vessels.

(Choice A) Epidermal growth factor (EGF), not to be confused with VEGF, has a mitogenic influence on epithelial cells, hepatocytes, and fibroblasts. EGF does not appear to play as important a role in angiogenesis as VEGF or FGF-2.

(Choice C) Insulin-like growth factor 1 (IGF-1), or somatomedin C, is synthesized predominantly by growth hormone-influenced hepatocytes and serves to stimulate cell growth and multiplication. IGF-1 does not appear to directly stimulate angiogenesis, but it can indirectly promote it by encouraging cell growth.

(Choices D and E) Although the proinflammatory nature of interleukin-1 (IL-1) can induce the release of other proinflammatory cytokines that trigger cellular VEGF expression, IL-1 does not appear to directly stimulate angiogenesis. Similarly, although interferon-γ can indirectly promote neovascularization through activation of macrophages (can release VEGF), it does not appear to directly stimulate angiogenesis.

Educational objective:
The key growth factors that promote angiogenesis in neoplastic and granulation tissue are vascular endothelial growth factor (VEGF) and fibroblast growth factor. Proinflammatory cytokines (eg, interleukin-1, interferon-γ) can indirectly promote angiogenesis through increased VEGF expression. The laminin in basement membranes may pose a physical barrier to the sprouting of new blood vessels.

Pathology	Hematology & Oncology	Hemangioma
Subject	System	Topic

- **Vascular endothelial growth factor** (VEGF): VEGF stimulates angiogenesis in a variety of tissues (normal, chronically inflamed, healing, or neoplastic). As VEGF increases endothelial cell motility and proliferation, new capillaries begin to sprout.
- **Fibroblast growth factor** (FGF): FGF-2 is produced by a wide range of cells and is involved in endothelial cell proliferation, migration, and differentiation. FGF-2 also appears to play an important role in embryogenesis by stimulating angioblast production. As a group, FGFs not only contribute to angiogenesis, but also to embryonic development, hematopoiesis, and wound repair (by recruiting macrophages, fibroblasts, and endothelial cells to damaged tissues).

However, the laminin in basement membranes may pose a physical barrier to the sprouting of new blood vessels.

(Choice A) Epidermal growth factor (EGF), not to be confused with VEGF, has a mitogenic influence on epithelial cells, hepatocytes, and fibroblasts. EGF does not appear to play as important a role in angiogenesis as VEGF or FGF-2.

(Choice C) Insulin-like growth factor 1 (IGF-1), or somatomedin C, is synthesized predominantly by growth hormone-influenced hepatocytes and serves to stimulate cell growth and multiplication. IGF-1 does not appear to directly stimulate angiogenesis, but it can indirectly promote it by encouraging cell growth.

(Choices D and E) Although the proinflammatory nature of interleukin-1 (IL-1) can induce the release of other proinflammatory cytokines that trigger cellular VEGF expression, IL-1 does not appear to directly stimulate angiogenesis. Similarly, although interferon-γ can indirectly promote neovascularization through activation of macrophages (can release VEGF), it does not appear to directly stimulate angiogenesis.

Educational objective:
The key growth factors that promote angiogenesis in neoplastic and granulation tissue are vascular endothelial growth factor (VEGF) and fibroblast growth factor. Proinflammatory cytokines (eg, interleukin-1, interferon-γ) can indirectly promote angiogenesis through increased VEGF expression. The laminin in basement membranes may pose a physical barrier to the sprouting of new blood vessels.

Pathology	Hematology & Oncology	Hemangioma
Subject	System	Topic

Copyright © UWorld. All rights reserved.

A 35-year-old woman comes to the physician complaining of weakness, fatigue, and pallor. She denies heavy menses or melena. Physical examination is unremarkable except for conjunctival pallor. Laboratory results are as follows:

Complete blood count	
Hemoglobin	7.2 g/dL
Erythrocyte count	1.8 million/μL
Mean corpuscular volume	90 fL
Reticulocytes	0.1%
Platelets	280,000 /μL
Leukocyte count	6,700 cells/μL

Iron studies and serum B_{12} and folic acid levels are within normal limits. Bone marrow biopsy shows absence of erythroid precursors but preserved myeloid and megakaryocytic elements. Further workup would most likely show which of the following?

A. Hepatocellular carcinoma
B. Renal cell carcinoma
C. Thymic tumor
D. Cerebellar hemangioblastoma
E. Uterine fibroid

Submit

A 35-year-old woman comes to the physician complaining of weakness, fatigue, and pallor. She denies heavy menses or melena. Physical examination is unremarkable except for conjunctival pallor. Laboratory results are as follows:

Complete blood count	
Hemoglobin	7.2 g/dL
Erythrocyte count	1.8 million/μL
Mean corpuscular volume	90 fL
Reticulocytes	0.1%
Platelets	280,000 /μL
Leukocyte count	6,700 cells/μL

Iron studies and serum B_{12} and folic acid levels are within normal limits. Bone marrow biopsy shows absence of erythroid precursors but preserved myeloid and megakaryocytic elements. Further workup would most likely show which of the following?

A. Hepatocellular carcinoma
B. Renal cell carcinoma
C. Thymic tumor
D. Cerebellar hemangioblastoma
E. Uterine fibroid

Submit

A 35-year-old woman comes to the physician complaining of weakness, fatigue, and pallor. She denies heavy menses or melena. Physical examination is unremarkable except for conjunctival pallor. Laboratory results are as follows:

Complete blood count	
Hemoglobin	7.2 g/dL
Erythrocyte count	1.8 million/μL
Mean corpuscular volume	90 fL
Reticulocytes	0.1%
Platelets	280,000 /μL
Leukocyte count	6,700 cells/μL

Iron studies and serum B_{12} and folic acid levels are within normal limits. Bone marrow biopsy shows absence of erythroid precursors but preserved myeloid and megakaryocytic elements. Further workup would most likely show which of the following?

A. Hepatocellular carcinoma (10%)
B. Renal cell carcinoma (53%)
✓ C. Thymic tumor (23%)
D. Cerebellar hemangioblastoma (6%)
E. Uterine fibroid (5%)

Omitted
Correct answer

23%
Answered correctly

03 secs
Time Spent

03/02/2020
Last Updated

1 2 3 4 5 6 7 8 9 10 11 12 13 14 15 16 17 18 19 20 21 22 23 24 25 26 27 28 29 30

This patient's pallor and fatigue suggest that she is suffering from anemia, which is confirmed by her low erythrocyte count, low percentage of reticulocytes (decreased RBC production), and low hemoglobin. Importantly, her white blood cell and platelet counts are within normal limits and their bone marrow precursors appear normal as well. The most likely diagnosis is pure red cell aplasia (PRCA), a rare form of marrow failure characterized by severe hypoplasia of marrow erythroid elements in the setting of normal granulopoiesis and thrombopoiesis.

The pathogenesis of PRCA often involves the inhibition of erythropoietic precursors and progenitors by IgG autoantibodies or cytotoxic T lymphocytes. It has been associated with immune system diseases such as thymomas and lymphocytic leukemias. When a thymoma is present, removal can occasionally cure PRCA. Thus, all patients with PRCA should undergo a chest CT scan. PRCA can also result from parvovirus B19 infection. This virus preferentially attacks and destroys proerythroblasts. Recent parvovirus infection can be confirmed via the detection of anti-B19 IgM antibodies in the serum.

(Choice A) Hepatocellular carcinoma (HCC) can cause anemia of chronic disease, in which the total iron binding capacity is low. However, this patient's iron studies are within normal limits. HCC tumors may also secrete erythropoietin, although polycythemia is less common.

(Choice B) Renal cell carcinoma (RCC) can cause both anemia of chronic disease and iron deficiency anemia due to chronic hematuria. Some renal cell tumors can produce erythropoietin and cause polycythemia. Thus, anemia, polycythemia, or normal hemoglobin may be present in the setting of RCC. However, selective absence of erythroid precursors in the bone marrow would not occur with RCC. In addition, RCC is rare in younger patients, whereas benign thymomas are more common.

(Choice D) Cerebellar hemangioblastomas can produce erythropoietin and are often associated with polycythemia.

(Choice E) Uterine fibroids can cause bleeding and may result in microcytic hypochromic anemia with iron studies showing low iron and increased total iron binding capacity. However, fibroids can also produce erythropoietin and can cause polycythemia.

Educational objective:
Pure red cell aplasia is a rare form of marrow failure characterized by severe hypoplasia of marrow erythroid elements in the setting of normal granulopoiesis and thrombopoiesis. Pure red cell aplasia is associated with thymoma, lymphocytic leukemias, and parvovirus B19 infection.

Pathology	Hematology & Oncology	Pure red cell aplasia
Subject	System	Topic

1
2
3
4
5
6
7
8
9
10
11
12
13
14
15
16
17
18
19
20
21
22
23
24
25
26
27
28
29
30

A 73-year-old man comes to the office due to blood in his urine. He has noted bright red blood at the end of micturition on several occasions but has had no urinary frequency or pain with urination. The patient has a history of hypertension and chronic bronchitis. He has smoked a pack of cigarettes daily for 30 years. Temperature is 37 C (98.6 F). Abdominal, external genital, and rectal examinations are unremarkable. Urinalysis shows hematuria. Urine cytology is positive for malignant cells. Cystoscopy is planned for visualization and biopsy of suspected urinary tract cancer. Which of the following features would be most suggestive of a poor prognosis?

- A. High-grade intraepithelial lesion
- B. Involvement of the muscular layer
- C. Location at the anterior bladder wall
- D. Papillary morphology
- E. Tumor size >2 cm

Submit

A 73-year-old man comes to the office due to blood in his urine. He has noted bright red blood at the end of micturition on several occasions but has had no urinary frequency or pain with urination. The patient has a history of hypertension and chronic bronchitis. He has smoked a pack of cigarettes daily for 30 years. Temperature is 37 C (98.6 F). Abdominal, external genital, and rectal examinations are unremarkable. Urinalysis shows hematuria. Urine cytology is positive for malignant cells. Cystoscopy is planned for visualization and biopsy of suspected urinary tract cancer. Which of the following features would be most suggestive of a poor prognosis?

- A. High-grade intraepithelial lesion (9%)
- ✓ B. Involvement of the muscular layer (77%)
- C. Location at the anterior bladder wall (3%)
- D. Papillary morphology (4%)
- E. Tumor size >2 cm (5%)

Omitted
Correct answer
B

77%
Answered correctly

01 sec
Time Spent

03/31/2020
Last Updated

Explanation

This patient with a significant smoking history has developed painless gross hematuria, which raises suspicion for bladder cancer. **Urothelial (transitional cell) carcinomas** arising from the transitional epithelium lining the bladder are the most common type of bladder cancer; squamous cell and adenocarcinomas may occur but are significantly less common. Urothelial cancer typically grows as an erythematous papillary, nodular, or sessile mass and is easily diagnosed on cystoscopy. Microscopy may show cells resembling normal bladder epithelium but with irregular architecture, pleomorphism, hyperchromatic nuclei, and atypical mitoses

This patient with a significant smoking history has developed painless gross hematuria, which raises suspicion for bladder cancer. **Urothelial (transitional cell) carcinomas** arising from the transitional epithelium lining the bladder are the most common type of bladder cancer; squamous cell and adenocarcinomas may occur but are significantly less common. Urothelial cancer typically grows as an erythematous papillary, nodular, or sessile mass and is easily diagnosed on cystoscopy. Microscopy may show cells resembling normal bladder epithelium but with irregular architecture, pleomorphism, hyperchromatic nuclei, and atypical mitoses.

Tumor stage is the most important factor for determining prognosis in urothelial carcinoma and is based on the **depth of invasion** into the bladder wall and the degree of spread to other tissues. Tumor penetration through the mucosa and lamina propria **into the muscular layer** (indicating stage T2 or higher in the Tumor, Node, Metastasis [TNM] system) carries an **unfavorable prognosis**.

(Choice A) Tumor grade, or the degree of cellular abnormality, also influences prognosis but to a lesser extent than staging. High-grade intraepithelial lesions (carcinoma in situ), despite their high degree of cellular abnormality, have a relatively favorable prognosis as they have not invaded the basement membrane.

(Choice C) Urothelial tumors at the bladder neck may have an elevated risk of recurrence, but, in general, tumor location within the bladder has only a minor effect on prognosis.

(Choice D) Tumors with papillary morphology are more likely to extend into the bladder lumen rather than penetrate into the bladder wall. However, these tumors can become invasive, and papillary morphology itself does not directly influence prognosis.

(Choice E) Larger tumors are associated with worse prognosis; however, depth of tumor invasion is a much more important prognostic factor than tumor size.

Educational objective:
Urothelial (transitional cell) carcinoma is the most common type of bladder cancer. Tumor stage is the most important factor for determining prognosis and is based on the depth of invasion into the bladder wall and the degree of spread to other tissues. Tumor invasion into the muscular layer of the bladder wall carries an unfavorable prognosis.

References

- Diagnosis and staging of bladder cancer.

This patient with a significant smoking history has developed painless gross hematuria, which raises suspicion for bladder cancer. **Urothelial**

Exhibit Display

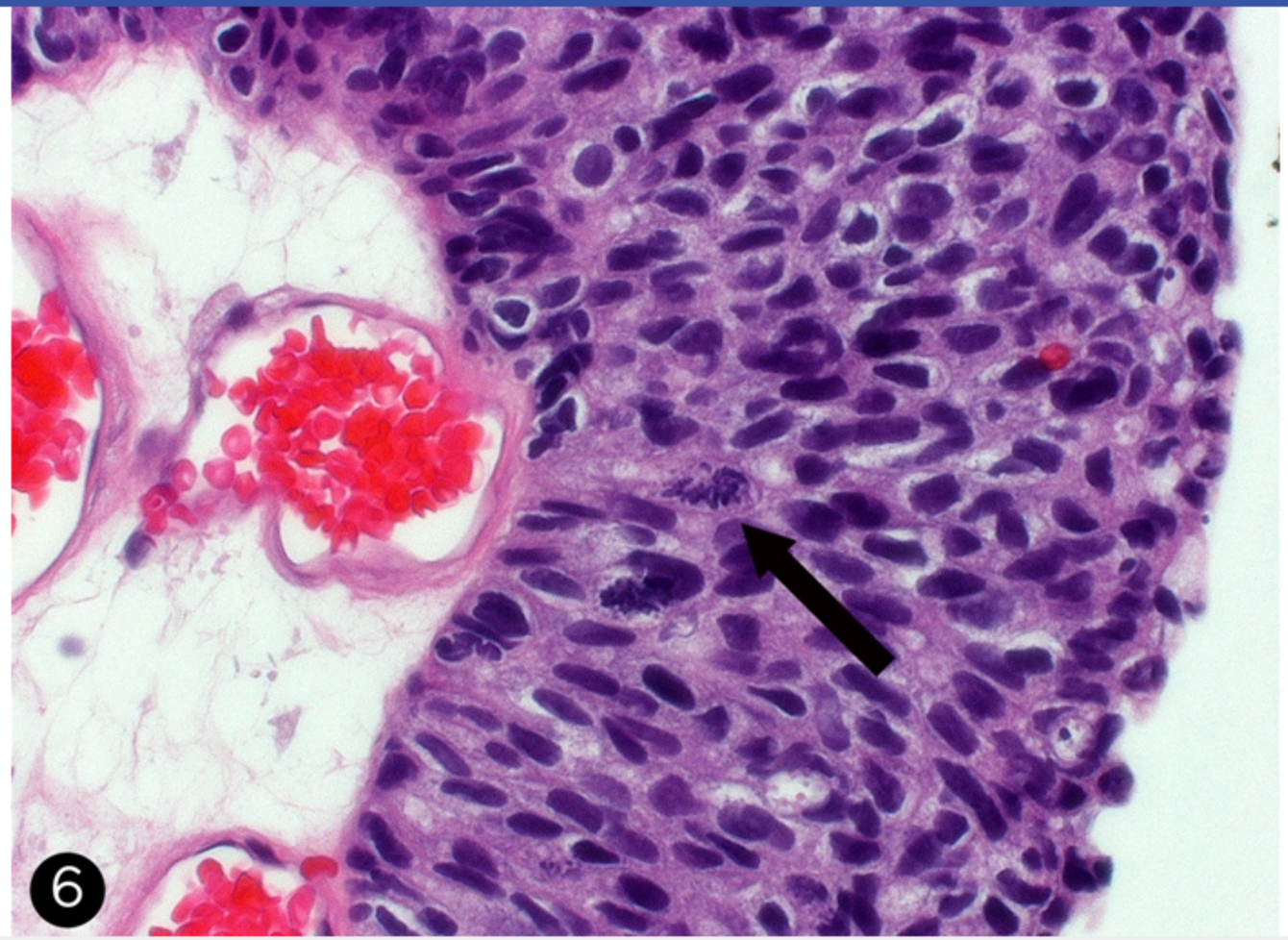

Zoom In | Zoom Out | Reset | Add To New Card | Existing Card

This patient with a significant smoking history has developed painless gross hematuria, which raises suspicion for bladder cancer. **Urothelial**

Exhibit Display

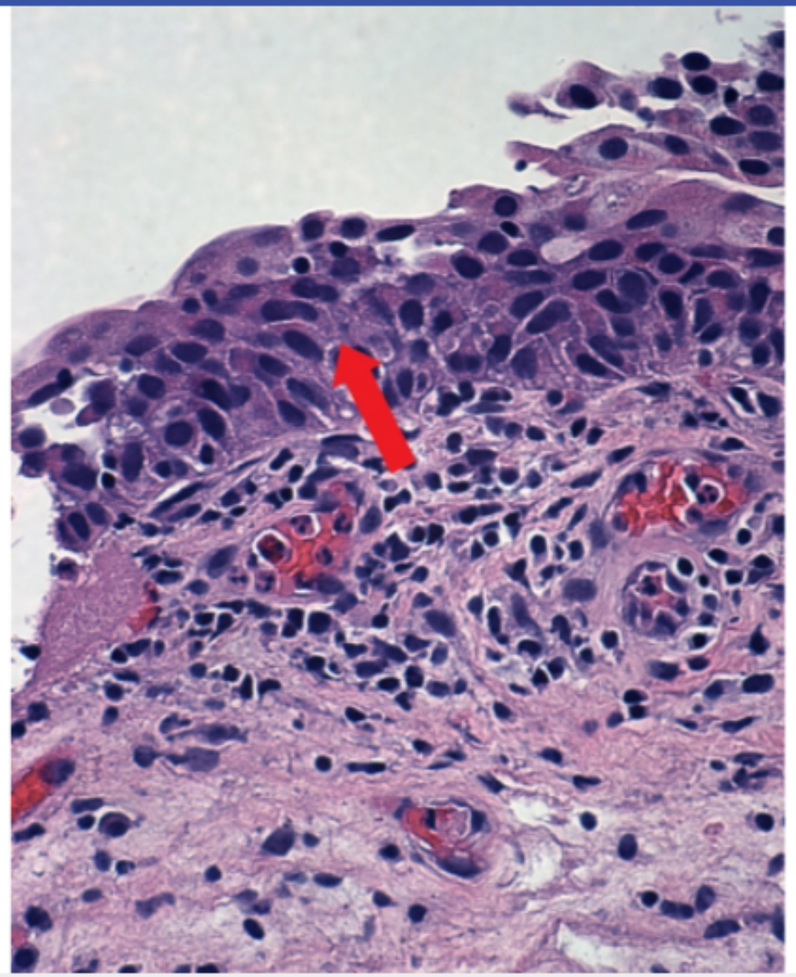

Zoom In | Zoom Out | Reset | Add To New Card | Existing Card

cell and adenocarcinomas may occur but are significantly less common. Urothelial cancer typically grows as an erythematous papillary, nodular, or sessile mass and is easily diagnosed on cystoscopy. Microscopy may show cells resembling normal bladder epithelium but with irregular architecture, pleomorphism, hyperchromatic nuclei, and atypical mitoses.

Tumor stage is the most important factor for determining prognosis in urothelial carcinoma and is based on the **depth of invasion** into the bladder wall and the degree of spread to other tissues. Tumor penetration through the mucosa and lamina propria **into the muscular layer** (indicating stage T2 or higher in the Tumor, Node, Metastasis [TNM] system) carries an **unfavorable prognosis**.

(Choice A) Tumor grade, or the degree of cellular abnormality, also influences prognosis but to a lesser extent than staging. High-grade intraepithelial lesions (carcinoma in situ), despite their high degree of cellular abnormality, have a relatively favorable prognosis as they have not invaded the basement membrane.

(Choice C) Urothelial tumors at the bladder neck may have an elevated risk of recurrence, but, in general, tumor location within the bladder has only a minor effect on prognosis.

(Choice D) Tumors with papillary morphology are more likely to extend into the bladder lumen rather than penetrate into the bladder wall. However, these tumors can become invasive, and papillary morphology itself does not directly influence prognosis.

(Choice E) Larger tumors are associated with worse prognosis; however, depth of tumor invasion is a much more important prognostic factor than tumor size.

Educational objective:
Urothelial (transitional cell) carcinoma is the most common type of bladder cancer. Tumor stage is the most important factor for determining prognosis and is based on the depth of invasion into the bladder wall and the degree of spread to other tissues. Tumor invasion into the muscular layer of the bladder wall carries an unfavorable prognosis.

References

- Diagnosis and staging of bladder cancer.

Pathology	Hematology & Oncology	Bladder cancer
Subject	System	Topic

A 12-year-old African American male is brought to the emergency room with high fever, chest pains, and dyspnea. His past medical history is significant for two prior hospitalizations for abdominal pain, which resolved with analgesics and hydration. Evaluation today reveals a hematocrit of 23% and reticulocyte count of 9%. Several hours after being admitted, the patient dies in the hospital. At autopsy, the patient's spleen is firm and brown; this finding is most likely related to:

- A. Work hypertrophy
- B. Follicular hyperplasia
- C. Vascular occlusion
- D. Pressure atrophy
- E. Dysplasia
- F. Lipid accumulation

Submit

A 12-year-old African American male is brought to the emergency room with high fever, chest pains, and dyspnea. His past medical history is significant for two prior hospitalizations for abdominal pain, which resolved with analgesics and hydration. Evaluation today reveals a hematocrit of 23% and reticulocyte count of 9%. Several hours after being admitted, the patient dies in the hospital. At autopsy, the patient's spleen is firm and brown; this finding is most likely related to:

- A. Work hypertrophy (17%)
- B. Follicular hyperplasia (2%)
- ✓ C. Vascular occlusion (73%)
- D. Pressure atrophy (4%)
- E. Dysplasia (0%)
- F. Lipid accumulation (1%)

Omitted
Correct answer
C

73%
Answered correctly

01 sec
Time Spent

02/03/2020
Last Updated

Explanation

In an African American patient with the hematologic findings described above and recurrent episodes of abdominal pain that resolve with hydration, sickle cell anemia is the most likely diagnosis. Today this patient has presented with symptoms of "acute chest syndrome" (ACS), which is vaso-occlusive crisis localized to the pulmonary vasculature that can occur in patients with sickle cell anemia. ACS is commonly precipitated by pulmonary infection.

Explanation

In an African American patient with the hematologic findings described above and recurrent episodes of abdominal pain that resolve with hydration, sickle cell anemia is the most likely diagnosis. Today this patient has presented with symptoms of "acute chest syndrome" (ACS), which is vaso-occlusive crisis localized to the pulmonary vasculature that can occur in patients with sickle cell anemia. ACS is commonly precipitated by pulmonary infection.

In patients with homozygous hemoglobin S disease, vaso-occlusive crises can also cause splenic infarctions. Repeated infarctions over time produce a spleen that is shrunken, discolored, and fibrotic. By the time they reach adulthood, most patients with sickle cell anemia have undergone "autosplenectomy" as a result of these infarcts and are left with only a small, scarred splenic remnant. The spleen may demonstrate brownish discoloration (hemosiderosis) due to extensive ingestion of sickled RBCs by splenic macrophages (extravascular hemolysis).

(Choices A and B) There may be hyperplasia and hypertrophy of normal splenic elements (especially macrophages and lymphoid cells) in systemic infections and various other disease states.

(Choice D) Pressure atrophy of the splenic parenchyma can be seen when there is a tumor infiltrating the spleen.

(Choice E) Dysplasia is disordered growth and/or abnormal hyperplasia of epithelia. This term is rarely applied to histologic components of the spleen.

(Choice F) Intrasplenic lipid accumulation might be seen in lysosomal lipid storage disorders like Gaucher's disease.

Educational Objective:
The major chronic pathologic changes in the spleens of patients with sickle cell anemia result from repetitive splenic infarctions caused by splenic microvessel occlusion. Fibrosis, brownish discoloration, and eventual autosplenectomy ultimately result.

Pathology	Hematology & Oncology	Sickle cell
Subject	System	Topic

Copyright © UWorld. All rights reserved.

A 56-year-old man is evaluated for increased fatigability. His past medical history is significant for diabetes mellitus, osteoarthritis, and severe aortic stenosis that required aortic valve replacement. His peripheral blood smear is shown on the slide below.

Which of the following laboratory findings is most likely to be seen in this patient?

1
2
3
4
5
6
7
8
9
10
11
12
13
14
15
16
17
18
19
20
21
22
23
24
25
26
27
28
29
30

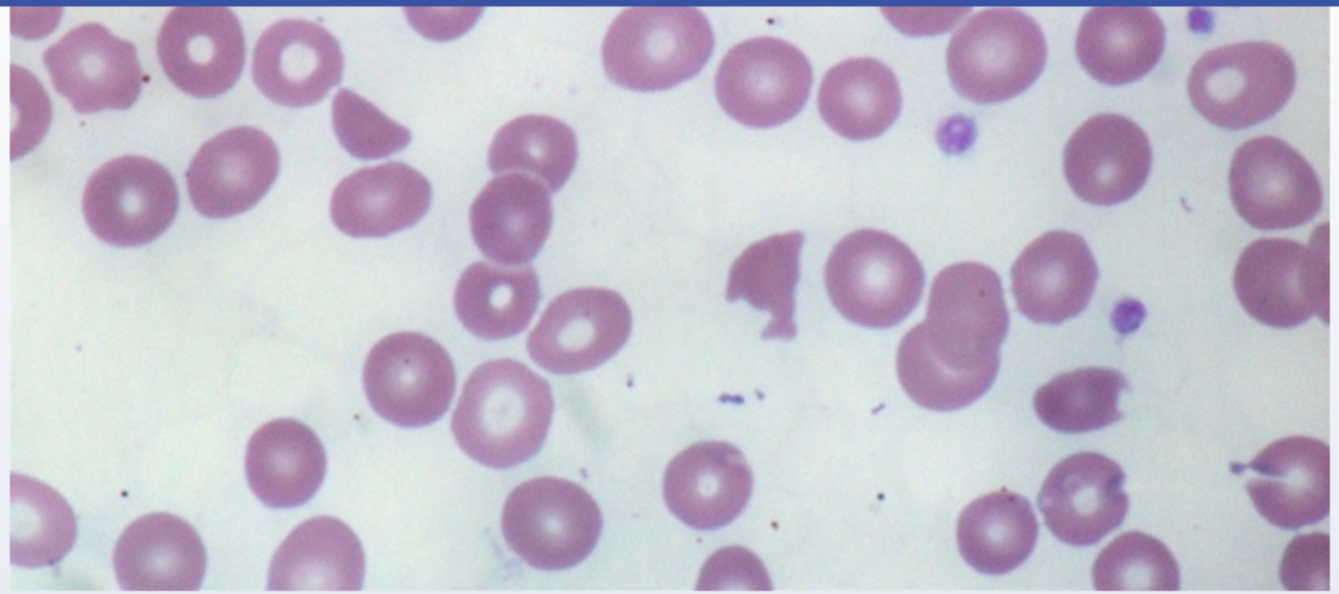

Which of the following laboratory findings is most likely to be seen in this patient?

A. Increased total serum iron level

B. Decreased serum haptoglobin level

C. Increased mean corpuscular volume

D. Decreased reticulocyte count

E. Decreased serum albumin level

Submit

1
2
3
4
5
6
7
8
9
10
11
12
13
14
15
16
17
18
19
20
21
22
23
24
25
26
27
28
29
30

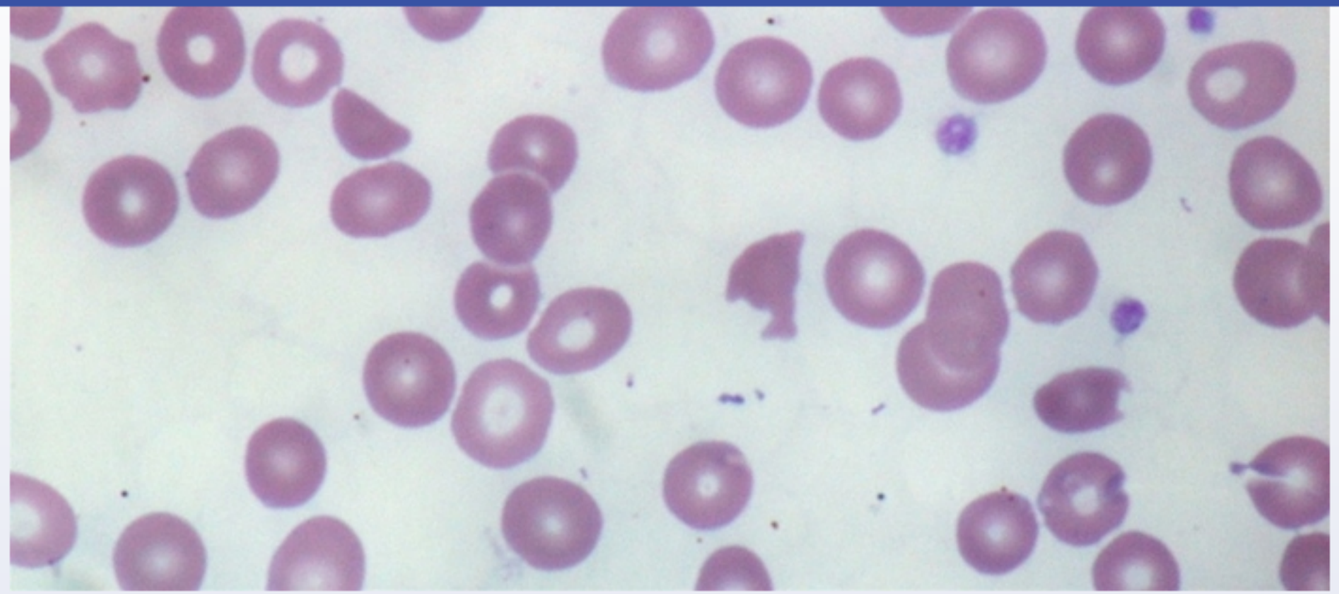

Which of the following laboratory findings is most likely to be seen in this patient?

- A. Increased total serum iron level (10%)
- ✓ B. Decreased serum haptoglobin level (76%)
- C. Increased mean corpuscular volume (6%)
- D. Decreased reticulocyte count (4%)
- E. Decreased serum albumin level (1%)

Omitted
Correct answer

76%
Answered correctly

08 secs
Time Spent

04/15/2020
Last Updated

1
2
3
4
5
6
7
8
9
10
11
12
13
14
15
16
17
18
19
20
21
22
23
24
25
26
27
28
29
30

Schistocytes

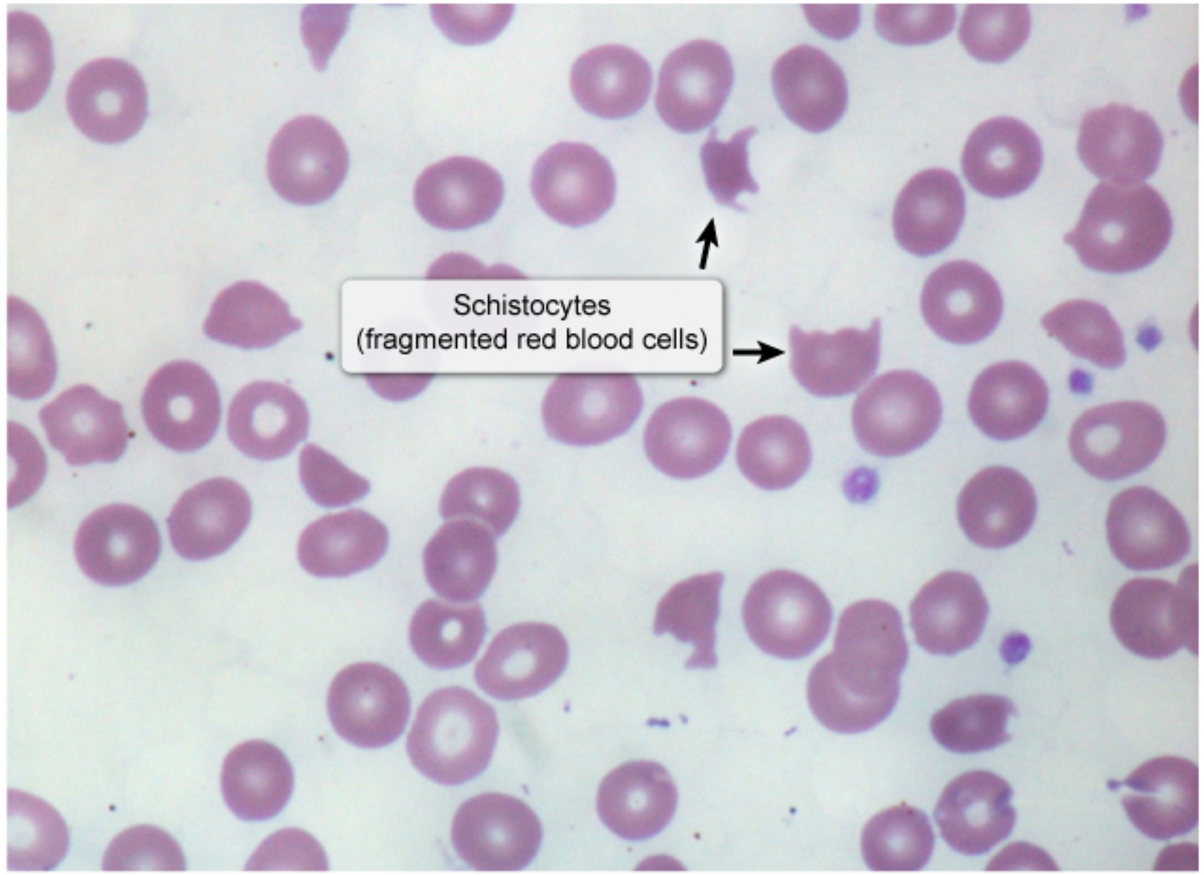

©UWorld

The fragmented erythrocytes shown on the slide above are called schistocytes or helmet cells. They are formed by mechanical trauma to erythrocytes as they circulate through the vasculature. This patient's schistocytes are most likely due to erythrocyte damage caused by his aortic valve prosthesis. Artificial (mechanical) valves are more traumatic for RBCs than porcine prostheses and frequently cause hemolysis.

The fragmented erythrocytes shown on the slide above are called schistocytes or helmet cells. They are formed by mechanical trauma to erythrocytes as they circulate through the vasculature. This patient's schistocytes are most likely due to erythrocyte damage caused by his aortic valve prosthesis. Artificial (mechanical) valves are more traumatic for RBCs than porcine prostheses and frequently cause hemolysis. Schistocytes can also be formed from narrowing of the vascular spaces due to fibrin strand formation, as seen in disseminated intravascular coagulation, hemolytic-uremic syndrome, and thrombotic thrombocytopenic purpura.

Hemolytic anemia due to intravascular erythrocyte destruction results in laboratory findings similar to those in other types of hemolytic anemias, including an increase in serum indirect bilirubin. Intravascular erythrocyte damage also results in free hemoglobin in serum (hemoglobinemia) and urine (hemoglobinuria) as well as increased serum lactate dehydrogenase (LDH). Haptoglobin is a serum protein that binds to free hemoglobin and promotes its uptake by the reticuloendothelial system. Haptoglobin levels decrease when significant quantities of hemoglobin are released into the circulation, as occurs with intravascular hemolysis.

(Choice A) Increased serum iron occurs in hemochromatosis most classically, but increased serum iron can also be iatrogenic. Hemochromatosis does not cause anemia, but it is associated with cirrhosis and increased incidence of hepatocellular cancer, skin darkening, and insulin resistance. Hemolysis does not usually have a significant effect on serum iron.

(Choice C) Increased mean corpuscular volume (MCV) is a sign of megaloblastic anemia, which is most frequently caused by folate or Vitamin B12 deficiency. The peripheral blood smear in megaloblastic anemia shows hypersegmented neutrophils and enlarged ovoid erythrocytes. In contrast, schistocytosis may cause decreased MCV due to small RBC fragments being erroneously counted by automated hematology machines (this counteracts any increase in MCV due to reticulocytosis).

(Choice D) A decreased reticulocyte count in the presence of anemia is characteristic of aplastic anemia. In hemolytic anemias, the reticulocyte count is increased to compensate for the increased destruction of RBCs.

(Choice E) A decreased serum albumin level is associated with cirrhosis (decreased production), nephrotic syndrome (urinary loss), and protein-wasting enteropathy (bowel loss).

Educational objective:
Schistocytes (helmet cells) are fragmented erythrocytes. They occur secondary to mechanical trauma from microangiopathic hemolytic anemias or prosthetic cardiac valves. Intravascular hemolytic anemias are characterized by decreased serum haptoglobin levels as well as increased LDH and bilirubin.

Hemolytic anemia due to intravascular erythrocyte destruction results in laboratory findings similar to those in other types of hemolytic anemias, including an increase in serum indirect bilirubin. Intravascular erythrocyte damage also results in free hemoglobin in serum (hemoglobinemia) and urine (hemoglobinuria) as well as increased serum lactate dehydrogenase (LDH). Haptoglobin is a serum protein that binds to free hemoglobin and promotes its uptake by the reticuloendothelial system. Haptoglobin levels decrease when significant quantities of hemoglobin are released into the circulation, as occurs with intravascular hemolysis.

(Choice A) Increased serum iron occurs in hemochromatosis most classically, but increased serum iron can also be iatrogenic. Hemochromatosis does not cause anemia, but it is associated with cirrhosis and increased incidence of hepatocellular cancer, skin darkening, and insulin resistance. Hemolysis does not usually have a significant effect on serum iron.

(Choice C) Increased mean corpuscular volume (MCV) is a sign of megaloblastic anemia, which is most frequently caused by folate or Vitamin B12 deficiency. The peripheral blood smear in megaloblastic anemia shows hypersegmented neutrophils and enlarged ovoid erythrocytes. In contrast, schistocytosis may cause decreased MCV due to small RBC fragments being erroneously counted by automated hematology machines (this counteracts any increase in MCV due to reticulocytosis).

(Choice D) A decreased reticulocyte count in the presence of anemia is characteristic of aplastic anemia. In hemolytic anemias, the reticulocyte count is increased to compensate for the increased destruction of RBCs.

(Choice E) A decreased serum albumin level is associated with cirrhosis (decreased production), nephrotic syndrome (urinary loss), and protein-wasting enteropathy (bowel loss).

Educational objective:
Schistocytes (helmet cells) are fragmented erythrocytes. They occur secondary to mechanical trauma from microangiopathic hemolytic anemias or prosthetic cardiac valves. Intravascular hemolytic anemias are characterized by decreased serum haptoglobin levels as well as increased LDH and bilirubin.

Pathology	Hematology & Oncology	Hemolytic anemia
Subject	System	Topic

Copyright © UWorld. All rights reserved.

Hemolytic anemia due to intravascular erythrocyte destruction results in laboratory findings similar to those in other types of hemolytic anemias, including an increase in serum indirect bilirubin. Intravascular erythrocyte damage also results in free hemoglobin in serum (hemoglobinemia) and

Exhibit Display

Megaloblastic anemia Megaloblastic anemia

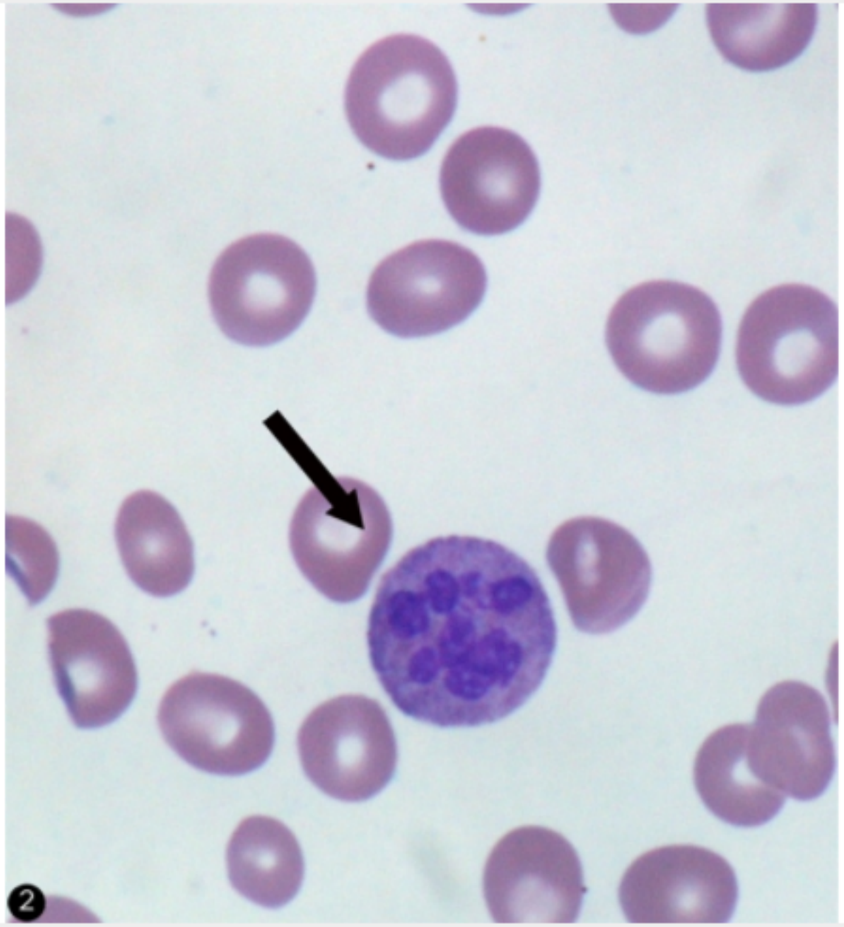

Zoom In Zoom Out Reset Add To New Card | Existing Card

Hemolytic anemia due to intravascular erythrocyte destruction results in laboratory findings similar to those in other types of hemolytic anemias, including an increase in serum indirect bilirubin. Intravascular erythrocyte damage also results in free hemoglobin in serum (hemoglobinemia) and

Exhibit Display

Megaloblastic anemia Megaloblastic anemia

Megaloblastic anemia

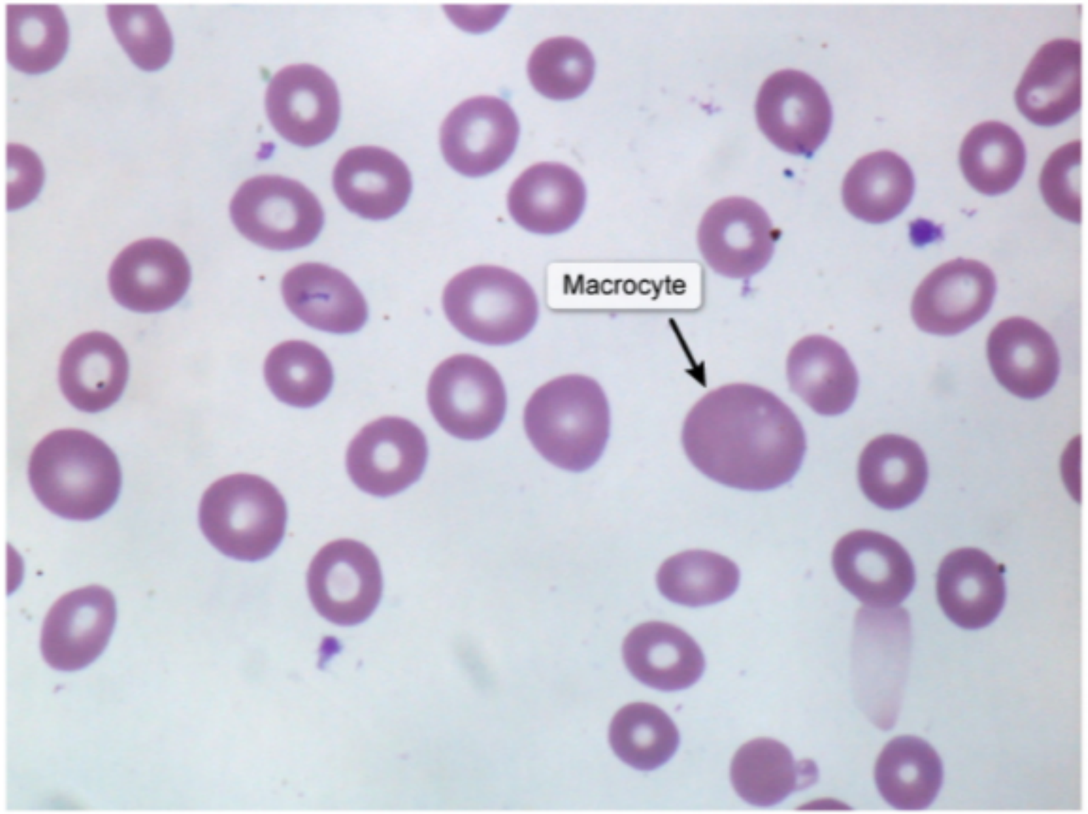

©UWorld

Zoom In Zoom Out Reset Add To New Card | Existing Card

1 2 3 4 5 6 7 8 9 10 11 12 13 14 15 16 17 18 19 20 21 22 23 24 25 26 27 28 29 30

1
2
3
4
5
6
7
8
9
10
11
12
13
14
15
16
17
18
19
20
21
22
23
24
25
26
27
28
29
30

A 68-year-old man with a long history of using chewing tobacco comes to the office for follow up of squamous cell carcinoma (SCC) of the oral cavity. A month ago, the patient was diagnosed with SCC of the left lateral tongue. He underwent resection, the surgical specimen showed clear margins, and he started additional treatment. The patient recently noticed a second ulcerative lesion on the right lateral tongue. Biopsy is performed and it also shows SCC. The second tumor most likely arose from which of the following mechanisms?

A. Chemotherapy-induced malignancy
B. Field cancerization
C. Hematogenous spread
D. Immunologic privilege
E. Impaired wound healing
F. Lymphatic spread

Submit

A 68-year-old man with a long history of using chewing tobacco comes to the office for follow up of squamous cell carcinoma (SCC) of the oral cavity. A month ago, the patient was diagnosed with SCC of the left lateral tongue. He underwent resection, the surgical specimen showed clear margins, and he started additional treatment. The patient recently noticed a second ulcerative lesion on the right lateral tongue. Biopsy is performed and it also shows SCC. The second tumor most likely arose from which of the following mechanisms?

- A. Chemotherapy-induced malignancy (3%)
- ✓ B. Field cancerization (57%)
- C. Hematogenous spread (9%)
- D. Immunologic privilege (3%)
- E. Impaired wound healing (1%)
- F. Lymphatic spread (23%)

Omitted
Correct answer
B

57%
Answered correctly

01 sec
Time Spent

02/24/2020
Last Updated

Explanation

This patient with mucosal head and neck squamous cell carcinoma (HNSCC) has developed a second primary tumor, which is common with HNSCC due to **field cancerization**.

Field cancerization describes a large area of cells within a field (eg, upper aerodigestive tract) that are "primed" to develop cancer because of **widespread exposure to mutagens** (eg, tobacco). Mutations that affect many similar cells can increase the likelihood of developing multiple

This patient with mucosal head and neck squamous cell carcinoma (HNSCC) has developed a second primary tumor, which is common with HNSCC due to **field cancerization**.

Field cancerization describes a large area of cells within a field (eg, upper aerodigestive tract) that are "primed" to develop cancer because of **widespread exposure to mutagens** (eg, tobacco). Mutations that affect many similar cells can increase the likelihood of developing multiple primary malignancies, analogous to germline mutations in tumor suppressor genes (eg, *BRCA1* or *BRCA2* in breast and ovarian cancer). Field cancerization likely underlies the development of many common cancers, including:

- HNSCC due to mucosal exposure to tobacco carcinogens
- Basal cell carcinoma of the skin due to skin exposure to ultraviolet light
- Colorectal carcinoma due to epithelial exposure to dietary carcinogens

Even with adequate treatment of a malignancy, the areas affected by field cancerization remain at higher risk of developing **multiple primary malignancies**, as seen in this patient. Therefore, patients diagnosed with any of these cancers require comprehensive evaluation and continued surveillance of the at-risk area (eg, colonoscopy, comprehensive skin examination, panendoscopy of the upper aerodigestive tract).

(Choice A) Chemotherapy can induce secondary malignancies, most commonly leukemia and lymphoma, in cancer survivors. In contrast to the tumors in this patient, secondary malignancies are seen years or even decades later.

(Choices C and F) Most carcinomas, including HNSCC, spread via the lymphatic system, leading to metastases in the regional (eg, ipsilateral anterior neck) lymph nodes. However, it is unlikely for the carcinoma to spread back up to a contralateral epithelial site. Hematogenous spread is less common with carcinomas and typically results in metastases to distant sites.

(Choice D) Certain anatomic sites (eg, eyes, testes) display inherent immune privilege, in which foreign grafts or cancers that would otherwise induce immunologic rejection are tolerated. Cancers may establish local sites of immune privilege to evade destruction, but this does not cause new tumor formation.

(Choice E) Cancer treatment (eg, chemotherapy, radiation therapy) can result in impaired wound healing, which can result in acutely ulcerative oral lesions due to mucositis. However, these lesions would not be malignant.

Educational objective:

surveillance of the at-risk area (eg, colonoscopy, comprehensive skin examination, panendoscopy of the upper aerodigestive tract).

(Choice A) Chemotherapy can induce secondary malignancies, most commonly leukemia and lymphoma, in cancer survivors. In contrast to the tumors in this patient, secondary malignancies are seen years or even decades later.

(Choices C and F) Most carcinomas, including HNSCC, spread via the lymphatic system, leading to metastases in the regional (eg, ipsilateral anterior neck) lymph nodes. However, it is unlikely for the carcinoma to spread back up to a contralateral epithelial site. Hematogenous spread is less common with carcinomas and typically results in metastases to distant sites.

(Choice D) Certain anatomic sites (eg, eyes, testes) display inherent immune privilege, in which foreign grafts or cancers that would otherwise induce immunologic rejection are tolerated. Cancers may establish local sites of immune privilege to evade destruction, but this does not cause new tumor formation.

(Choice E) Cancer treatment (eg, chemotherapy, radiation therapy) can result in impaired wound healing, which can result in acutely ulcerative oral lesions due to mucositis. However, these lesions would not be malignant.

Educational objective:
Field cancerization can occur when a large area of cells is exposed to carcinogens that induce mutations, leading to a higher risk of forming cancers.

References

- An evolutionary perspective on field cancerization.
- Wound healing and cancer stem cells: inflammation as a driver of treatment resistance in breast cancer.
- Epithelial stem cells, wound healing and cancer.

Pathology	Hematology & Oncology	Head and neck cancers
Subject	System	Topic

Copyright © UWorld. All rights reserved.

1
2
3
4
5
6
7
8
9
10
11
12
13
14
15
16
17
18
19
20
21
22
23
24
25
26
27
28
29
30

A 67-year-old man comes to the office due to severe fatigue for the past several months. The patient cannot eat as much as he used to and has lost nearly 10 kg (22 lb) in the past 6 months. Physical examination shows mucosal pallor, hepatomegaly, and massive splenomegaly. Further evaluation reveals a gain-of-function mutation of a non-receptor tyrosine kinase protein in hematopoietic cells, leading to persistent activation of signal transducers and activators of transcription (STAT) proteins. This patient is most likely suffering from which of the following disorders?

A. Acute promyelocytic leukemia

B. Chronic lymphocytic leukemia

C. High-grade non-Hodgkin lymphoma

D. Mantle cell lymphoma

E. Primary myelofibrosis

Submit

A 67-year-old man comes to the office due to severe fatigue for the past several months. The patient cannot eat as much as he used to and has lost nearly 10 kg (22 lb) in the past 6 months. Physical examination shows mucosal pallor, hepatomegaly, and massive splenomegaly. Further evaluation reveals a gain-of-function mutation of a non-receptor tyrosine kinase protein in hematopoietic cells, leading to persistent activation of signal transducers and activators of transcription (STAT) proteins. This patient is most likely suffering from which of the following disorders?

- A. Acute promyelocytic leukemia (16%)
- B. Chronic lymphocytic leukemia (27%)
- C. High-grade non-Hodgkin lymphoma (8%)
- D. Mantle cell lymphoma (8%)
- ✓ E. Primary myelofibrosis (39%)

Omitted
Correct answer
E

39%
Answered correctly

01 sec
Time Spent

02/05/2020
Last Updated

Explanation

Chronic myeloproliferative disorders		
Disorder	Diagnostic features	Mutation

1
2
3
4
5
6
7
8
9
10
11
12
13
14
15
16
17
18
19
20
21
22
23
24
25
26
27
28
29
30

Chronic myeloproliferative disorders		
Disorder	**Diagnostic features**	**Mutation**
Chronic myelogenous leukemia	Constitutional symptoms (eg, fatigue, weight loss, excessive sweating), splenomegaly & **leukocytosis with marked left shift** (eg, myelocytes, metamyelocytes, band forms)	Philadelphia chromosome t(9:22) BCR-ABL fusion protein
Essential thrombocytosis	Hemorrhagic & thrombotic symptoms (eg, easy bruising, microangiopathic occlusion), **thrombocytosis** & megakaryocytic hyperplasia	JAK2
Polycythemia vera	Pruritus, erythromelalgia, splenomegaly, thrombotic complications, **erythrocytosis** & thrombocytosis	
Primary myelofibrosis	Severe fatigue, splenomegaly (often causing early satiety/abdominal discomfort), hepatomegaly, anemia & **bone marrow fibrosis**	

©UWorld

The chronic myeloproliferative disorders are bone marrow diseases characterized by overproduction of myeloid cells. **Primary myelofibrosis** is caused by atypical megakaryocytic hyperplasia, which stimulates fibroblast proliferation, resulting in progressive replacement of the marrow space by extensive collagen deposition. In the early stages, there is marrow hypercellularity with minimal fibrosis, but as the disease progresses,

The chronic myeloproliferative disorders are bone marrow diseases characterized by overproduction of myeloid cells. **Primary myelofibrosis** is caused by atypical megakaryocytic hyperplasia, which stimulates fibroblast proliferation, resulting in progressive replacement of the marrow space by extensive collagen deposition. In the early stages, there is marrow hypercellularity with minimal fibrosis, but as the disease progresses, **pancytopenia** can result. **Hepatomegaly** and massive **splenomegaly** develop because the loss of bone marrow hematopoiesis is compensated for by extramedullary hematopoiesis. The peripheral smear characteristically shows **teardrop**-shaped red blood cells (dacrocytes) and nucleated red blood cells.

With the exception of chronic myelogenous leukemia, the chronic myeloproliferative disorders (especially polycythemia vera) frequently harbor a mutation in the nonreceptor cytoplasmic tyrosine kinase, Janus kinase 2 (JAK2). This mutation results in **constitutive tyrosine phosphorylation activity**, and consequently, in the cytokine-independent activation of the signal transducers and activators of transcription **(STAT)** pathway. Once they are activated, STAT proteins translocate to the nucleus and promote transcription. A JAK2 inhibitor (ruxolitinib) has been approved for treatment of primary myelofibrosis.

(Choice A) In acute promyelocytic leukemia, t(15;17) leads to the formation of a fusion gene between the promyelocytic leukemia (*PML*) and the retinoic acid receptor alpha (*RARA*) genes. The abnormal PML/RARα fusion protein blocks differentiation of myeloid precursors.

(Choice B) Chronic lymphocytic leukemia is a lymphoproliferative disorder involving B lymphocytes. The most significant laboratory finding is marked lymphocytosis, with "smudge cells" seen on peripheral blood smear. The majority of cases exhibit increased expression of the proto-oncogene *BCL2*; a similar finding occurs in follicular lymphomas.

(Choices C and D) Several high-grade non-Hodgkin lymphomas (NHLs) are associated with cytogenetic abnormalities. The t(8;14) translocation involves the c-*Myc* oncogene and is common in Burkitt lymphoma, which is associated with Epstein-Barr virus infection and classically has a "starry sky" histological appearance. Mantle cell lymphoma is a low grade NHL characterized by t(11;14), leading to cyclin D1 overexpression.

Educational objective:
The chronic myeloproliferative disorders (polycythemia vera, essential thrombocytosis, and primary myelofibrosis) often have a mutation in Janus kinase 2 (JAK2), a cytoplasmic tyrosine kinase. This results in constitutive tyrosine kinase activity, and consequently, in the cytokine-independent activation of signal transducers and activators of transcription (STAT) proteins (JAK-STAT signaling pathway).

References

- Myeloproliferative disorders.

The chronic myeloproliferative disorders are bone marrow diseases characterized by overproduction of myeloid cells. **Primary myelofibrosis** is

Exhibit Display

Receptor vs non-receptor tyrosine kinases

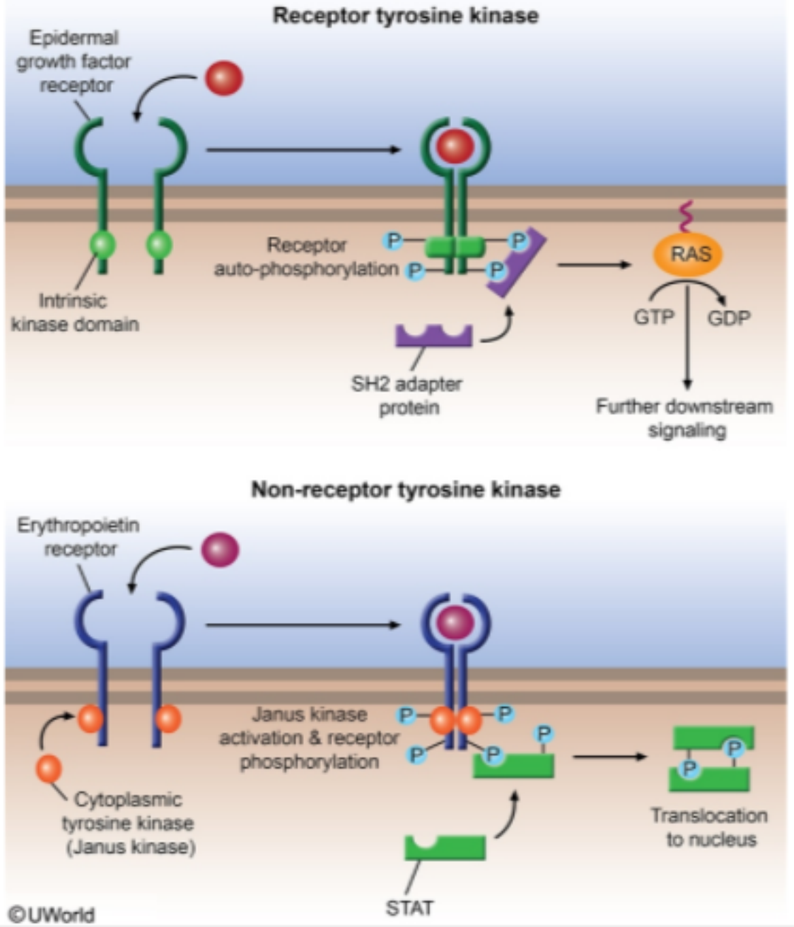

Zoom In Zoom Out Reset Add To New Card | Existing Card

- Myeloproliferative disorders.

With the exception of chronic myelogenous leukemia, the chronic myeloproliferative disorders (especially polycythemia vera) frequently harbor a mutation in the nonreceptor cytoplasmic tyrosine kinase, Janus kinase 2 (JAK2). This mutation results in **constitutive tyrosine phosphorylation activity**, and consequently, in the cytokine-independent activation of the signal transducers and activators of transcription **(STAT)** pathway. Once they are activated, STAT proteins translocate to the nucleus and promote transcription. A JAK2 inhibitor (ruxolitinib) has been approved for treatment of primary myelofibrosis.

(Choice A) In acute promyelocytic leukemia, t(15;17) leads to the formation of a fusion gene between the promyelocytic leukemia (*PML*) and the retinoic acid receptor alpha (*RARA*) genes. The abnormal PML/RARα fusion protein blocks differentiation of myeloid precursors.

(Choice B) Chronic lymphocytic leukemia is a lymphoproliferative disorder involving B lymphocytes. The most significant laboratory finding is marked lymphocytosis, with "smudge cells" seen on peripheral blood smear. The majority of cases exhibit increased expression of the proto-oncogene *BCL2*; a similar finding occurs in follicular lymphomas.

(Choices C and D) Several high-grade non-Hodgkin lymphomas (NHLs) are associated with cytogenetic abnormalities. The t(8;14) translocation involves the c-*Myc* oncogene and is common in Burkitt lymphoma, which is associated with Epstein-Barr virus infection and classically has a "starry sky" histological appearance. Mantle cell lymphoma is a low grade NHL characterized by t(11;14), leading to cyclin D1 overexpression.

Educational objective:
The chronic myeloproliferative disorders (polycythemia vera, essential thrombocytosis, and primary myelofibrosis) often have a mutation in Janus kinase 2 (JAK2), a cytoplasmic tyrosine kinase. This results in constitutive tyrosine kinase activity, and consequently, in the cytokine-independent activation of signal transducers and activators of transcription (STAT) proteins (JAK-STAT signaling pathway).

References

- Myeloproliferative disorders.

Pathology	Hematology & Oncology	Myelofibrosis
Subject	System	Topic

Copyright © UWorld. All rights reserved.

1
2
3
4
5
6
7
8
9
10
11
12
13
14
15
16
17
18
19
20
21
22
23
24
25
26
27
28
29
30

A 24-year-old man comes to the clinic due to progressive generalized weakness and fatigue over the last 2 weeks. He also has significant bruising on his trunk that developed spontaneously without any associated trauma. The patient has no known medical problems and takes no medications. His temperature is 37.1 C (98.8 F). Physical examination is notable for conjunctival pallor and truncal ecchymoses. Laboratory studies reveal a hemoglobin of 6.8 g/dL. Creatinine is normal. Bone marrow aspiration is performed. The aspirate is grossly pale and histologically appears dilute due to high lipid content.

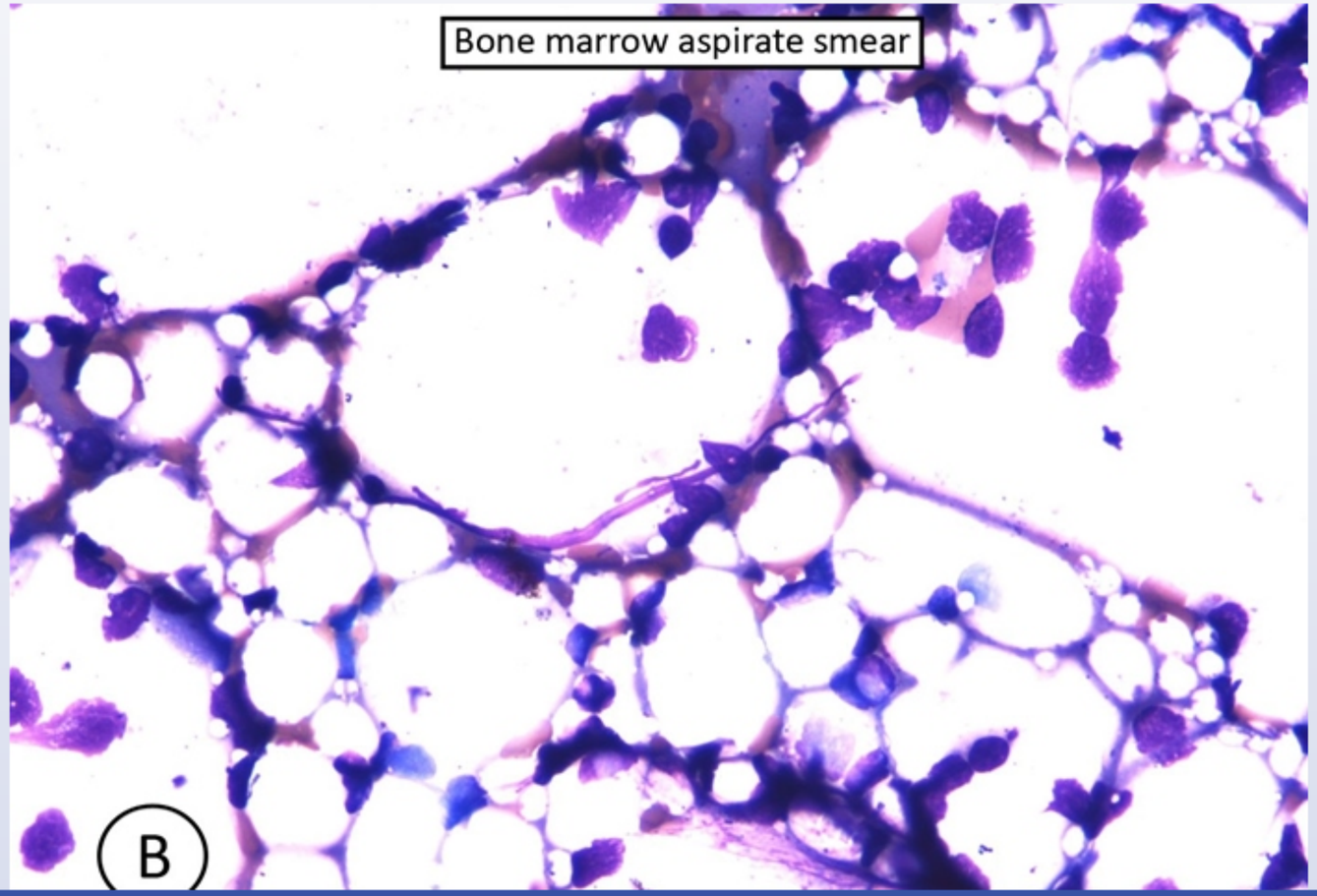

1
2
3
4
5
6
7
8
9
10
11
12
13
14
15
16
17
18
19
20
21
22
23
24
25
26
27
28
29
30

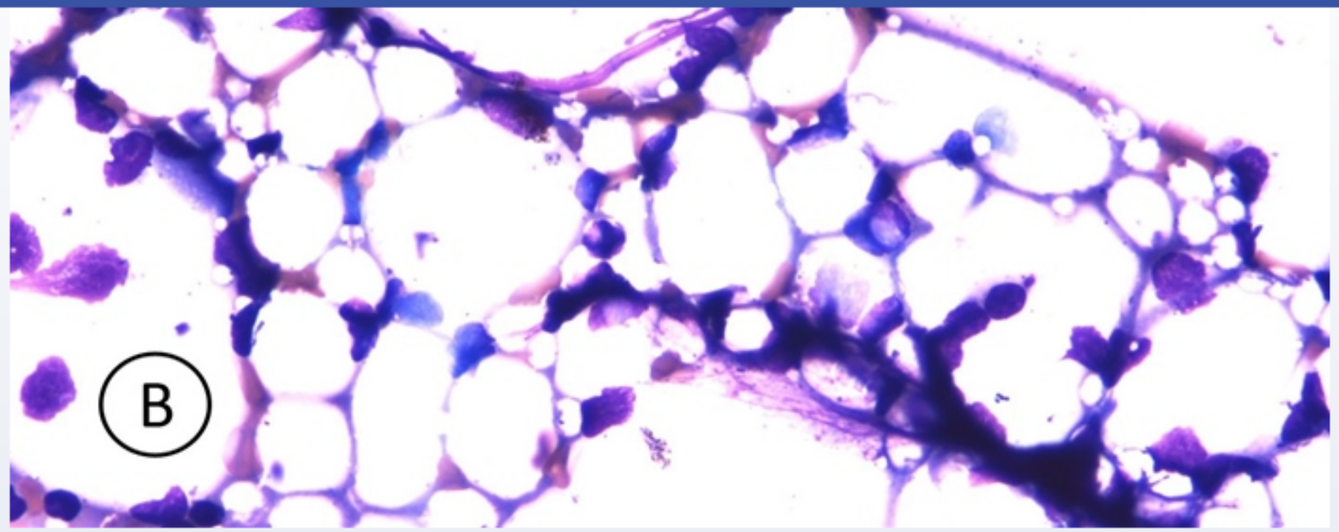

Which of the following blood parameters is most likely to be elevated in this patient?

- A. Eosinophil count
- B. Erythropoietin
- C. Haptoglobin
- D. Iron
- E. Lactate dehydrogenase
- F. Reticulocyte index

Submit

1
2
3
4
5
6
7
8
9
10
11
12
13
14
15
16
17
18
19
20
21
22
23
24
25
26
27
28
29
30

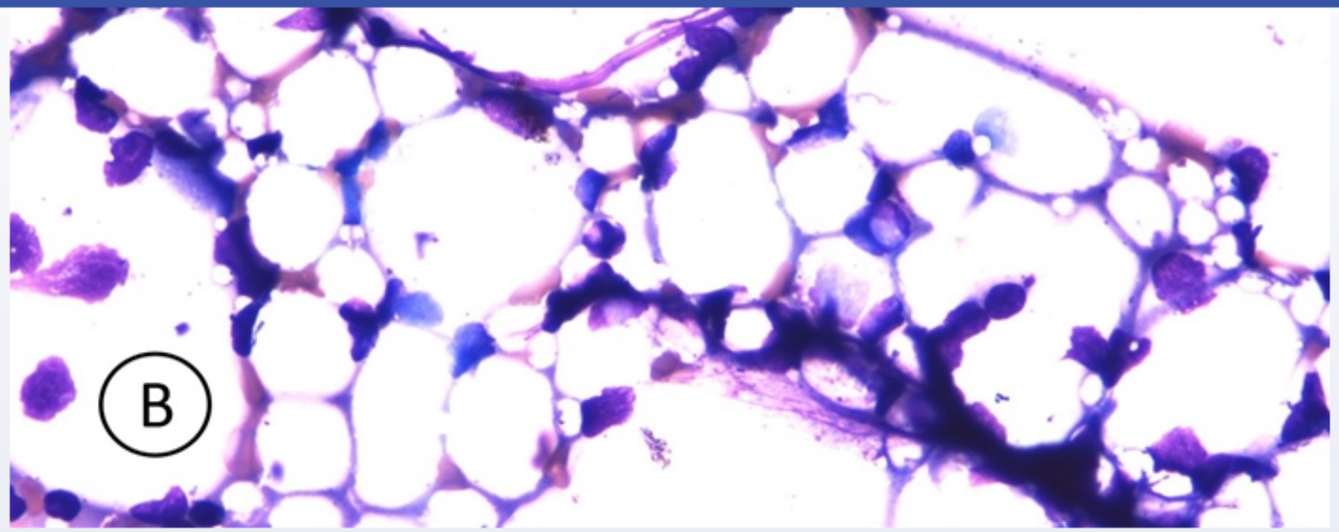

Which of the following blood parameters is most likely to be elevated in this patient?

A. Eosinophil count (1%)
B. Erythropoietin (75%)
C. Haptoglobin (5%)
D. Iron (1%)
E. Lactate dehydrogenase (8%)
F. Reticulocyte index (7%)

Omitted
Correct answer

75%
Answered correctly

06 secs
Time Spent

01/19/2020
Last Updated

This patient has:

- Fatigue, weakness, conjunctival pallor, and decreased hemoglobin, suggestive of anemia
- Bruising not associated with trauma, suggestive of thrombocytopenia
- High lipid content of the bone marrow aspirate, suggestive of hematopoietic cell aplasia or hypoplasia

He likely suffers from **aplastic anemia**, which is due to stem cell failure and actually affects all 3 cells lines, causing **pancytopenia** (despite the name).

As with most **anemias**, increased production of **erythropoietin** by the kidney (in response to anemia-induced hypoxia) would be expected, given this patient's normal renal function.

(Choice A) Aplastic anemia is associated with pancytopenia, which includes a reduction in circulating eosinophils.

(Choice C) Haptoglobin levels are typically normal in aplastic anemia. Haptoglobin is reduced in cases of intravascular hemolysis; once free hemoglobin binds haptoglobin, the resulting haptoglobin-hemoglobin complex is removed from circulation.

(Choice D) Serum iron is usually normal in aplastic anemia.

(Choice E) Elevated lactate dehydrogenase (LDH), particularly LDH-1, is expected in patients with hemolytic anemia, not aplastic anemia.

(Choice F) An increased reticulocyte index would be expected in a hemolytic or hemorrhagic anemia, assuming normal bone marrow function. Reticulocyte count is low in aplastic anemia because there are few progenitor cells in the marrow.

Educational objective:
The triad of low hemoglobin, thrombocytopenia, and absent hematopoietic cells in the bone marrow is consistent with aplastic anemia. A compensatory increase in circulating erythropoietin levels would be expected in individuals with aplastic anemia and normal renal function.

Pathology	Hematology & Oncology	Aplastic anemia
Subject	System	Topic

Copyright © UWorld. All rights reserved.

1
2
3
4
5
6
7
8
9
10
11
12
13
14
15
16
17
18
19
20
21
22
23
24
25
26
27
28
29
30

A 59-year-old woman comes to the office due to progressive fatigue and occasional heart palpitations over the last 6 months. The patient has been under a lot of stress recently due to problems at work. She has no dietary restrictions, eats out at restaurants frequently, and drinks 2 or 3 cans of beer on the weekends. The patient is postmenopausal and has not noticed any uterine bleeding, dark stools, or bleeding with bowel movements. Her BMI is 25 kg/m^2. Hemoglobin is 8.5 g/dL. Peripheral blood smear reveals pale, microcytic erythrocytes. Which of the following is the most likely underlying cause of this patient's abnormal laboratory findings?

A. Drug abuse

B. Hematologic malignancy

C. Hemolysis

D. Liver disease

E. Occult blood loss

F. Poor nutrition

Submit

A 59-year-old woman comes to the office due to progressive fatigue and occasional heart palpitations over the last 6 months. The patient has been under a lot of stress recently due to problems at work. She has no dietary restrictions, eats out at restaurants frequently, and drinks 2 or 3 cans of beer on the weekends. The patient is postmenopausal and has not noticed any uterine bleeding, dark stools, or bleeding with bowel movements. Her BMI is 25 kg/m^2. Hemoglobin is 8.5 g/dL. Peripheral blood smear reveals pale, microcytic erythrocytes. Which of the following is the most likely underlying cause of this patient's abnormal laboratory findings?

- A. Drug abuse (2%)
- B. Hematologic malignancy (4%)
- C. Hemolysis (4%)
- D. Liver disease (3%)
- ✓ E. Occult blood loss (45%)
- F. Poor nutrition (39%)

Omitted
Correct answer
E

45%
Answered correctly

01 sec
Time Spent

07/01/2020
Last Updated

Explanation

Iron deficiency anemia

1
2
3
4
5
6
7
8
9
10
11
12
13
14
15
16
17
18
19
20
21
22
23
24
25
26
27
28
29
30

Iron deficiency anemia

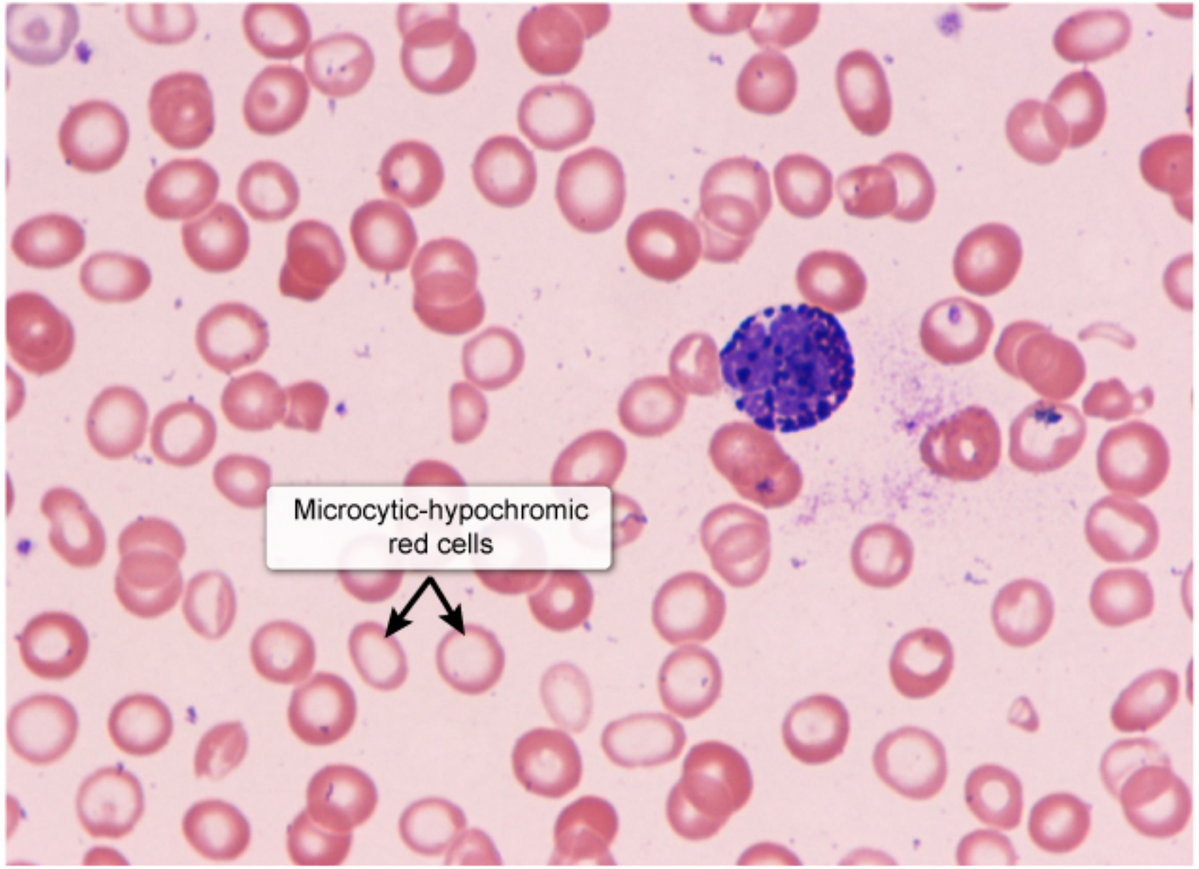

©UWorld

Fatigue and heart palpitations are common manifestations of all forms of anemia. This patient's peripheral smear findings indicate **hypochromic, microcytic anemia**, which **most often** arises in the setting of **iron deficiency**. The primary, and most dangerous if overlooked, mechanism of iron deficiency is **blood loss**, and it should be excluded first. Women of childbearing age are commonly iron deficient due to menstruation. Men (especially over the age of 60) or postmenopausal women have no physiologic reason to be iron deficient and therefore should be evaluated for

Fatigue and heart palpitations are common manifestations of all forms of anemia. This patient's peripheral smear findings indicate **hypochromic, microcytic anemia**, which **most often** arises in the setting of **iron deficiency**. The primary, and most dangerous if overlooked, mechanism of iron deficiency is **blood loss**, and it should be excluded first. Women of childbearing age are commonly iron deficient due to menstruation. Men (especially over the age of 60) or postmenopausal women have no physiologic reason to be iron deficient and therefore should be evaluated for blood loss in the **gastrointestinal (GI) tract** (eg, due to malignancy). GI blood loss is often **occult**, so the lack of dark or bright red stools in this patient should not rule out GI hemorrhage. Iron studies (including ferritin) should be obtained, and the patient will likely require endoscopic evaluation.

(Choice A) Ingestion of the more commonly abused drugs is not associated with microcytic anemia.

(Choice B) Hematologic malignancies (eg, leukemia, lymphoma, multiple myeloma) tend to be associated with normochromic, normocytic anemia. The decrease in erythropoiesis seen in these patients results from hypersplenism or tumor replacement of bone marrow mass.

(Choice C) Hemolysis often presents with a normochromic, normocytic anemia. Spherocytes or schistocytes are often seen on peripheral blood smear.

(Choice D) The anemia of chronic liver disease is usually normocytic or slightly macrocytic with target cells on the peripheral blood smear. Microcytic anemia occurs in <25% of cases, and most patients have only mild anemia with a hemoglobin level of 10-11 g/dL.

(Choice F) This patient has a normal BMI and no factors predisposing her to malnutrition (eg, dietary restrictions, chronic alcoholism). A normal Western diet provides 6 mg of iron for every 1,000 calories, and the recommended intake for individuals age >50 is 8 mg per day. As a result, men and postmenopausal women (ie, not menstruating, pregnant, or lactating) usually have no dietary iron shortage.

Educational objective:
Hypochromic, microcytic anemia is most commonly due to iron deficiency. Blood loss, especially occult loss from the gastrointestinal tract, must be ruled out in a patient with iron deficiency anemia.

Pathology	Hematology & Oncology	Iron deficiency anemia
Subject	System	Topic

microcytic anemia, which **most often** arises in the setting of **iron deficiency**. The primary, and most dangerous if overlooked, mechanism of iron deficiency is **blood loss**, and it should be excluded first. Women of childbearing age are commonly iron deficient due to menstruation. Men (especially over the age of 60) or postmenopausal women have no physiologic reason to be iron deficient and therefore should be evaluated for blood loss in the **gastrointestinal (GI) tract** (eg, due to malignancy). GI blood loss is often **occult**, so the lack of dark or bright red stools in this patient should not rule out GI hemorrhage. Iron studies (including ferritin) should be obtained, and the patient will likely require endoscopic evaluation.

(Choice A) Ingestion of the more commonly abused drugs is not associated with microcytic anemia.

(Choice B) Hematologic malignancies (eg, leukemia, lymphoma, multiple myeloma) tend to be associated with normochromic, normocytic anemia. The decrease in erythropoiesis seen in these patients results from hypersplenism or tumor replacement of bone marrow mass.

(Choice C) Hemolysis often presents with a normochromic, normocytic anemia. Spherocytes or schistocytes are often seen on peripheral blood smear.

(Choice D) The anemia of chronic liver disease is usually normocytic or slightly macrocytic with target cells on the peripheral blood smear. Microcytic anemia occurs in <25% of cases, and most patients have only mild anemia with a hemoglobin level of 10-11 g/dL.

(Choice F) This patient has a normal BMI and no factors predisposing her to malnutrition (eg, dietary restrictions, chronic alcoholism). A normal Western diet provides 6 mg of iron for every 1,000 calories, and the recommended intake for individuals age >50 is 8 mg per day. As a result, men and postmenopausal women (ie, not menstruating, pregnant, or lactating) usually have no dietary iron shortage.

Educational objective:
Hypochromic, microcytic anemia is most commonly due to iron deficiency. Blood loss, especially occult loss from the gastrointestinal tract, must be ruled out in a patient with iron deficiency anemia.

Pathology	Hematology & Oncology	Iron deficiency anemia
Subject	System	Topic

Copyright © UWorld. All rights reserved.